

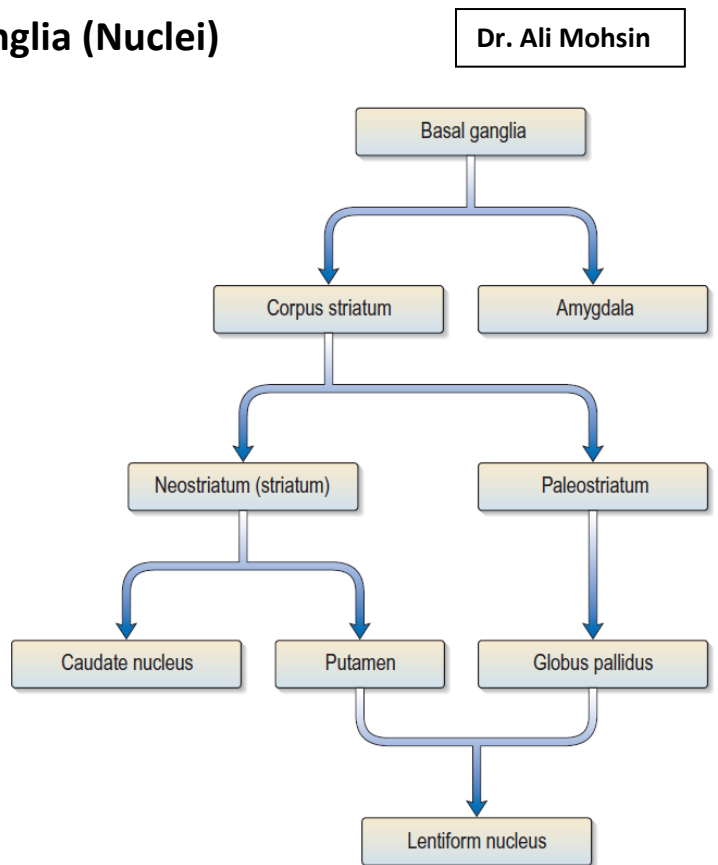
## Neuroanatomy 8: Basal Ganglia (Nuclei)

Dr. Ali Mohsin

The term basal ganglia refers to a number of subcortical nuclear masses (gray matter islets) embedded inside the cerebral white matter in the inferior part of the cerebral hemisphere, anterior & lateral to the thalamus. These structures form a functional complex involved in the control of movement and motivational aspects of behavior.

Components:

- Anatomically, the basal ganglia include: **caudate nucleus, lentiform nucleus** (putamen + globus pallidus), & the **amygdaloid complex**.
- Functionally, other structures are closely related to the basal ganglia, like **substantia nigra** (of the midbrain), **subthalamic nucleus** (of the diencephalon), & some thalamic nuclei.
- The amygdaloid complex, while being a basal ganglion, it is more related functionally to the limbic system than to the basal ganglia.
- See the adjacent figure to know the divisions of basal ganglia.



### Corpus Striatum

The corpus striatum is composed of the lentiform and caudate nuclei. Hence, the corpus striatum is made up of the putamen, globus pallidus and caudate nucleus. The corpus striatum has two parts or units, the striatum and the pallidum. The striatum is composed of caudate nucleus and putamen, while the pallidum is made up of the globus pallidus.

**Pallidum:** This is composed of the globus pallidus and it forms one unit of the corpus striatum. It sends fibers (efferents) to the substantia nigra pars reticulata and to the thalamus, but receives fibers (afferents) from the striatum.

**Striatum:** This is the second unit of the corpus striatum which is composed of the caudate nucleus and putamen, separated from each other by the fibers of the internal capsule. It is the main input unit of the basal ganglia, receiving most of the afferents to the basal nuclei.

There are two types of cell population within the striatum, the spiny projection neurons (also called medium spiny neurons) which constitutes about 90-95% of its neuronal population. The spiny projection neurons are the principal neurons of the striatum that are largely responsible for its functions, and by extension, the functions of the basal ganglia. The spiny projection neurons are GABAergic, which possess receptors for GABA neurotransmitters. Thus, they are classified as inhibitory neurons. The second cell group within the striatum consists of interneurons. The interneurons make up about 5-10% of the striatal neurons. They are Cholinergic – releasing and using acetylcholine and are classified as excitatory.

### Anatomy of the caudate nucleus:

The caudate nucleus is a large comma-shaped mass of gray matter situated in the cerebral hemisphere, in a paramedian position, with a close relation to the lateral ventricle. The caudate nucleus is divided into head, body, & tail. The **head** of caudate nucleus is the largest part. It lies in the white matter of the frontal lobe, forming most of the lateral wall of the anterior horn of the lateral ventricle. The anterior limb of internal capsule lies lateral to the head of caudate nucleus, separating it from the lentiform nucleus. The **body** of caudate nucleus extends posteriorly from the head, & tapers in size as it does so. It forms the inferolateral wall of the body of lateral ventricle, lying superolateral to the thalamus. The **tail** of caudate nucleus curves posteriorly, inferiorly & anterolaterally (in line with the lateral ventricle) to form part of the roof of its inferior horn, & contact the amygdala by its tip.

## **Anatomy of the lentiform nucleus:**

The lentiform nucleus is a large wedge-shaped mass of gray matter situated in the cerebral hemisphere lateral to the internal capsule. The lentiform nucleus is divided (by the external medullary lamina) into a larger lateral part (the putamen) & a smaller medial part (the globus pallidus). The globus pallidus is subdivided (by the internal medullary lamina) into an external & an internal pallidal segments. The medial conical surface of the lentiform nucleus is separated by the anterior limb of internal capsule from the head of caudate nucleus, & by the posterior limb from the thalamus. The lateral convex surface of the lentiform nucleus is separated from the claustrum by the external capsule.

## **Amygdaloid Complex**

The amygdala lies in the temporal lobe white matter, close to the temporal pole of the cerebral hemisphere. It lies deep to the uncus (of the cerebral cortex) and is related to the anterior end of the inferior horn of the lateral ventricle. The tail of caudate nucleus usually contacts the amygdaloid complex.

## **Clastrum**

The claustrum is a thin lamina of grey matter that lies lateral to the lentiform nucleus. It is separated from the latter by fibers of the external capsule. Laterally, it is separated by a thin layer of white matter (the extreme capsule) from the cortex of the insula. It has reciprocal connections between the sensory cortices.

## **Subthalamic Nucleus**

The subthalamic nucleus (STN) is traditionally described as part of the subthalamic region but functionally grouped with the basal nuclei.

The nucleus is shaped like a biconcave lens. It lies between the thalamus above, and the substantia nigra (of midbrain) below. The upper end of the red nucleus is close to it. The fibers connecting the subthalamic nucleus to the globus pallidus (part of the corpus striatum) form a bundle called the subthalamic fasciculus which passes through the internal capsule. The subthalamic nucleus produces the excitatory neurotransmitter glutamate and sends excitatory input to the globus pallidus.

## **Substantia Nigra**

This is a midbrain structure that is closely linked, functionally, to the basal ganglia. It is considered the mesencephalic grey matter portion of the basal ganglia. It is divided into a pars reticulata and a pars compacta (based on the arrangements of neurons within each part). Neurons of substantia nigra compacta (SNc) are very close to one another, while those of substantia nigra reticulata (SNr) are further away from one another.

The substantia nigra pars compacta produces the inhibitory neurotransmitter dopamine, which is very significant in maintaining the striatal pathway (the main input pathway of the basal ganglia). There is a fine connection between the substantia nigra pars reticulata and the subthalamic nucleus and the globus pallidus. Through those connections dopaminergic fibers (inhibitory fibers) are sent to the thalamus.

## **Thalamic nuclei related to the basal ganglia**

The ventral anterior (VA), ventral lateral (VL), & the some intralaminar nuclei are connected to the basal ganglia, & are integrated with the motor function of them.

## **Connections**

The caudate nucleus and the putamen form the main sites for receiving input to the basal nuclei. The globus pallidus forms the major site from which the output leaves the basal nuclei. They receive no direct input from or output to the spinal cord.

## **Afferent fibers of the corpus striatum:**

1. **Corticostriate Fibers:** All parts of the cerebral cortex send axons to the caudate nucleus and the putamen. Each part of the cerebral cortex projects to a specific part of the caudate-putamen complex. Most of the projections are from the cortex of the same side. The largest input is from the sensory-motor cortex. Glutamate is the neurotransmitter of the corticostriate fibers.
2. **Thalamostriate Fibers:** The intralaminar nuclei of the thalamus send large numbers of axons to the caudate nucleus and the putamen.
3. **Nigrostriate Fibers:** Neurons in the substantia nigra compacta (SNc) send axons to the caudate nucleus and the putamen and liberate dopamine at their terminals as the neurotransmitter. It is believed that these fibers are inhibitory in function.
4. **Brainstem Striatal Fibers:** Ascending fibers from the brainstem end in the caudate nucleus and putamen and liberate serotonin at their terminals as the neurotransmitter. It is thought that these fibers are inhibitory in function.

### **Efferent fibers of the corpus striatum:**

**Striatopallidal Fibers:** Striatopallidal fibers pass from the caudate nucleus and putamen to the globus pallidus. They have gamma-aminobutyric acid (GABA) as their neurotransmitter.

**Striatonigral Fibers:** Striatonigral fibers pass from the caudate nucleus and putamen to the substantia nigra reticulata (SNr). Some of the fibers use GABA or acetylcholine as the neurotransmitter, while others use substance P.

### **Afferent fibers of the globus pallidus:**

**Striatopallidal Fibers:** Striatopallidal fibers pass from the caudate nucleus and putamen to the globus pallidus. As noted previously, these fibers have GABA as their neurotransmitter.

### **Efferent fibers of the globus pallidus (pallidofugal fibers):** these include:

1. the **ansa lenticularis**, which pass to the thalamic nuclei;
2. the **fasciculus lenticularis**, which pass to the subthalamus;
3. the **pallidotegmental fibers**, which terminate in the caudal tegmentum of the midbrain;
4. the **pallidosubthalamic fibers**, which pass to the subthalamic nuclei.

## **Functions of the basal ganglia**

Basically, the corpus striatum receives afferent information from most of the cerebral cortex, the thalamus, the subthalamus, and the brainstem, including the substantia nigra. The information is integrated within the corpus striatum, and the outflow passes back to the areas listed above. This circular pathway is believed to function as follows.

- The activity of the basal nuclei is initiated by information received from the premotor and supplemental areas of the motor cortex, the primary sensory cortex, the thalamus, and the brainstem.
- The outflow from the basal nuclei is channeled through the globus pallidus, which then influences the activities of the motor areas of the cerebral cortex or other motor centers in the brainstem.
- Thus, the basal nuclei control muscular movements by influencing the cerebral cortex and have no direct control through descending pathways to the brainstem and spinal cord.
- In this way, the basal nuclei assist in the regulation of voluntary movement and the learning of motor skills.

Destruction of the primary motor cerebral cortex prevents the individual from performing fine discrete movements of the hands and feet on the opposite side of the body. However, the person is still capable of performing gross crude movements of the opposite limbs. If destruction of the corpus striatum then takes place, paralysis of the remaining movements of the opposite side of the body occurs.

The basal nuclei not only influence the execution of a particular movement of, say, the limbs but also help prepare for the movements. This may be achieved by controlling the axial and girdle movements of the body and the positioning of the proximal parts of the limbs. The activity in certain neurons of the globus pallidus increases before active movements take place in the distal limb muscles. This important preparatory function enables the trunk and limbs to be placed in appropriate positions before the primary motor part of the cerebral cortex activates discrete movements in the hands and feet.

## **Clinical Considerations**

### **Huntington Disease**

Huntington disease is an autosomal dominant inherited disease, with the onset occurring most often in adult life. The disease has been traced to a single gene defect on chromosome 4. This gene encodes a protein, huntingtin, the function of which is not known. The codon (CAG) that encodes glutamine is repeated many more times than normal. The disease affects men and women with equal frequency and unfortunately often reveals itself only after they have had children. Patients have the following characteristic signs and symptoms:

- *Choreiform movements first appear as involuntary movements of the extremities and twitching of the face. Later, more muscle groups are involved, so the patient becomes immobile and unable to speak or swallow.*
- *Progressive dementia occurs with loss of memory and intellectual capacity.*

*In this disease, there is a degeneration of the GABA-secreting, substance P-secreting, and acetylcholine-secreting neurons of the striatonigral-inhibiting pathway. This results in the dopa-secreting neurons of the substantia nigra becoming overactive; thus, the nigrostriatal pathway inhibits the caudate nucleus and the putamen. This inhibition produces the abnormal movements seen in this disease. Computed tomography scans show enlarged lateral ventricles due to degeneration of the caudate nuclei.*

### **Parkinson Disease**

*Parkinson disease is a progressive disease of unknown cause that begins between the ages of 45 and 55 years. It is associated with neuronal degeneration in the substantia nigra and, to a lesser extent, in the globus pallidus, putamen, and caudate nucleus.*

*The degeneration of the neurons of the substantia nigra that send their axons to the corpus striatum results in a reduction in the release of the neurotransmitter dopamine within the corpus striatum. This leads to hypersensitivity of the dopamine receptors in the postsynaptic neurons in the striatum.*

*Patients have the following characteristic signs and symptoms:*

1. *Tremor: This is the result of the alternating contraction of agonists and antagonists. The tremor is slow and occurs most obviously when the limbs are at rest. It disappears during sleep. It should be distinguished from the intention tremor seen in cerebellar disease, which only occurs when purposeful active movement is attempted.*
2. *Rigidity: If the tremor is absent, the rigidity is felt as resistance to passive movement and is sometimes referred to as plastic rigidity. If the tremor is present, the muscle resistance is overcome as a series of jerks, called cogwheel rigidity.*
3. *Bradykinesia: There is a difficulty in initiating (akinesia) and performing new movements. The movements are slow, the face is expressionless, and the voice is slurred and unmodulated. Swinging of the arms in walking is lost.*
4. *Postural disturbances: The patient stands with a stoop, and his or her arms are flexed. The patient walks by taking short steps and often is unable to stop. In fact, he or she may break into a shuffling run to maintain balance.*
5. *There is no loss of muscle power and no loss of sensibility. Since the corticospinal tracts are normal, the superficial abdominal reflexes are normal, and there is no Babinski response. The deep tendon reflexes are normal.*

**END**