



Case Report

Bilateral sialocele associated with osseous metaplasia in a dog

Jamile M Garcia^{1*}, Luiz A S Silva¹, Nathalia S R Elias², Andressa G C Nitrini², Ticiania B Ervedosa¹,
Maria Lucia Z Dagli¹, Claudia Momo¹

¹ Serviço de Patologia Animal, Faculdade de Medicina Veterinária e Zootecnia, Universidade de São Paulo (USP), São Paulo, SP, Brazil

² Departamento de Cirurgia, Faculdade de Medicina Veterinária e Zootecnia, Universidade de São Paulo (USP), São Paulo, SP, Brazil

*Corresponding author: jamile.garcia@usp.br

Submitted: July 26th, 2023. Accepted: September 23rd, 2023.

Abstract

Sialocele is a lesion characterized by a cavity filled with saliva and delimited by granulation tissue and is the most commonly observed condition in dogs' salivary glands. A cervical swelling was observed in a male, mixed breed, 12-year-old dog. When punctured, the local was filled with saliva. The animal was referred for sialoadenectomy, and bilateral involvement was observed, with stony material delimiting the sialoceles on both sides. Samples were sent for histopathological examination, which showed cavity areas without epithelial delimitation, with osseous metaplasia and chronic inflammation. Such characteristics allowed the diagnosis of bilateral sialocele associated with osseous metaplasia. The presence of osseous metaplasia in sialoceles is extremely rare, with only four other cases described, which makes it difficult to reach conclusions related to epidemiology and pathogenesis.

Keywords: salivary gland, salivary mucocele, osseous metaplasia, canine, pathology.

Introduction

Salivary glands secrete saliva and are located in different regions of the head and neck (5, 15). They vary in number and location among the species, but all of them have the parotid, mandibular, and sublingual glands as their main glands. In the case of carnivores, the zygomatic glands are also added (5).

Sialocele is an accumulation of saliva in a cavity surrounded by granulation tissue (11, 14). Such accumulation is always located near a salivary gland or a ruptured duct (11). The article reports an unusual case of osseous metaplasia in a cervical sialocele. This study is the first known report of this condition being described bilaterally, to the best of the author's knowledge.

Case description

A 12-year-old mixed-breed male dog was admitted to the Veterinary Teaching Hospital of the School of Veterinary

Medicine and Animal Science from the University of São Paulo (HOVET – FMVZ – USP), São Paulo, Brazil, due to a painless and firm submandibular swelling measuring 5.5 x 5.0 x 4.5 cm. An aqueous fluid was aspirated through fine needle aspiration, and the case was clinically diagnosed as sialocele. Initial treatment consisted of carprofen 25mg twice a day and warm compresses. Two months later, after recurrence, the animal was referred for bilateral sialoadenectomy. During the procedure, close to the left mandibular salivary gland, a cavity area delimited by hard consistency tissue was observed, filled with approximately 48 ml of blood-tinged fluid. Inside the cavity, it was noted the presence of sialoliths. The right mandibular salivary gland had a small cavity area filled with a light amount of saliva and a plaque similar to that observed in the left sialocele. Samples were submitted to the Animal Pathology Service of the same institution for histopathological examination. The sialocele samples needed to undergo decalcification. The fragments were fixed in 10% formalin and routinely processed to obtain histological slides stained with hematoxylin and eosin. In the histopathological analysis, the walls of the sialoceles on both sides had mature

bone tissue, characterizing an area of osseous metaplasia, surrounded by fibrosis, hemorrhage, and chronic inflammation, composed by macrophage, lymphocytes, and plasma cells (Figs. 1-3). The cavities had no epithelial lining, leading to the diagnosis of bilateral sialocele associated with osseous metaplasia. Both mandibular salivary glands had a moderate interstitial lymphoplasmacytic infiltrate. The treatment proved to be curative, with the animal in good general condition and without clinical changes in the postoperative period.

Discussion

Salivary gland diseases in dogs are uncommon (5), comprising an incidence of only 0.5% of the diseases in this species (14). Sialocele is the most commonly observed condition involving the salivary glands (14). It is characterized by the accumulation of saliva in the subcutaneous tissue adjacent

to a salivary duct or a salivary gland, and it is delimited by granulation tissue, which can be a single or multilocular cavity (1, 5, 15). Sialoceles can be classified as sublingual, pharyngeal, zygomatic, cervical, or complex, depending on the anatomical location (11, 15). Cervical sialocele is the most observed in dogs, mainly originating from the sublingual gland (1, 2, 15).

The cause of this condition is unknown, but it can occur secondary to traumatic rupture of the duct or salivary gland, which leads to the extravasation of saliva into the adjacent tissue and the formation of reactive connective tissue around it, with a consequent inflammatory response (1, 5, 15). Other possibilities are foreign bodies and sialoliths (5, 11). The animal being discussed here was found to have sialoliths, which could be the reason for the sialocele. However, studies suggest that sialoliths may also appear after the development of sialocele (13). Several attempts to produce an experimental model of sialocele were unsuccessful. Because of this, an inherent predisposition to affected dogs has been suggested (7, 14).

This lesion can be seen in several breeds, but the most affected are Poodle, German shepherd, Dachshund, and Australian silky terrier (1, 14). A survey of 60 cases of canine sialoceles did not indicate a predisposition in mixed-breed dogs (1). There is no statistically significant difference in sex and age predisposition (1).

In the case being described, the animal's only clinical sign was painless swelling in the submandibular region. Cases of sialocele are usually asymptomatic and painless (1, 14, 16). Most cervical sialoceles are subcutaneous, located anywhere between the mandibular symphysis and the neck, especially in the ventrolateral region, and can reach up to 10 cm (15, 16).

The diagnosis of sialocele is performed through clinical history, physical examination, and histopathological examination (11, 14). When punctured, the lesion commonly drains yellowish mucoid content, which, on cytology, tends to

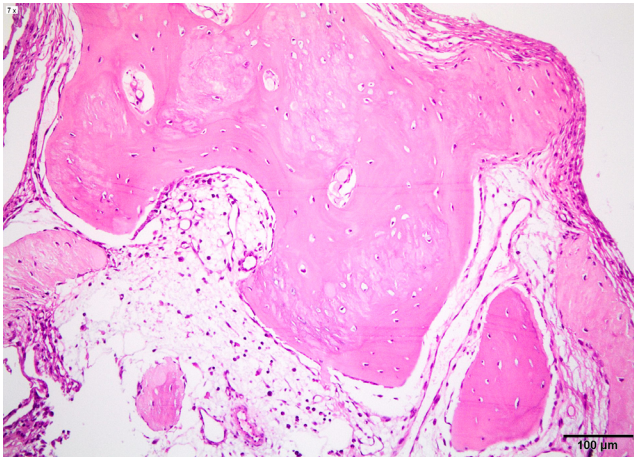


Figure 1. Sialocele, dog. Cavity wall area showing no epithelium, and surrounded by mature bone tissue, and inflammation. HE, bar = 100 μ m.

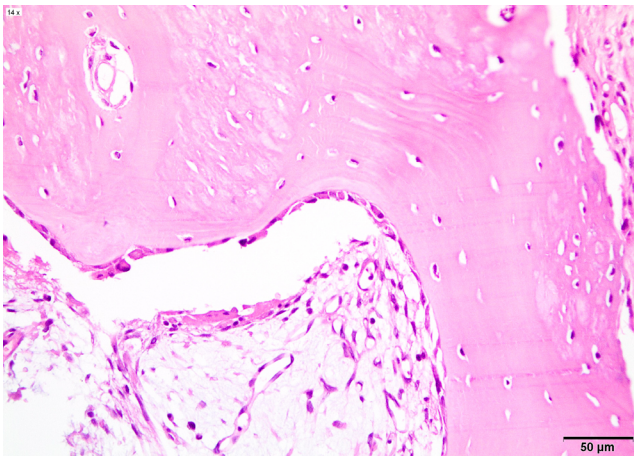


Figure 2. Sialocele, dog. Osteoid-producing cells on the areas of bone formation. HE, bar = 50 μ m.

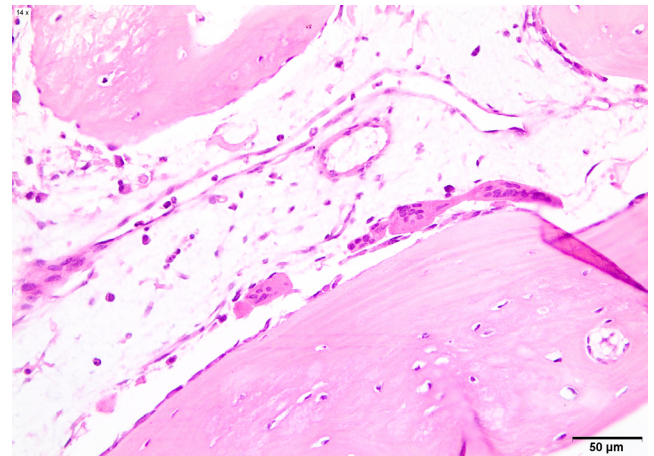


Figure 3. Sialocele, dog. Area of more developed ossification with osteoclasts. HE, bar = 50 μ m.

be acellular and compatible with saliva (10, 15, 16). The main differential diagnoses are salivary gland tumors, hematoma, lymphadenomegaly, congenital cysts, abscesses, foreign body, sialadenosis, sialoliths, and sialadenitis (5, 6, 7, 15). In the present case, the diagnosis was established through clinical history, with subsequent confirmation by histopathological examination. Histopathology is essential for the differentiation between sialocele and congenital cysts. This last one has a true secretory epithelial lining, which is not seen in sialocele (7, 11, 15). Another possibility to be excluded is a dilatation of the salivary duct, which generates a retention of saliva. In this case, the cystic area is lined by ductal epithelium (15).

Histologically, the cavity is lined by dense mature connective tissue, without epithelial lining, with abundant vessels, and may arise squamous (15, 16) or osseous metaplasia (3, 4, 9, 10). In the rare cases of osseous metaplasia described, as in the present case, well-differentiated trabecular bone formation was observed on the inner surface of the cavity wall (3, 4, 9, 10). The wall of the sialocele usually presents a chronic inflammatory process, predominantly composed of macrophages and multinucleated giant cells (16).

Metaplasia is a pathological process in which one cell type is differentiated into another completely different one (5). It is often a reversible process as long as the initial cause stops (5). Osseous metaplasia is an extremely rare process in sialoceles, with only four other reports published, none of them bilateral (3, 4, 9, 10). The presence of a painless mass in the cervical region is a common feature in all cases. Two of them also presented sialoliths in the dilated area (3, 4).

The pathogenesis of osseous metaplasia in cases of sialocele is not yet known (9). What is known is that trauma and chronic inflammation can be considered causative agents, which would be compatible with the abundant inflammatory process observed in the wall of sialoceles (5).

The treatment of this disease is based on surgical extraction (1, 8, 11, 12). Drainage is not sufficient to treat sialocele (1, 2). In the present case, the treatment method chosen was based on what the current literature indicates, that is, through surgical excision, which proved to be curative.

This report details the fifth known case of bone metaplasia linked to sialocele in dogs, with the first instance observed bilaterally. The limited published research on salivary gland lesions creates challenges in drawing definitive conclusions about their etiology and pathogenesis. This limitation may be due to the infrequency of such lesions or a lower emphasis on the importance of salivary glands, given their rarity of malignant behavior. Nonetheless, an increased number of case reports in this field may facilitate future epidemiological and pathogenic research.

Conflict of Interest

The authors declare no competing interests.

References

- Bellenger CR, Simpson DJ. Canine sialocele – 60 clinical cases. *J Small Anim Pract.* 1992;33(8):376-80.
- Dunning D. Oral cavity. In: Slatter D, editor. *Textbook of Small Animal Surgery.* Philadelphia: WB Saunders; 2003. p. 558-9.
- Farajli-Abbasi M, Azizi S, Kheirandish, R, Azari O, Nikzad R, Farajli-Abbasi M. Surgical treatment of sialocele associated with osseous metaplasia and sialolith in a Terrier dog. *Iran J Vet Surg.* 2018;13(2):65-70.
- Fernandes TR, Grandi F, Monteiro LN, Salgado BS, Rocha RM, Rocha NS. Ectopic ossification presenting as osteoid metaplasia in a salivary mucocele in a Shih Tzu dog. *BMC Vet Res.* 2012;8:13.
- Gelberg HB. Alimentary system. In: McGavin MD, Zachary JF, editors. *Pathologic Basis of Veterinary Disease.* Missouri: Mosby; 2007. p. 301-91.
- Head KW, Else RW, Dubizielg RR. Tumors of the alimentary tract. In: Meuten DJ, editor. *Tumors in domestic animals.* Ames: Iowa State Press; 2002. p. 401-82.
- Karbe E, Nielsen SW. Canine ranulas, salivary mucoceles and branchial cysts. *J Small Anim Pract.* 1966;7(10):625-30.
- Kazemi D, Doustar Y, Assadnassab G. Surgical treatment of a chronically recurring case of cervical mucocele in a German Shepherd dog. *Case Rep Vet Med.* 2012;2012:954343.
- Park JK, Han JY, Hong IH, Hwang OK, Hong KS, Ji AR, Ki MR, Park SI, Kim TH, Choi DH, Jeong KS. Salivary mucocele with osseous metaplasia in a dog. *J Vet Med Sci.* 2009;71(7):975-7.
- Prassinis NN, Tontis DK, Adamama-Moraitou Kk, Galatos AD, Siochu A. Metaplastic ossification of a cervical sialocele in a dog. *Aust Vet J.* 2005;83(7):421-3.
- Radlinsky MG. Cirurgia do sistema digestório. In: Fossum TW, editor. *Cirurgia de Pequenos Animais.* Rio de Janeiro: Mosby Elsevier; 2015. p. 417-22.
- Rahal SC, Nunes AL, Teixeira CR, Cruz ML. Salivary mucocele in a wild cat. *Can Vet J.* 2003;44(11):933-4.
- Spreull JS, Head KW. Cervical salivary cysts in the dog. *J Small Anim Pract.* 1967;8(1):17-35.
- Taney K, Smith MM. Oral and salivary gland disorders. In: Ettinger SJ, Feldman EC, editors. *Textbook of veterinary internal medicine.* Philadelphia: Elsevier; 2010. p. 1479-86.
- Uzal FA, Plattner BL, Hostetter JM. Alimentary system. In: Maxie MG, editor. *Jubb, Kennedy & Palmer's Pathology of domestic animals.* Missouri: Elsevier; 2016. p. 28-30.
- Yasuno H, Nagai H, Ishimura Y, Watanabe T, Yamasaki H, Anayama H, Takai Y, Yamauchi H, Hara Y, Murai F, Kandori H. Salivary mucocele in a laboratory beagle. *J Toxicol Pathol.* 2011;24(2):131-5.