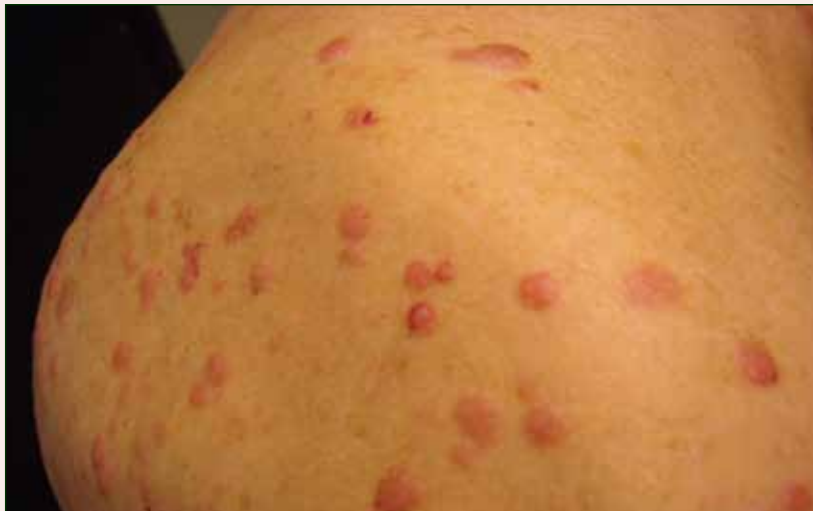

Multiple Firm Pink Papules and Nodules

What's the diagnosis?



A 91-year-old man presented with numerous, scattered, asymptomatic, 3- to 9-mm, smooth, firm, pink papules and nodules involving the neck, trunk, and arms and legs of 1 week's duration.

Christine C. Tam, MD; Kerith E. Spicknall, MD; Adam A. Ingraffea, MD

From the Department of Dermatology, University of Cincinnati, Ohio.

The authors report no conflict of interest.

Correspondence: Christine C. Tam, MD, 16000 Pearl Rd, Strongsville, OH 44136 (cctammd@gmail.com).

The Diagnosis: Myeloid Leukemia Cutis

Leukemia cutis represents the infiltration of leukemic cells into the skin. It has been described in the setting of both myeloid and lymphoid leukemia. In the setting of acute myeloid leukemia, it has been reported to occur in 2% to 13% of patients overall,^{1,2} but it may occur in 31% of patients with the acute myelomonocytic or acute monocytic leukemia subtypes.³ Leukemia cutis is less common, with chronic myeloid leukemia occurring in 2.7% of patients in one study.⁴ In another study, 65% of patients with myeloid leukemia cutis had an acute myeloid leukemia.⁵

Myeloid leukemia cutis has been reported in patients aged 22 days to 90 years, with a median age of 62 years. There is a male predominance (1.4:1 ratio).^{5,6} The diagnosis of leukemia cutis is made concurrently with the diagnosis of leukemia in approximately 30% of cases, subsequent to the diagnosis of leukemia in approximately 60% of cases, and prior to the diagnosis of leukemia in approximately 10% of cases.⁵

Clinically, myeloid leukemia cutis presents as an asymptomatic solitary lesion in 23% of cases or as multiple lesions in 77% of cases. Lesions consist of pink to red to violaceous papules, nodules, and

macules that are occasionally purpuric and involve any cutaneous surface.⁵

Histologically, the epidermis is unremarkable. Beneath a grenz zone within the dermis and usually extending into the subcutis there is a diffuse or nodular proliferation of neoplastic cells, often with perivascular and periadnexal accentuation and sometimes single filing of cells between collagen bundles (Figure 1). The cells are immature myeloid cells with irregular nuclear contours that may be indented or reniform (Figure 2). Nuclei contain finely dispersed chromatin with variably prominent nucleoli.^{5,6} Immunohistochemically, CD68 is positive in approximately 97% of cases, myeloperoxidase in 62%, and lysozyme in 85%. CD168, CD14, CD4, CD33, CD117, CD34, CD56, CD123, and CD303 are variably positive. CD3 and CD20, markers of lymphoid leukemia, are negative.^{5,8}

Leukemia cutis in the setting of a myeloid leukemia portends a grave prognosis. In a series of 18 patients, 16 had additional extramedullary leukemia, including meningeal leukemia in 6 patients.² Most patients with myeloid leukemia cutis die within an average of 1 to 8 months of diagnosis.⁹

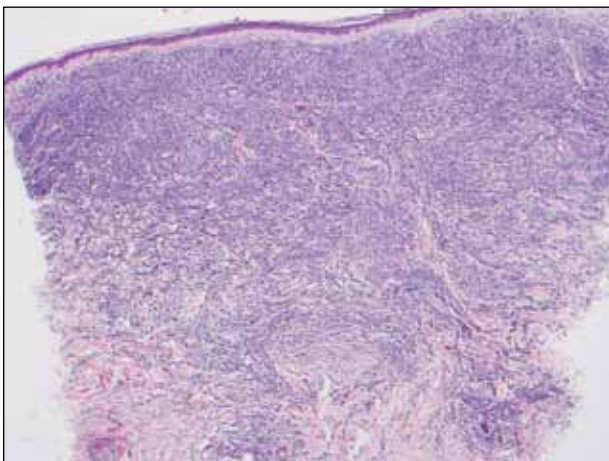


Figure 1. Beneath a grenz zone, a diffuse proliferation of neoplastic cells with single filing of cells between collagen bundles (H&E, original magnification $\times 40$).

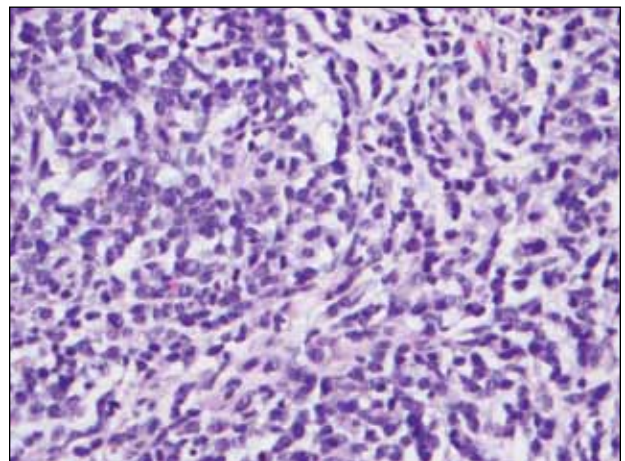


Figure 2. Pleomorphic cells with variably indented nuclei were seen (H&E, original magnification $\times 400$).

REFERENCES

1. Boggs DR, Wintrobe MM, Cartwright GE. The acute leukemias. analysis of 322 cases and review of the literature. *Medicine (Baltimore)*. 1962;41:163-225.
2. Baer MR, Barcos M, Farrell H, et al. Acute myelogenous leukemia with leukemia cutis. eighteen cases seen between 1969 and 1986. *Cancer*. 1989;63:2192-2200.
3. Straus DJ, Mertelsmann R, Koziner B, et al. The acute monocytic leukemias: multidisciplinary studies in 45 patients. *Medicine (Baltimore)*. 1980;59:409-425.
4. Rosenthal S, Canellos GP, DeVita VT Jr, et al. Characteristics of blast crisis in chronic granulocytic leukemia. *Blood*. 1977;49:705-714.
5. Bénét C, Gomez A, Aguilar C, et al. Histologic and immunohistologic characterization of skin localization of myeloid disorders: a study of 173 cases. *Am J Clin Pathol*. 2011;135:278-290.
6. Cronin DM, George TI, Sundram UN. An updated approach to the diagnosis of myeloid leukemia cutis. *Am J Clin Pathol*. 2009;132:101-110.
7. Cho-Vega JH, Medeiros LJ, Prieto VG, et al. Leukemia cutis. *Am J Clin Pathol*. 2008;129:130-142.
8. Kaddu S, Zenahlik P, Beham-Schmid C, et al. Specific cutaneous infiltrates in patients with myelogenous leukemia: a clinicopathologic study of 26 patients with assessment of diagnostic criteria. *J Am Acad Dermatol*. 1999;40:966-978.
9. Su WP, Buechner SA, Li CY. Clinicopathologic correlations in leukemia cutis. *J Am Acad Dermatol*. 1984;11:121-128.