

Prof. Ivo Šteiner, MD, PhD, Editor

CASE 2-2010: MASSIVE MYOCARDIAL CALCIFICATION IN AN ELDERLY WOMAN

Martin Jakl^{1,2}, Miroslav Podhola³, Radek Pudil²

University of Defense, Faculty of Military Health Sciences, Department of Field Internal Medicine, Hradec Králové, Czech Republic¹; Charles University in Prague, Faculty of Medicine and University Hospital Hradec Králové, Czech Republic: 1st Department of Internal Medicine², The Fingerland Department of Pathology³

Clinical data

81-year-old woman with known history of severe aortic stenosis, severe tricuspid regurgitation and mitral regurgitation was referred with dyspnoea, peripheral oedema and palpitations because of acute decompensation of chronic heart failure.

In medical history, the patient denied any other prior or chronic disease apart from osteoarthritis.

On physical examination, the patient had a blood pressure of 117/70 mmHg, an irregular pulse, heart rate of 120 beats per minute, and a respiratory rate of 18 breaths per minute. Her temperature was 36.3 °C. A loud systolic ejection murmur grade 4/6 was audible over the aortic valve; jugular veins were distended, lower limbs edema spread to knees. ECG showed atrial fibrillation with heart rate 120/min and non-specific ST-T changes. Laboratory investigations revealed blood urea nitrogen concentration of 11.5 mmol/l, creatinine 78 µmol/l and uric acid 490 µmol/l; plasma calcium and phosphate level were within the normal limits and markers of myocardial necrosis were negative. Chest X-ray demonstrated dilatation of the upper zone pulmonary vessels and opacity in the area of the left ventricle (Fig. 1). Two-dimensional echocardiography revealed calcified aortic stenosis (systolic peak/mean gradient 91/51 mmHg, aortic valve area was 0.35 cm²/m² according to planimetry and 0.45 cm²/m² calculated by the continuity equation) (5), moderate mitral regurgitation with annular calcification (Fig. 2) and tricuspid regurgitation. The ejection fraction of the left ventricle was 31 % and there was left ventricular hypertrophy and moderate pulmonary hypertension. Hyperechogenic tissue areas were detected in the interventricular septum and in the left ventricular wall (Fig. 3).

During hospitalization the patient underwent DC-cardioversion. After diuretic treatment she was hemodynamically stable and heart catheterization with coronary angiography was planned. But few days later, however, the patient suddenly died.

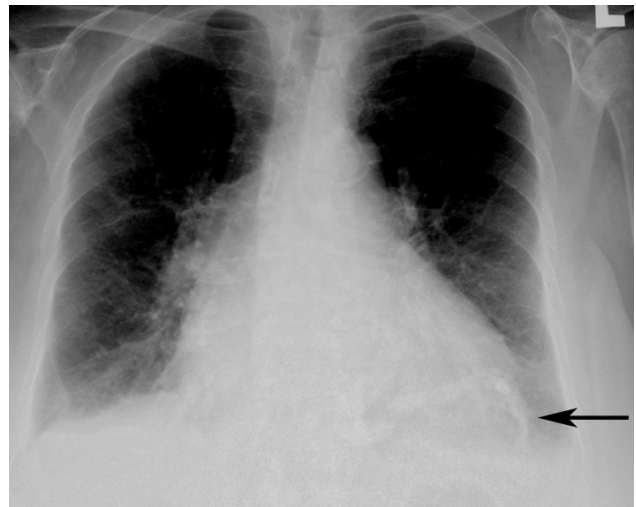


Fig. 1: Chest X-ray showing myocardial calcification (arrow).

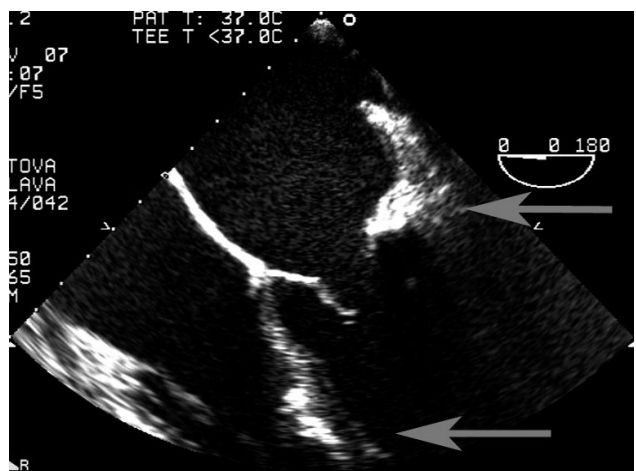


Fig. 2: TEE image showing calcification of mitral annulus and interventricular septum (arrows).

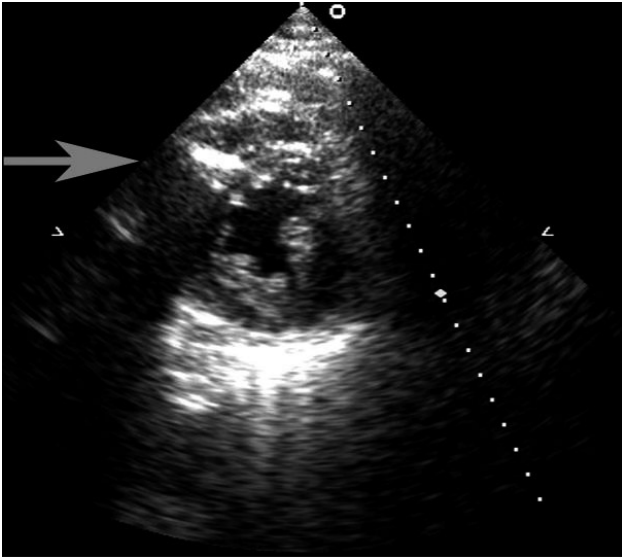


Fig. 3: Hyperechogenic areas of myocardial calcifications in the interventricular septum and in the left ventricular wall (arrows).

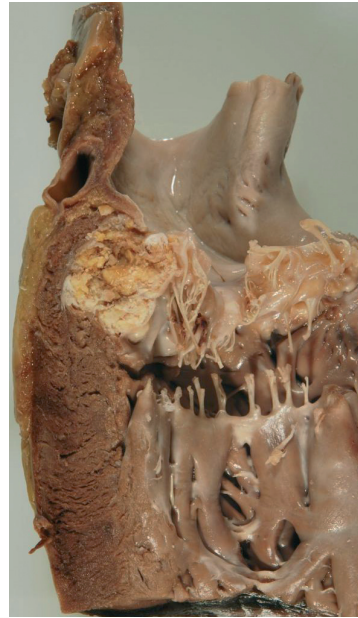

Fig. 4: Autopsy image of calcified mitral annulus.

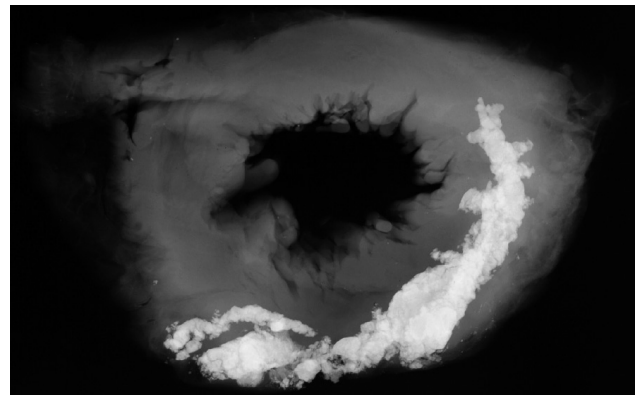


Fig. 5: Autopsy image of myocardial calcifications in the interventricular septum and in the left ventricular wall and X-ray image of a selected area.

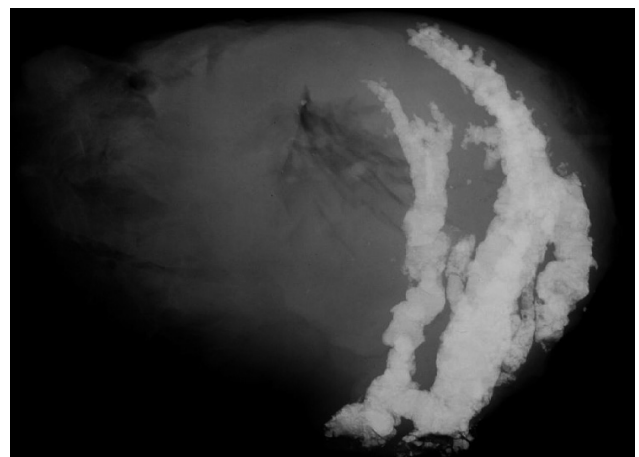
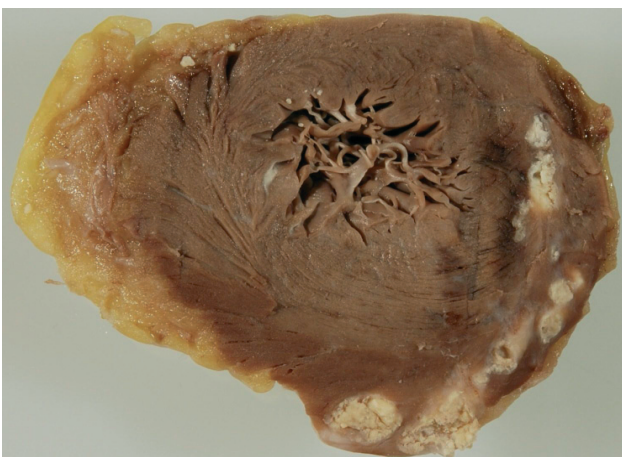


Fig. 6: Autopsy image of myocardial calcifications in the left ventricular apex and X-ray image of a selected area.

Pathological findings

Autopsy confirmed severe calcified aortic valve stenosis and large masses of calcifications located in the interventricular septum, left ventricular wall and in the mitral annulus (native pictures and post-mortem X-ray are shown in Figs. 4–6). Surprisingly, coronary arteries were without sclerotic plaques. In histological examination of myocardium, there was no sign of inflammation or neoplasia. No other calcifications were found. The parathyroid glands were of normal size and histology. On that account the aetiology of calcifications remains unclear.

Discussion

Myocardial calcifications are rare and are usually found only at autopsy. They can be detected as accidental finding during X-ray examinations, CT or MRI exams, less frequently they are visible in echocardiography. Myocardial calcifications can be of dystrophic or metastatic origin (1–3). The dystrophic calcifications are more frequent; they occur in devitalized or degenerate tissues, areas of necrosis or hemorrhage. They can develop in the course of myocarditis, systemic lupus erythematosus, rheumatic fever, chest irradiation, myocardial abscess, tuberculosis, pituitary adenoma or endomyocardial fibrosis. Congenital cardiomyopathy associated with myocardial calcification was described as well. Metastatic myocardial calcification is associated with hyperparathyroidism, D-hypervitaminosis, renal failure and Paget's disease, usually accompanied by deposits of calcium in other organs, particularly in lungs, stomach and kidneys.

None of these conditions was confirmed in this patient and the cause of calcifications remains unclear. Kirk and Russell (4) noted one patient with myocardial calcification of similar shape associated with a severely calcified bicuspid aortic valve, associated with neither metastatic deposition nor coronary artery disease. Aetiology of calcification in this patient remains unclear.

In this patient, there is no direct evidence of relationship between myocardial and valvular calcification, but ab-

sence of any other calcification in the organism and the previous report of a similar patient makes a relationship between those two forms of heart calcifications possible.

Message from Editor (Prof. Šteiner)

Calcifications in the heart are common. Most of them are of dystrophic character, i.e. deposition of calcium salts into necrotic, degenerate, or scar tissue (coronary artery atherosclerotic plaques, sclerotic aortic valve, mitral annulus), with normal calcemia. Metastatic calcification, i.e. deposition into normal cardiac tissues, in hypercalcemia is much rarer.

Calcific aortic stenosis and mitral annular calcification observed in the presented case are relatively frequent findings in the elderly. On the other hand, calcification of the heart muscle (except in postinfarction scars and chronic ventricular aneurysms) is rare, and massive myocardial calcification is highly exceptional. During my long career as a cardiopathologist, I have encountered only one similar case in a 19-year-old African (6). In the literature generally, reports on massive myocardial calcification are scarce.

The etiopathogenesis of myocardial calcification in the presented case (as well as in the literature ones) is obscure. It has features of dystrophic calcification. Its origin is certainly not postischemic. It can only be speculated on the possibility of a preceding myocarditis or some other myocardial damage.

References

1. Camm AJ, Bunce NH. Cardiovascular disease, in Kumar P, Clark M Clinical medicine. 6th ed. London: Elsevier Saunders Limited, 2005: 725–871.
2. Hudson REB. Cardiovascular Pathology. Vol. 2, London: Edward Arnold Pub, 1965: 1315–1323
3. Hudson REB. Cardiovascular Pathology. Vol. 3, London: Edward Arnold Publ, 1970: 752–755
4. Kirk RS, Russell JG. Spiral calcification in the ventricular myocardium. *Br Heart J*; 1966; 28: 342–9.
5. Otto CM, Pearlman AS, Nelson JC, et al. Experimental validation of Doppler echocardiographic measurement of volume flow through the stenotic aortic valve. *Circulation* 1988; 78: 435–41.
6. Steiner I. Calcification in the heart. II. Massive calcification of the myocardium. *Cesk Patol*. 1985; May; 21(2): 96–101.

Corresponding author:

Martin Jakl, M.D., Department of Internal Medicine I, University Hospital in Hradec Králové, Sokolská 581, 500 05 Hradec Králové, Czech Republic; e-mail: jaklm@seznam.cz
