

# Original Article

## Effects of hyperoxia on Wistar rat lungs\*

Samuel dos Santos Valença<sup>1</sup>, Milena Leonarde Kloss<sup>2</sup>, Frank Silva Bezerra<sup>3</sup>,  
Manuella Lanzetti<sup>4</sup>, Fabiano Leichsenring Silva<sup>5</sup>, Luís Cristóvão Porto<sup>6</sup>

### Abstract

**Objective:** To study the effects of short-term exposure to high oxygen concentrations (hyperoxia) on Wistar rat lungs. **Methods:** Animals were divided into three groups exposed to hyperoxia for 10', 30' and 90' (O10', O30', O90', respectively), together with a control group (exposed to room air). The animals were sacrificed 24 h after exposure. Bronchoalveolar lavage was performed, and the lungs were removed for histological and stereological analysis. **Results:** In the O10', O30', and O90' groups, respectively and in comparison with the controls, we observed an increase in the numbers of macrophages ( $2169.9 \pm 118.0$ ,  $1560.5 \pm 107.0$ , and  $1467.6 \pm 39.0$  vs.  $781.3 \pm 78.3$ ) and neutrophils ( $396.3 \pm 35.4$ ,  $338.4 \pm 17.3$ , and  $388.7 \pm 11.7$  vs.  $61.6 \pm 4.2$ ), concomitant with an increase in oxidative damage ( $143.0 \pm 7.8\%$ ,  $180.4 \pm 5.6\%$ , and  $235.0 \pm 13.7$  vs.  $100.6 \pm 1.7\%$ ). The histological and stereological analyses revealed normal alveoli and alveolar septa in the controls ( $83.51 \pm 1.20\%$  and  $15 \pm 1.21\%$ ), in the O10' group ( $81.32 \pm 0.51\%$  and  $16.64 \pm 0.70\%$ ), and in the O30' group ( $78.75 \pm 0.54\%$  and  $17.73 \pm 0.26\%$ ). However, in the O90' group, inflammatory cell infiltration was observed in the alveoli and alveolar septa. Red blood cells extravasated from capillaries to the alveoli ( $59.06 \pm 1.22\%$ ), with evidence of congestion, hemorrhage, and septal edema ( $35.15 \pm 0.69\%$ ). **Conclusion:** Hyperoxia for 90' caused injury of the lung parenchyma, resulting in oxidative damage and inflammatory cell infiltration.

**Keywords:** Hyperoxia; Lung/injuries; Oxidative stress.

\* Study conducted in the Laboratory of Tissue Repair of the Department of Histology and Embriology at the *Universidade do Estado do Rio de Janeiro* – UERJ, Rio de Janeiro State University – Rio de Janeiro, Brazil and at the Research Center of the *Faculdade Adventista da Bahia* – FAB, Adventist School of Bahia – Cachoeira, Brazil.

1. Visiting Professor in the Department of Histology and Embriology at the *Universidade do Estado do Rio de Janeiro* – UERJ, Rio de Janeiro State University – Rio de Janeiro, Brazil.

2. Undergraduate Student in Physical Therapy at the *Faculdade Adventista da Bahia* – FAB, Adventist School of Bahia – Cachoeira, Brazil.

3. Doctoral Student in the Department of Histology and Embriology at the *Universidade do Estado do Rio de Janeiro* – UERJ, Rio de Janeiro State University – Rio de Janeiro, Brazil.

4. Undergraduate Student in Nutrition in the Department of Histology and Embriology at the *Universidade do Estado do Rio de Janeiro* – UERJ, Rio de Janeiro State University – Rio de Janeiro, Brazil.

5. Assistant Professor at the Research Center of the *Faculdade Adventista da Bahia* – FAB, Adventist School of Bahia – Cachoeira, Brazil.

6. Full Professor in the Department of Histology and Embriology at the *Universidade do Estado do Rio de Janeiro* – UERJ, Rio de Janeiro State University – Rio de Janeiro, Brazil.

Correspondence to: Samuel dos Santos Valença. Departamento de Histologia e Embriologia, IBRAG-UERJ, Av. Professor Manoel de Abreu, 444, 3º andar, Maracanã, CEP 20550-170, Rio de Janeiro, RJ, Brazil.

Tel 55 21 2587 6509. Fax 55 21 2587 8164. E-mail: samuelv@hotmail.com

Submitted: 25 October 2006. Accepted, after review: 9 March 2007.

## Introduction

Supplemental oxygen is typically administered to individuals with severe heart or lung disease who required increased oxygen availability for the treatment of tissue hypoxia.<sup>(1)</sup> However, exposure to high concentrations of oxygen (>50%) for prolonged periods causes acute hyperoxic lung injury.<sup>(2)</sup> This response is characterized by damage to the epithelium and endothelium, with extravasation of proteins.<sup>(3)</sup> Studies have shown that reactive oxygen species are partially responsible for these effects, leading to cell death by necrosis.<sup>(4)</sup>

High concentrations of supplemental oxygen cause noncardiogenic lung edema,<sup>(5)</sup> formation of hyaline membrane,<sup>(6)</sup> damage to the type 1 pneumocyte,<sup>(7)</sup> type 2 pneumocyte hyperplasia,<sup>(8)</sup> neutrophil infiltration,<sup>(9)</sup> alveolar hemorrhage, and thickening of the alveolar septum.<sup>(10)</sup> These changes in the lungs are mediated by oxidative stress with protein oxidation, lipid peroxidation of the membrane, and rupture of the DNA strand.<sup>(11)</sup> In addition, hyperoxia causes release of a great number of pro-inflammatory cytokines, such as the tumor necrosis factor alpha (TNF- $\alpha$ ) and interleukin 1-beta.<sup>(12)</sup> The exact mechanisms of oxygen toxicity in the lung are complex, and evidence suggests that reactive oxygen species, such as superoxide anion, the hydroxyl radical, and hydrogen peroxide, are important mediators of lung injury.<sup>(13,14)</sup>

However, studies with time variance maintaining a high concentration of oxygen are rare, and the main focus has been the variance or concentration of supplemental oxygen. In this study, we focused on inflammatory cell kinetics, the histological pattern, the stereological analysis, and the oxidative damage induced by supplementation of a high concentration of oxygen, in different periods, acutely, in Wistar rat lungs.

## Methods

### Animals

We used 20 eight-week-old (180-200 g) male Wistar rats, divided into groups of five animals per cage, housed in the animal facilities of the Research Center at the Adventist School of Bahia, with controlled temperature and humidity ( $21 \pm 2$  °C and  $50 \pm 10\%$ , respectively), submitted to inverted 12 h

light/dark cycles (artificial light from 7 pm to 7 am), and exhaust for 15 min/h. The animals were divided into the following groups:

- Control group – rats exposed to the same conditions as the experimental group in room air;
- O10' group – rats exposed to hyperoxia for 10 min;
- O30' group – rats exposed to hyperoxia for 30 min; and
- O90' group – rats exposed to hyperoxia for 90 min.

The animals received balanced standard food and water *ad libitum* throughout the experimental period. This project was approved by the ethics committee for studies with laboratory animals of the Roberto Alcântara Gomes Institute of Biology, Rio de Janeiro State University.

### Oxygen exposure

In order to expose the animals to hyperoxia, an acrylic inhalation chamber was used (length = 30 cm, width = 20 cm, and height = 15 cm). The 100% oxygen was acquired from White Martins® (White Martins Praxair Inc., São Paulo, Brazil). The oxygen tank was coupled to the inhalation chamber using a silicon conduit. The oxygen was released into the chamber at a constant flow rate of 5 L/min, thereby ensuring an oxygen supply that saturated the environment. After the space had been filled with oxygen, each rat except those in the control group (which inhaled room air) were placed in the inhalation chamber and removed after 10, 30, or 90 min.

### Histology

The animals were sacrificed one day after the end of the experiment with an i.p. injection with 50 mg/kg of thiopental (Eron, C., Havana, Cuba). The left lung was clamped, and the right lung was fixed with 10% buffered formalin (Vetec Química Fina, Duque de Caxias, Brazil) introduced through a tube inserted into the right mainstem bronchus, with the pressure continuously maintained at of 25 cm H<sub>2</sub>O using a pump (Sykam, Gewerbering, Germany). After the formalin instillation, the right mainstem bronchus was clamped. The right lung was removed *en bloc*, after which it was immersed in a fixing solution for 48 h, processed according to the laboratory routine in increasing alcohol

concentrations, cleared in xylene, and embedded in paraffin to obtain fragments from the apex, middle third, and base. Sections (5 mm in thickness) were stained with hematoxylin and eosin, as well as with Giemsa (Sigma, St. Louis, MO, USA).

### ***Stereology***

In order to obtain uniform and proportional lung samples, 18 fields (six non-overlapping fields in three different slides) were randomly analyzed with the use of a Zeiss-Axioplan video microscope fitted with a 20× objective (Carl Zeiss, Oberkochen, Germany) and a video camera (Trinitron; Sony, San Diego, CA, USA) connected to a color monitor (Trinitron; Sony). A test system (16 cycloid arches and 16 points) was superimposed on the monitor, and the reference volume was estimated by point counts. The points coinciding with the alveolar septum, alveoli or leukocytes (macrophages, neutrophils, or lymphocytes) were counted to estimate the volume density of these structures. A total area of 1.94 mm<sup>2</sup> was analyzed in order to determine the volume density of the alveolar septum and the alveoli in the slides stained with hematoxylin and eosin, as well as that of the leukocytes in the slides stained with Giemsa. Two researchers counted the unidentified slides at different times.<sup>(15)</sup>

### ***Bronchoalveolar lavage***

The left lung underwent lavage once with 2 mL of saline solution through a tube inserted into the left mainstem bronchus. Soon thereafter, the samples were placed on crushed ice in order to avoid cell lysis. Subsequently, 100 µL of the bronchoalveolar lavage fluid from each animal were added to 10 mL of Isoton (Coulter Electronics, Fullerton, CA, USA) and counted in a cytometer (Coulter Electronics), after which 250 µL of the samples were cytocentrifuged (Shandon, Waltham, MA, USA) at 800 rpm/min. After obtaining the slides, a leukocyte staining kit (Diff-Quik, Baxter Dade, Dudingon, Switzerland) was used, and a total of 200 cells per slide were analyzed in order to obtain the differential count.<sup>(15)</sup>

### ***Oxidative damage analysis***

The bronchoalveolar lavage supernatant was used in order to analyze the thiobarbituric acid reactive substances (TBARS). Thiobarbituric acid

reacts with oxidative lipids, generating malondialdehyde.<sup>(15)</sup> An aliquot (300 µL) of bronchoalveolar lavage was centrifuged, and the supernatant was evaluated. The supernatant was added to 300 µL of 8.1% dodecyl sodium sulfate (Sigma), agitated and stored on crushed ice for 15 min. After centrifugation at 2000 rpm for 10 min, the supernatant was incubated with a solution of 300 µL of 0.8% thiobarbituric acid (Sigma) + 300 µL of 20% acetic acid, pH 3.5, for 1 h at 90 °C. The content was read at 532 nm using a Beckman Spectrophotometer (model DU 640; Coulter Electronics).

### ***Statistical analysis***

Data are expressed as mean ± standard deviation. The differences between the groups in the bronchoalveolar lavage and TBARS variables were tested using the one-way analysis of variance. The intergroup differences were tested using the Student-Newman-Keuls post-test. The stereology variables differences were tested using the Kruskal-Wallis test followed by Dunn's post-test. In both tests, values of  $p < 0.05$  were considered statistically significant.

## **Results**

### ***Histology***

In the control group, we observed preserved alveolar septa and fully-formed capillaries with normal-size alveoli, without inflammatory infiltrate (Figure 1a). In the O10' group, we observed a histological pattern very similar to that seen in the control group, without evident abnormalities (Figure 1b). However, in the O30' group, we observed some inflammatory cells in the alveoli and slightly thickened alveolar septum, with evident inflammatory infiltrate (Figure 1c). Despite these changes, the lung architecture did not change. In the O90' group, the extravasation of red blood cells from the capillaries, turgid septa, and a large quantity of inflammatory cells in the alveoli were evident (Figure 1d). The image suggests congestion and hemorrhage without impairment of the lung architecture.

### ***Stereology***

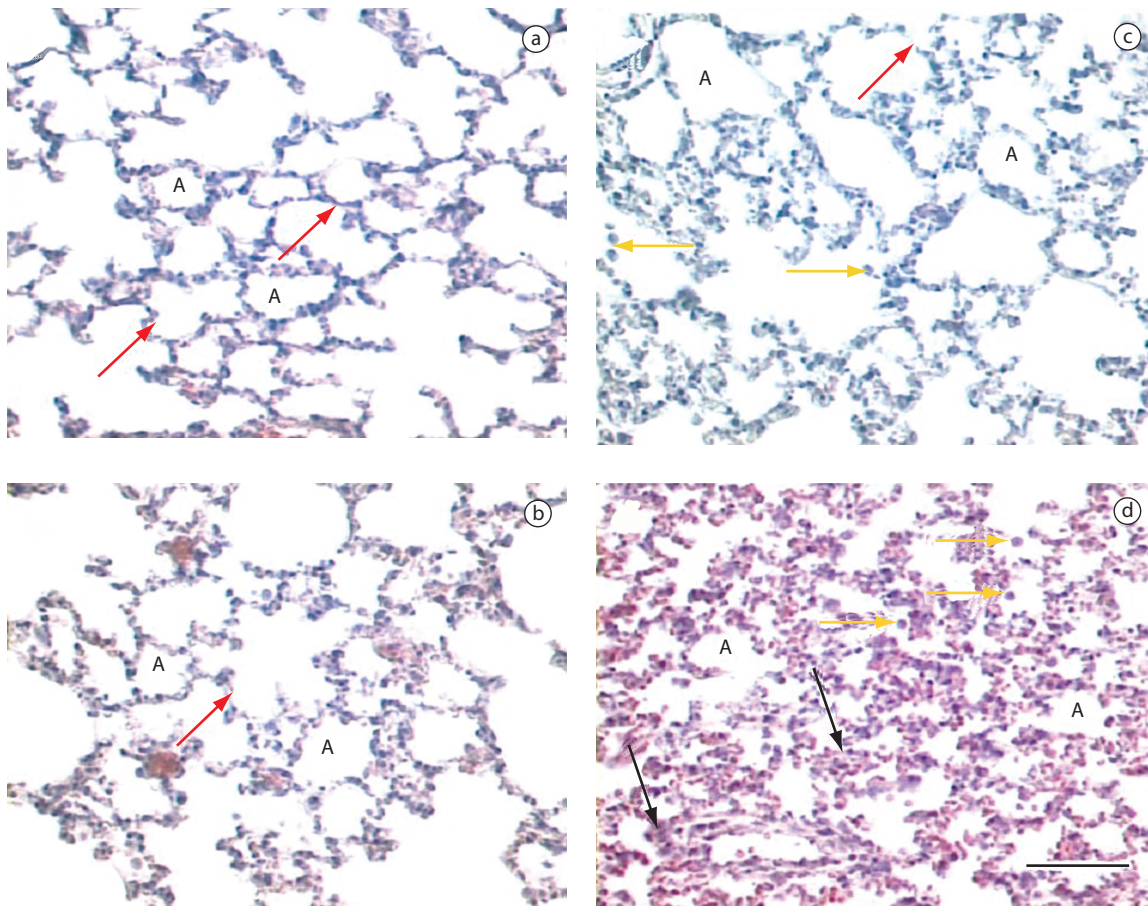
The stereology results are shown in Table 1. No differences were observed between the control

group and the O10' or O30' study groups in terms of the volume density of the alveoli, alveolar septa, and leukocytes, respectively: control:  $83.51 \pm 1.20\%$ ,  $15 \pm 1.21\%$ , and  $1.48 \pm 0.22\%$ ; O10' group:  $81.32 \pm 0.51\%$ ,  $16.64 \pm 0.70\%$ , and  $2.02 \pm 0.23\%$ ; and O30' group:  $78.75 \pm 0.54\%$ ,  $17.73 \pm 0.26\%$ , and  $3.51 \pm 0.32\%$ . However, in the O90' group, when compared with the control group, we observed significantly lower alveoli volume density ( $59.06 \pm 1.22\%$ ,  $p < 0.01$ ), concomitant to significantly greater alveolar septa volume density

( $35.15 \pm 0.69\%$ ,  $p < 0.01$ ), as well as greater leukocyte volume density ( $5.78 \pm 0.68\%$ ,  $p < 0.01$ ).

### ***Bronchoalveolar lavage***

A higher number of alveolar macrophages was observed ( $10^3/\text{mL}$ ) in the O10' group ( $216.9 \pm 118.7$ ), which was lower in the O30' group ( $1560.5 \pm 107.4$ ), and in the O90' group ( $1467.6 \pm 39.3$ ), when compared with the control group ( $781.32 \pm 78.3$ ). In addition, the groups exposed to oxygen were statistically different from the control group, with a  $p < 0.001$  (Figure 2). We found that neutrophil



**Figure 1** – Histology: a) control group with preserved alveolar septa (red arrows), fully-formed capillaries and normal-size alveoli (A) with no inflammatory infiltrate (hematoxylin and eosin, 400 $\times$ ); b) O10' group with histological pattern similar to the control group with no evident abnormalities (hematoxylin and eosin, 400 $\times$ ); c) O30' group with small inflammatory infiltrate in the alveoli (arrows) and slightly thickened alveolar septum (red arrow) with evident inflammatory infiltrate (hematoxylin and eosin, 400 $\times$ ); and d) O90' group with extravasation of red blood cells from capillaries, turgid septa (black arrows) and inflammatory cells in the alveoli (arrows) with image suggestive of congestion/hemorrhage, and no alteration of the lung architecture. (hematoxylin and eosin, 400 $\times$ ). Bar = 100  $\mu\text{m}$ .

**Table 1** - Stereological analysis of alveoli, alveolar septa, and leukocytes in the control group and in the groups exposed to oxygen in different periods.

Groups	Stereology		
	VvA (%)	VvAS (%)	VvL (%)
Control	83.51 ± 1.20	15.00 ± 1.21	1.48 ± 0.22
O10'	81.32 ± 0.51	16.64 ± 0.70	2.02 ± 0.23
O30'	78.75 ± 0.54	17.73 ± 0.26	3.51 ± 0.32
O90'	59.06 ± 1.22 <sup>a</sup>	35.15 ± 0.69 <sup>a</sup>	5.78 ± 0.68 <sup>a</sup>

VvA: alveoli volume density; VvAS: alveolar septa volume density; VvL: leukocyte volume density; O10': exposed to hyperoxia for 10 min; O30': exposed to hyperoxia for 30 min; and O90': exposed to hyperoxia for 90 min; and <sup>a</sup>p < 0.01 vs. control group.

counts were consistently higher in the O10', O30', and O90' groups (396.3 ± 35.4, 338.4 ± 17.6, and 388.7 ± 11.7, respectively) than in the control group (61.6 ± 4.2), with p < 0.001 for all groups exposed to oxygen (Figure 2).

### ***Oxidative damage analysis***

The oxidative damage was evaluated by quantifying TBARS (Figure 3). The control group value was considered 100% and those for the other groups as variations from the control group value. We found TBARS to be lower in the control group (100.6 ± 1.7) than in the O10' group (143 ± 7.8, p < 0.05), O30' group (180.4 ± 5.6, p < 0.001), or O90' group (235 ± 13.7, p < 0.001).

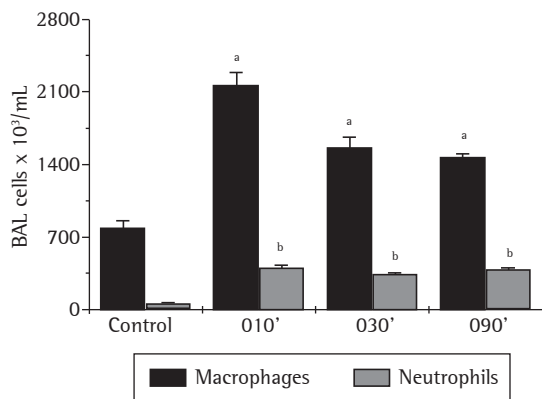
### **Discussion**

Oxygen supplementation is widely prescribed by intensive care unit professionals. When correctly administered, it can save lives. However, oxygen is often supplied without an accurate evaluation of its potential benefits and side effects. As any other drug, there are clear indications for the treatment with oxygen and appropriate methods for its administration. An inappropriate dose and failure to monitor this kind of treatment can have severe consequences. Careful monitoring to rapidly detect and correct any adverse effects is essential. The results of this study show an undesirable effect of oxygen supplied in high concentrations in parameters such as histology, stereology, bronchoalveolar lavage, and oxidative damage. Despite the influx of inflammatory cells and the oxidative damage observed in one acute experimental study,

the possible implications of altered lung architecture induced by high concentrations of oxygen in humans should not be ignored.

Our results agree with one study in which the histological analysis of rat lungs submitted to hyperoxia revealed an increase in the number of alveolar macrophages and the number of type 2 epithelial cells.<sup>(16)</sup> Moderate alveolar exudate and increased air spaces were observed. However, the histological changes appeared earlier in our animals. The prolonged exposure to high concentrations of oxygen (>50% of oxygen) during an intensive adjustment of precautions to maintain the optimal arterial oxygen tension can lead to progressive lung injury.<sup>(17,18)</sup> Macrophages, neutrophils, and lymphocytes are involved in this process. In animals exposed to oxygen >95% for 72 h, a decrease in the number of alveolar macrophages was observed, concomitant to an increase in the number of neutrophils and lymphocytes compared with the animals exposed to room air.<sup>(19)</sup> Our results demonstrate that neutrophil counts were higher in the group exposed to 100% hyperoxia than in the control group. However, no significant differences were observed in relation to lymphocyte counts. Nevertheless, we also observed an increase in the number of alveolar macrophages in the first group (O10'), which reduced as the oxygen exposure increased. The result observed in the bronchoalveolar lavage was not identical to the leukocyte volume density. We believe that as the O90' group suffered pathological changes induced by hyperoxia, the lavage result principally reflects the conditions of the influx of cells from bronchi and bronchioles. We suggest that a longer period of hyperoxia (two to four days) might reduce the number of alveolar macrophages. This supposition might be confirmed by the results of another study,<sup>(20)</sup> in which high numbers of neutrophils and lymphocytes were also found, together with lower numbers of alveolar macrophages, in the lungs of rats exposed to hyperoxia for 64 h.

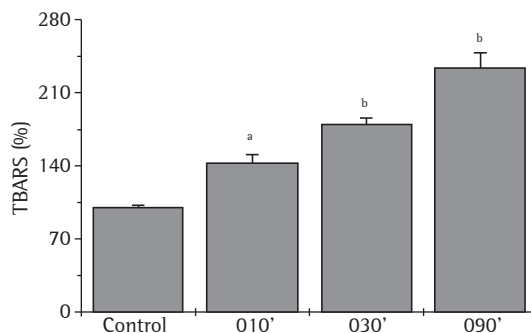
The exposure of alveolar macrophages to oxygen under normal conditions is approximately 13%. However, in circumstances of exposure to supplemental oxygen (for example, in patients with acute diseases), macrophages can be exposed to up to 90% of oxygen. It is known that macrophages, under oxidative stress conditions such as exposure to cigarette smoke, survive for prolonged periods in the lung.<sup>(21)</sup> In contrast, in vitro macro-



**Figure 2** - Analysis of the bronchoalveolar lavage (BAL) showing the time-dependent effect of hyperoxia on the influx of inflammatory cells into Wistar rat lungs; <sup>a</sup>p < 0.001 vs. controls; and <sup>b</sup>p < 0.001 vs. controls.

phages (RAW macrophages) survive prolonged periods of hyperoxia when accompanied by extracellular signal-regulated kinases (ERKs). As shown in another study,<sup>(22)</sup> macrophage survival after 24 h of hyperoxia was near 100%. However, macrophage survival after 24 h of hyperoxia with ERK inhibition was significantly reduced ( $\approx 60\%$ ) ( $p < 0.05$ ). These data support the hypothesis that hyperoxia leads to ERK activation, which is a crucial indicator of sustained macrophage vitality.

The activation of inflammatory cells causes the release of reactive oxygen species and pro-inflammatory cytokines, resulting in endothelial dysfunction, formation of edema in the alveolar tissue, and surfactant inactivation.<sup>(23)</sup> In the present study, it was not possible to determine the levels of cytokines involved in the inflammatory process or to study the nuclear factors involved in the activation of these cells. However, pro-inflammatory cytokines, such as TNF- $\alpha$  and interferon gamma (IFN- $\gamma$ ), can trigger the process of lung injury. Recent studies detected increased concentrations of TNF- $\alpha$  e IFN- $\gamma$  in the lungs of animals exposed to hyperoxia before the neutrophil infiltration became evident.<sup>(24)</sup> Another study showed that rats not expressing the TNF receptor, the TNF I receptor, or the TNF II receptor remain susceptible to hyperoxia, suggesting that TNF- $\alpha$  is not a key molecule in hyperoxia-induced lung injury.<sup>(25)</sup> It is known that IFN- $\gamma$  is released in the lung by inflammatory cells, including lymphocytes, after exposure to hyperoxia.<sup>(26)</sup> Various studies have



**Figure 3** - Time-dependent effect of hyperoxia on the oxidative damage analyzed by quantifying thiobarbituric acid reactive substances (TBARS); <sup>a</sup>p < 0.05 vs. controls; <sup>b</sup>p < 0.001 vs. controls.

shown that IFN- $\gamma$  induces apoptosis in several cell types, including lung epithelial cells, and mediates lung injury.<sup>(9)</sup>

The pathogenesis of hyperoxia-induced lung injury is not well known. However, it is believed to be mediated by the direct damage to the cell through the generation of reactive oxygen species.<sup>(27,28)</sup> It is generally accepted that the increased production of reactive oxygen species play an important role in triggering lung injury during exposure to hyperoxia.<sup>(29)</sup> Oxidative damage can be evinced by TBARS-induced peroxidation of lipids in the lung.<sup>(30)</sup> One study demonstrated a pronounced increase in TBARS concentration ( $146.0 \pm 62.0$  nmol/mL) in rats exposed to hyperoxia when compared with those in normoxia ( $35.0 \pm 14.0$  nmol/mL), and the supply of oxygen at 60% ( $31.0 \pm 17.0$  nmol/mL).<sup>(29)</sup> We observed that Wistar rats exposed to hyperoxia for 10, 30, or 90 min present greater oxidative damage, as analyzed through quantification of TBARS, and that this damage progresses in parallel with the duration of exposure. The maximum oxidative damage observed in the O90' group is consistent with the leukocyte volume density, emphasizing that, in this case, this response could also be explained by the accumulation of leukocytes in the alveolar septum. Although it was not possible to determine which reactive oxygen species were involved in the production of oxidative damage, we believe that oxygen plays a crucial role.

The results of this study suggest that the exposure to hyperoxia is prejudicial and harmful to Wistar rat lungs. It was not possible to ensure in this study that 100% hyperoxia was achieved. However, we believe that the concentration of oxygen in the exposure chamber should have approached almost this value. We suggest that time is an important and crucial factor in the process of hyperoxia-induced injury. The observation of this model is likely to be extended to human beings, although the introduction of doses and duration remain less than fully clarified. The pathophysiological mechanisms involved in the lung injury induced by oxygen are complex. Nevertheless, we suggest that, even in an acute phase, oxygen supplementation has deleterious effect for the lung.

## References

- O'Reilly MA. DNA damage and cell cycle checkpoints in hyperoxic lung injury: braking to facilitate repair. *Am J Physiol Lung Cell Mol Physiol.* 2001;281(2):291-305.
- Bhandari V, Choo-Wing R, Lee CG, Zhu Z, Nedrelov JH, Chupp GL, et al. Hyperoxia causes angiotensin 2-mediated acute lung injury and necrotic cell death. *Nat Med.* 2006;12(11):1286-93.
- Barazzone C, White CW. Mechanisms of cell injury and death in hyperoxia: role of cytokines and Bcl-2 family proteins. *Am J Respir Cell Mol Biol.* 2000;22(5):517-9.
- Brueckl C, Kaestle S, Kerem A, Habazettl H, Krombach F, Kuppe H, et al. Hyperoxia-induced reactive oxygen species formation in pulmonary capillary endothelial cells in situ. *Am J Respir Cell Mol Biol.* 2006;34(4):453-63.
- Song Y, Fukuda N, Bai C, Ma T, Matthay MA, Verkman AS. Role of aquaporins in alveolar fluid clearance in neonatal and adult lung, and in oedema formation following acute lung injury: studies in transgenic aquaporin null mice. *J Physiol.* 2000;525 Pt 3:771-9.
- Matthew E, Kutcher L, Dedman J. Protection of lungs from hyperoxic injury: gene expression analysis of cyclosporin A therapy. *Physiol Genomics.* 2003;14(2):129-38.
- Lian X, Qin Y, Hossain SA, Yang L, White A, Xu H, et al. Overexpression of Stat3C in pulmonary epithelium protects against hyperoxic lung injury. *J Immunol.* 2005;174(11):7250-6.
- Babu PB, Chidekel A, Shaffer TH. Hyperoxia-induced changes in human airway epithelial cells: the protective effect of perflubron. *Pediatr Crit Care Med.* 2005;6(2):188-94.
- Yamada M, Kubo H, Kobayashi S, Ishizawa K, Sasaki H. Interferon-gamma: a key contributor to hyperoxia-induced lung injury in mice. *Am J Physiol Lung Cell Mol Physiol.* 2004;287(5):1042-7.
- Dauger S, Ferkdadjji L, Saumon G, Vardon G, Peuchmaur M, Gaultier C, et al. Neonatal exposure to 65% oxygen durably impairs lung architecture and breathing pattern in adult mice. *Chest.* 2003;123(2):530-8.
- Cotton RB, Sundell HW, Zeldin DC, Morrow JD, Roberts LJ, Hazinski TA, et al. Inhaled nitric oxide attenuates hyperoxic lung injury in lambs. *Pediatr Res.* 2006;59(1):142-6.
- Ben-Ari J, Makhoul IR, Dorio RJ, Buckley S, Warburton D, Walker SM. Cytokine response during hyperoxia: sequential production of pulmonary tumor necrosis factor and interleukin-6 in neonatal rats. *Isr Med Assoc J.* 2000;2(5):365-9.
- Narasaraju TA, Jin N, Narendranath CR, Chen Z, Gou D, Liu L. Protein nitration in rat lungs during hyperoxia exposure: a possible role of myeloperoxidase. *Am J Physiol Lung Cell Mol Physiol.* 2003;285(5):1037-45.
- Lee PJ, Choi AM. Pathways of cell signaling in hyperoxia. *Free Radic Biol Med.* 2003;35(4):341-50.
- Valenca SS, Castro P, Pimenta WA, Lanzetti M, Silva SV, Barja-Fidalgo C, et al. Light cigarette smoke-induced emphysema and NFkappaB activation in mouse lung. *Int J Exp Pathol.* 2006;87(5):373-81.
- Paine R 3rd, Wilcoxon SE, Morris SB, Sartori C, Baleeiro CE, Matthay MA, et al. Transgenic overexpression of granulocyte macrophage-colony stimulating factor in the lung prevents hyperoxic lung injury. *Am J Pathol.* 2003;163(6):2397-406.
- Barnikol WK, Pötzschke H. [Haemoglobin hyperpolymers, a new type of artificial oxygen carrier - the concept and current state of development][Article in German]. *Anesthesiol Intensivmed Notfallmed Schmerzther.* 2005;40(1):46-58.
- Zhu CP, Du J, Li QP, Feng ZC. [Effect of lethal hyperoxia on pulmonary development and lung injury in neonatal rats][Article in Chinese]. *Nan Fang Yi Ke Da Xue Xue Bao.* 2006;26(7):945-8.
- Horinouchi H. [Role of polymorphonuclear leukocytes in experimental lung injury--chemotaxis and active oxygen metabolite production][Article in Japanese]. *Nippon Geka Gakkai Zasshi.* 1990;91(6):741-8.
- Balaan MR, Bowman L, Dedhia HV, Miles PR. Hyperoxia-induced alterations of rat alveolar lavage composition and properties. *Exp Lung Res.* 1995;21(1):141-56.
- Horinouchi H, Wang CC, Shepherd KE, Jones R. TNF alpha gene and protein expression in alveolar macrophages in acute and chronic hyperoxia-induced lung injury. *Am J Respir Cell Mol Biol.* 1996;14(6):548-55.
- Nyunoya T, Monick MM, Powers LS, Yarovinsky TO, Hunninghake GW. Macrophages survive hyperoxia via prolonged ERK activation due to phosphatase down-regulation. *J Biol Chem.* 2005;280(28):26295-302.
- Hesse AK, Dörger M, Kupatt C, Krombach F. Proinflammatory role of inducible nitric oxide synthase in acute hyperoxic lung injury. *Respir Res.* 2004;5:11.
- Vondráček J. Effects of recombinant rat tumor necrosis factor-alpha and interferon-gamma on the respiratory burst of rat polymorphonuclear leukocytes in whole blood. *Folia Biol (Praha).* 1997;43(3):115-21.
- Pryhuber GS, O'Brien DP, Baggs R, Phipps R, Huyck H, Sanz I, et al. Ablation of tumor necrosis factor receptor type 1 (p55) alters oxygen-induced lung injury. *Am J Physiol Lung Cell Mol Physiol.* 2000;278(5):1082-90.
- Granowitz EV, Skulsky EJ, Benson RM, Wright J, Garb JL, Cohen ER, et al. Exposure to increased pressure or hyperbaric oxygen suppresses interferon-gamma secretion in whole blood cultures of healthy humans. *Undersea Hyperb Med.* 2002;29(3):216-25.
- Nagata K, Iwasaki Y, Yamada T, Yuba T, Kono K, Hosogi S, et al. Overexpression of manganese superoxide dismutase

- by N-acetylcysteine in hyperoxic lung injury. *Respir Med.* 2007;101(4):800-7.
28. Xu D, Guthrie JR, Mabry S, Sack TM, Truog WE. Mitochondrial aldehyde dehydrogenase attenuates hyperoxia-induced cell death through activation of ERK/MAPK and PI3K-Akt pathways in lung epithelial cells. *Am J Physiol Lung Cell Mol Physiol.* 2006;291(5):966-75.
29. Wang Y, Feinstein SI, Manevich Y, Ho YS, Fisher AB. Lung injury and mortality with hyperoxia are increased in peroxiredoxin 6 gene-targeted mice. *Free Radic Biol Med.* 2004;37(11):1736-43.
30. Nader-Djalal N, Knight PR 3rd, Thusu K, Davidson BA, Holm BA, Johnson KJ, et al. Reactive oxygen species contribute to oxygen-related lung injury after acid aspiration. *Anesth Analg.* 1998;87(1):127-33.