

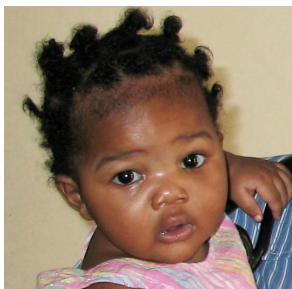

BEING BRAVE: Stories of children with drug-resistant tuberculosis

From the Sentinel Project on Pediatric Drug-Resistant Tuberculosis, March 2012



Table of Contents



The Sentinel Project on Pediatric Drug-Resistant Tuberculosis	2
---	---

Introduction	3
--------------	---


When the System Fails	4
-----------------------	---

Thabo—Soweto, South Africa	5
----------------------------	---

Cristina—Junín, Peru	6
----------------------	---

Anna—Karachi, Pakistan	7
------------------------	---

Fetene—Addis Ababa, Ethiopia	8
------------------------------	---



Access Saves Lives	9
--------------------	---

Luka, Giorgi, and Maryam—Tbilisi, Georgia	10
---	----

Yousra—Karachi, Pakistan	11
--------------------------	----

Naleli—Mafeteng, Lesotho	12
--------------------------	----

Paki—Cape Town, South Africa	13
------------------------------	----


Sonnu—Kandivali, India	14
------------------------	----

Molahlehi—Maseru, Lesotho	15
---------------------------	----

Juan—Lima, Peru	16
-----------------	----

Lesedi—Cape Town, South Africa	17
--------------------------------	----


Oyella Mercy—Kitgum, Uganda	17
-----------------------------	----



A Call to Action	18
------------------	----

Individual contributors	19
-------------------------	----

Contributing organizations	19
----------------------------	----



The Sentinel Project on Pediatric Drug-Resistant Tuberculosis

Every year, thousands of children die from drug-resistant tuberculosis—a disease with a known cure. This happens because children do not have access to diagnosis or treatment for this disease. In spite of global advances made in tuberculosis treatment, children have been left behind.

The Sentinel Project on Pediatric Drug-Resistant Tuberculosis is a global partnership of researchers, caregivers, and advocates who have come together to end the neglect of this vulnerable population of children. We are collaborating to develop and deploy evidence-based strategies to prevent the death of children from this treatable disease; we are a learning network committed to generating and disseminating knowledge and data for immediate action.

In October 2011, the Department of Global Health and Social Medicine at Harvard Medical School (Boston, MA, USA; ghsm.hms.harvard.edu) joined forces with the National Institute for Research in Tuberculosis (Chennai, India; www.trc-chennai.org) to convene and host this partnership. Already, more than 140 individuals from more than 30 countries have come together to collaborate on joint projects.

Network members have divided into task forces currently working on projects including: developing practical field tools to guide treatment; developing consensus research definitions; designing multi-site research studies; and effecting targeted advocacy ventures, such as collecting this first set of stories.

To learn more, visit us at www.sentinel-project.org



Introduction

If we can get it right for children — if we can deliver on our commitments and enable every child to enjoy the right to a childhood, to health, education, equality and protection — we can get it right for people of all ages.

— Kofi Annan, former United Nations Secretary General, 2006



When it comes to drug-resistant tuberculosis (DR-TB), the global community is failing to “get it right.” Millions of people around the world suffer from this dangerous, yet treatable, infectious disease. Yet, in over a decade, less than 1% of those with DR-TB have been diagnosed and treated.* Children bear a disproportionate burden of this disease, and are far less likely than adults with DR-TB to have access to appropriate care.

DR-TB kills children. “When the System Fails,” the first part of this collection, offers stories of children who died from DR-TB. This usually happened because they were either diagnosed too late, or had to wait months to access therapy. This testimony to their short lives and their suffering is a warning of what awaits thousands of other children with DR-TB, unless access to quality diagnosis and treatment improves.

Children can live with DR-TB. The stories offered in the second part of this collection, “Access Saves Lives,” are all of survivors of this disease. As their stories show, they too have been brave in the face

of great suffering. Some of this suffering is due to the treatment itself, which requires each child to receive daily injections and take multiple tablets for 18–24 months. Other suffering comes from the social and psychological pain the children and their families have faced as a result of DR-TB. These stories illustrate the need for better treatment strategies and support for children. They also show that children with DR-TB can be cured with timely access to care.

This collection gives voice to the children from around the world featured in it, and to the thousands more like them who face the challenges of fighting DR-TB every day. It is also a global call to action. These stories invite all of us to join children with DR-TB and their families and caregivers in the struggle for better diagnosis and treatment. It is the first step toward “getting it right” for children with TB.

* World Health Organization, *Towards Universal Access to Diagnosis and Treatment of Multi-Drug Resistant and Extensively Drug-Resistant Tuberculosis by 2015*, WHO Progress Report 2011 (Geneva: World Health Organization, 2011).



When the System Fails

At least they gave me money for the funeral. At least this way we can finally do something nice for Thabo. We can give him a small place to rest. And to know his peace.

— Mafong Ntsibile, aunt of eight-year-old Thabo, who died of DR-TB

Thabo

8 years old — Soweto, South Africa

“He was quiet when he died,” reported Thabo’s auntie. “He hardly made a sound. I would almost never have known if it hadn’t been for the flies, really.”

These were the words that announced the death of eight-year-old Thabo, a small boy who died in Soweto, South Africa. The clinic knew Thabo well—he had first come there with his mother, a young woman who was found to be both mentally ill and to have HIV. She was admitted to the mental ward, and Thabo took to sleeping on the clinic floor until his aunt finally picked him up. Eventually, his mother’s health improved and she came home; Thabo enrolled in school. Although he remained small for his age, things were looking up for him and his family.

That soon began to change. Thabo developed a fever, and would sweat terribly in the night. He was too weak to go to school. Thabo’s mother began to cough. On a rainy morning while hanging laundry, she spat bright red blood onto a clean blue sheet. Terrified, she returned to the clinic, where she found that she had TB. Worse, the strain she had was resistant to at least one of the first-line drugs. Her clinic referred her to another hospital, but without money to go there, she hiked back home.

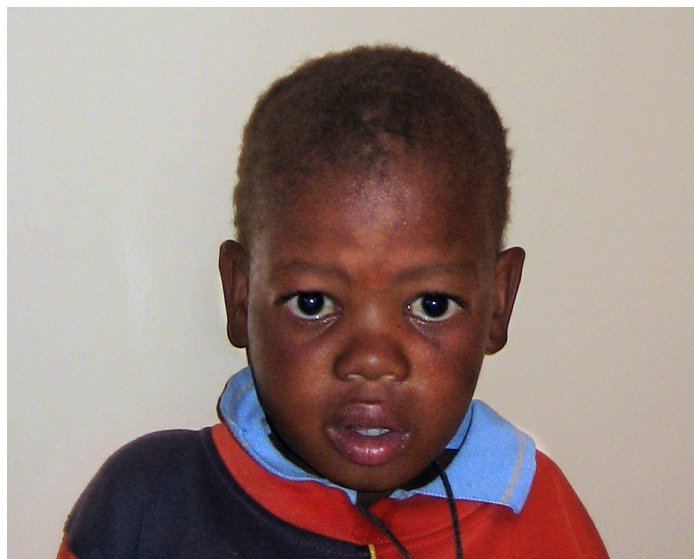Over the next weeks, Thabo and his mother became sicker and weaker. They barely ate,

and garbage piled up outside their home. His auntie finally came with money to go to the clinic. Everyone was frightened by the way the doctor stopped everything and moved quickly to Thabo’s side upon their arrival. “This boy is critical,” he said, and everyone moved to let him pass. He found large lumps in Thabo’s neck and fluid in the boy’s belly. “They must go to the other hospital now!” he shouted, so worried that he even gave them taxi fare from his own pocket.

When the hospital medical officer saw Thabo’s mother’s paper from the clinic saying she had DR-TB, he ordered her home. He was frightened for his other patients, and he did not have medicine for patients with DR-TB. He prescribed the mother and son first-line TB treatment—even though both likely had the drug-resistant form of the disease.

They lay in the grass outside the hospital and waited for days.

Thabo’s mother died there. A nursing sister who knew Thabo’s family found him, barely able to lift his head, and drove him to his auntie’s. Thabo still sweated in the night. His body still shook from chills. The lumps in his neck grew bigger and he, too, began to cough up blood. He grew smaller, but his belly grew bigger. He was visited every day by a worker from the TB clinic, and he took his first-line medications in spite of the nausea it brought him. It was just a few hours after receiving his directly observed dose of drugs that Thabo died alone in a corner, covered in flies. “At least they gave me money for the funeral,” his auntie remarked. “At least this way we can finally do something nice for Thabo. We can give him a small place to rest. And to know his peace.”




Cristina

1 year old — Junín, Peru

Baby Cristina's first birthday should have been a happy occasion. However, instead of eating cake and receiving presents, Cristina spent most of the day in the back of an old ambulance that carried her the six hours from a local hospital in central Peru to a referral hospital in Lima. By the time she arrived in the emergency department, Cristina was barely responsive to stimuli, and her left pupil was fixed and dilated—a sign of impending death from brain swelling.

Cristina lived with her family in the jungle district of Junín, one of the poorest regions in the country. Several months after Cristina was born her mother became ill, and was symptomatic for months before being diagnosed with TB.



Two weeks before her first birthday Cristina began experiencing fevers and a cough. Her parents gave her a fever-reducing medicine, but her symptoms became more severe. Five days later Cristina's parents took her to the local health center, where she was diagnosed with a cold and sent home. Two days later, Cristina had a seizure. Returning to the local hospital, she was again given medicines for her cough and fever, but was not evaluated further and was discharged after a day of observation. However, Cristina became increasingly drowsy over the next several days, so her parents again returned with her to the hospital. Her clinical status quickly worsening, the staff decided to transfer her to Lima. Her father accompanied her while her mother, undergoing treatment for her own TB, stayed in Junín.

At the hospital in Lima, neurosurgeons performed an emergency operation to save Cristina's life. Her doctors determined that she had already suffered permanent brain damage, and most likely had both pulmonary TB and TB meningitis. The physicians believed that she had most likely caught TB from her mother, but, despite their many efforts, were unable to obtain any specific information about her mother's illness or treatment course from Junín to know if she had a drug-resistant

strain. As a result, Cristina began the standard treatment for drug-sensitive TB while her diagnostic tests were pending.

After a month of treatment, Cristina's clinical status still had not improved, and her medical team began to suspect DR-TB. Her laboratory tests soon confirmed that she had multidrug-resistant TB (MDR-TB). The pulmonologists immediately altered the drug regimen. In the meantime, she underwent another surgical procedure and received several medicines to prevent further brain swelling and seizures.

Unfortunately, despite aggressive treatment, Cristina's clinical course slowly progressed, and, four months later, she died of progressive brain swelling. The doctors who cared for her expressed hope that a lesson could emerge from this tragedy: that providers at every level of the health system should consider and evaluate for TB, particularly when a member of the household also has active TB. Baby Cristina presented to care multiple times before she finally received appropriate diagnostic studies and treatment. If Cristina had been diagnosed earlier, she might have survived.

The name of the child in this story has been changed to protect confidentiality.

Anna

16 years old — Karachi, Pakistan

Anna was 16 years old when she was told she had tuberculosis (TB). Her father, with whom she lived in Karachi, Pakistan, had died a few months earlier of lung disease. The family was told that it was either lung cancer or TB that had not been investigated. Anna, meanwhile, was very ill and severely malnourished.

Anna's doctors started her on first-line TB treatment. They also performed drug-susceptibility testing to see if she had DR-TB. Indeed, after two months, Anna's culture showed she was resistant to isoniazid and pyrazinimide, two of the main drugs used in first-line treatment of TB. Anna's doctors switched her treatment course accordingly.

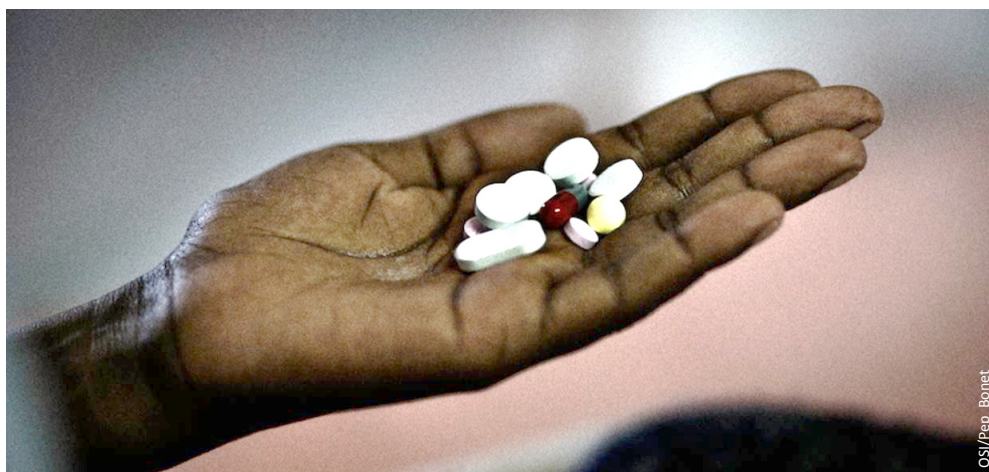Anna struggled with her DR-TB treatment. Her lungs were already

in very poor condition at the start of her treatment, requiring her to have oxygen therapy at home. She hated having to take 11 pills a day, and felt extremely nauseated whenever she ingested the toxic drugs. Anna cried out in pain every time she received the injections that were also part of her treatment.

Anna and her mother also suffered emotionally as a result of her TB and her poor prognosis, despite the help of their treatment supporter. Anna became extremely depressed. She got upset when treated like she had a fatal disease, and irritated when others were concerned that she would pass it onto them. After a month of oxygen therapy, Anna's doctor informed her that her respiratory distress was worsening, and that the end was



near. She lost all hope of getting better. Anna died soon after, leaving her mother devastated.



OSI/Pep Bonnet

Fetene

13 years old — Addis Ababa, Ethiopia

When a faith-based charity in Addis Ababa found 17-year-old Fetene, he weighed just 66 pounds. Fetene had been sick with TB since he was 13, and had already cycled through three grueling, ineffective TB treatment regimens. His parents had abandoned him, leaving him severely malnourished and isolated.

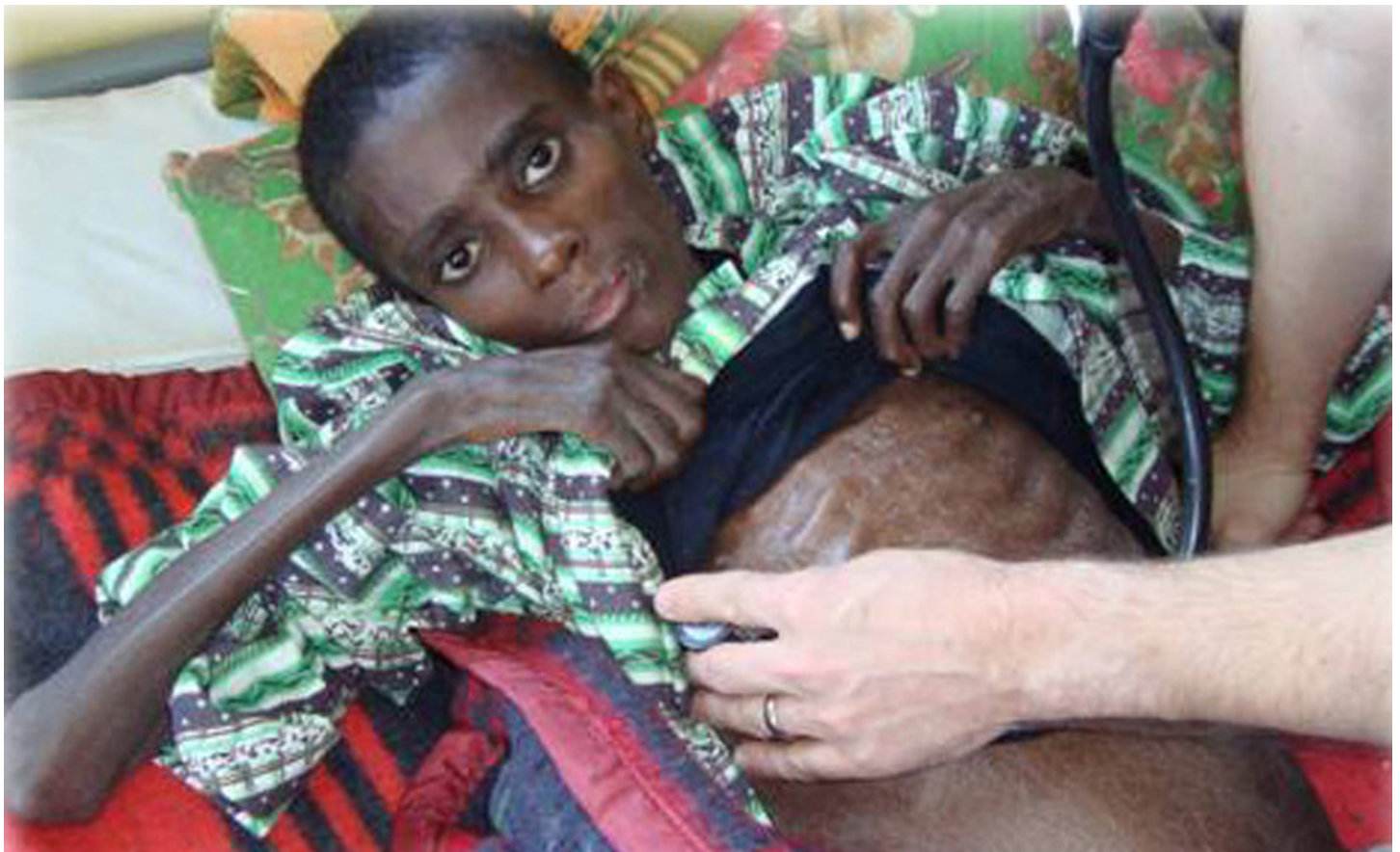Given his dire clinical status and the long course of his TB, Fetene was enrolled in a collaborative TB treatment program sponsored by the government in partnership

with a nongovernmental organization. There, doctors found that TB had ravaged not only Fetene's lungs but also his peritoneum (the membrane lining the abdominal cavity). Given these clinical symptoms and his previous, multiple treatment regimens, Fetene's doctors presumed that he had MDR-TB and enrolled him in appropriate treatment.

But by the time of Fetene's diagnosis and treatment, his lung disease was already so advanced and progressive that he developed

pneumonia. After less than two months of his MDR-TB treatment, the pneumonia led to respiratory failure, and Fetene passed away.

Fetene's untimely death illustrates many of the tragedies and injustices of pediatric drug-resistant TB. It took four years for Fetene to receive an appropriate diagnosis and treatment for his MDR-TB. In the meantime, he lost not only his health, but also his family and any other form of social support. By the time Fetene did receive a proper diagnosis and adequate care, it was too late.





Access Saves Lives

Now I am feeling a little good. I'm going to school — I like learning. When the treatment is finished in May, I'll feel happy, I'll play with my friends and I'll dance, because I'll be cured.

— Oyella Mercy, 15-year-old Ugandan girl being treated for MDR-TB

Luka, Giorgi and Maryam

7 years, 3 years, and 18 months old — Tbilisi, Georgia

“I am going to be president someday,” seven year-old Luka says proudly. He smiles an impish grin and goes back to practicing his English. His three-year old, towheaded brother Giorgi tears around the room. Their 18-month-old sister Maryam sits quietly on her mother’s lap alternately sucking on a soggy biscuit and the earpiece of a toy stethoscope. If this weren’t the highest-level referral hospital for TB treatment in Tbilisi, Georgia, you might think Luka, Giorgi, and Maryam were just everyday children playing together. A look at their pale, exhausted mother Nino might give you a clue that something terrible is wrong with these children. And then she tells you that her entire family—with the exception of

her—is undergoing treatment for extensively drug resistant tuberculosis (XDR-TB).

The children’s father lies dying from XDR-TB in a hospital room down the road. By the time he received diagnosis and treatment for his disease, it was too late. His physicians were appropriately worried about the children, though, and all three were immediately screened for TB. Unfortunately, all three children also had XDR-TB. They were quickly started on treatment with seven different medications, requiring the children to swallow more than 13 pills and receive a painful injection each day.

Yet the children are dedicated to this difficult treatment regimen.



“I drink them so well. I drink them so good,” Luka cheers when asked about his TB medicines. Giorgi chimes in “I drink good too. Me too.” In a classic case of sibling rivalry, Luka points out, “They cry with the shots. My brother and sister, they cry. But I am brave. I do not.”

As a result, they are doing well. Luka goes to tutoring classes, and all of the children are engaged in art classes as part of their holistic care. When asked about her hopes for her family, Nino says, “I have to be very brave. For my husband, really, there is no hope. He will die here and he will die soon. I am thankful my children are getting better. But I still have to be brave... For my family, it is the only way.”



Yusra

11 years old — Karachi, Pakistan



When Yusra, age 11, came to a referral hospital in Karachi, Pakistan with TB, it was hard to trace where she had contracted it. In just her immediate neighborhood at least seven people in three different households were undergoing treatment for TB. Yusra herself was already in her fourth month of TB treatment administered by a private practitioner. But Yusra's cough, fever, and weight loss were persisting. Weak and unwell, she came to the hospital.

Realizing her first-line TB treatment wasn't working, and that one of her personal contacts had been on treatment for three years, Yusra's new doctors suspected DR-TB. After the lengthy two months required to do drug susceptibility testing, Yusra's TB was found to be resistant to three first-line drugs. Her severe malnutrition also needed to be addressed, as her mother could not afford to provide adequate food.

Yusra began receiving food baskets from the hospital, and started on more effective treatment for her TB. But the cost of doing so was high, both physically and emotionally. She has trouble swallowing cycloserine, one of her new medications, and has a very difficult time receiving painful injections of other drugs. Despite the headaches, nausea, and vomiting her medications cause, Yusra nobly persists on her treatment course: "I wish I didn't have to take so many medications, they make me feel weak and nauseous, but I am finally improving after starting the right medicines. I will do anything to make them taste better and will take them responsibly."

Yusra's DR-TB diagnosis has also taxed her emotional and psychological health. Her mother describes the isolation and stigma Yusra faces: "My daughter was treated differently after the MDR-TB diagnosis was made; everyone separated her dishes and stopped inviting her [over]." While Yusra's TB is improving thanks to her perseverance and strength, her physical and psychological struggles continue.

Naleli

8 years old — Mafeteng, Lesotho

Naleli, eight years old, was orphaned by TB. Her father had been a miner in South Africa, a population heavily affected by TB, and likely was the first one in their household in rural Lesotho to fall ill. Both Naleli's parents died while on first-line TB treatment.

As if this wasn't enough hardship for Naleli to face, she herself became ill. She received a course of first-line TB treatment, despite her parents' unresponsiveness to those same medications. When doctors finally performed drug susceptibility testing for Naleli they found that she was indeed resistant to four main anti-TB drugs. She was sent to a referral clinic run by the Ministry of Health in collaboration with a nongovernmental organization. Her chest radiograph showed severe disease: the TB had affected both sides of her lungs and created a cavity.

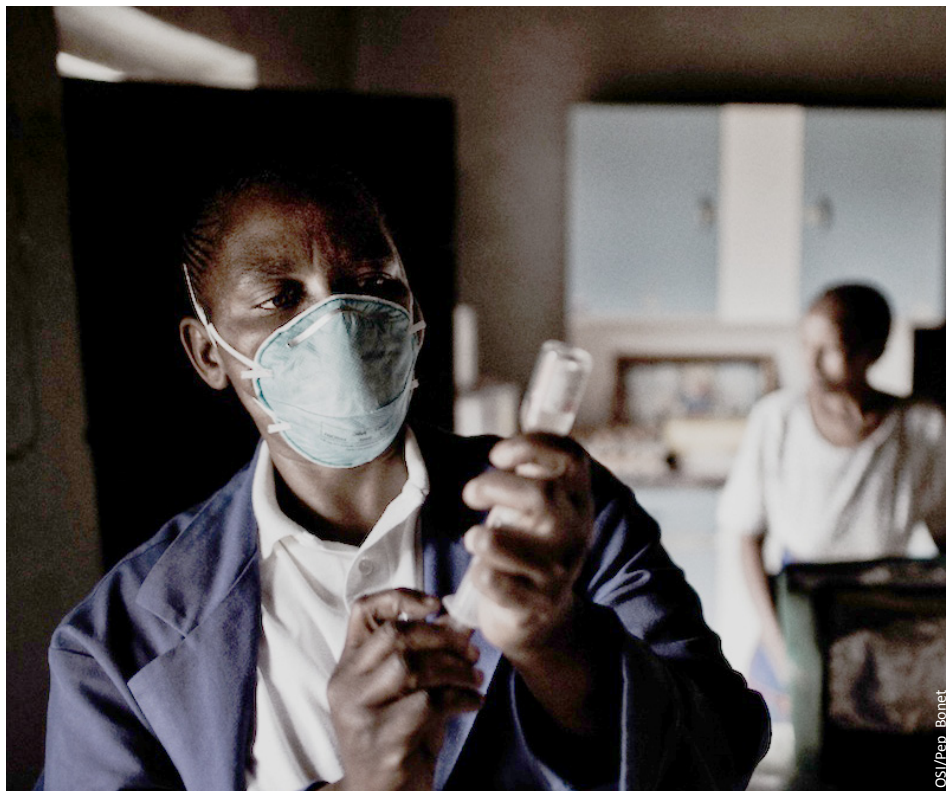Naleli started therapy for her MDR-TB, but her path was still paved with difficulties. She was also found to be infected with HIV. And because her HIV had been untreated, her CD4 cell count was extremely low (20 cells/mm³). Two weeks into her MDR-TB treatment, she started HIV treatment as well.

Naleli's HIV and TB treatment required her to take multiple medications with terrible side effects. The toxic drugs affected her liver,

her thyroid, and the potassium levels in her blood. They gave her a rash, and made her anemic. Fortunately, Naleli's health care providers monitored and managed these symptoms by giving her supplements and switching regimens when necessary.

The painful effects of Naleli's MDR-TB extended far beyond her physical health. At home, things were difficult for her. After being hospitalized for the first nine months of her treatment, Naleli, without a primary caregiver, bounced between family members' houses and an orphanage. Taunted by other students, she could not attend school.

While Naleli's 24 months of treatment ended with the successful cure of her MDR-TB, her story is far from a happy one. MDR-TB robbed her of both her parents. Her original doctors ignored this, placing her on ineffective therapy. When she finally did receive appropriate treatment for both her MDR-TB and her HIV, it ravaged her body for over two years. And she didn't just suffer physically: her schoolmates ostracized her and her family abandoned her. Though cured, it is hard to imagine that Naleli, now just 10 years old, is not forever scarred by these experiences.



The name of the child in this story has been changed to protect confidentiality.

Paki

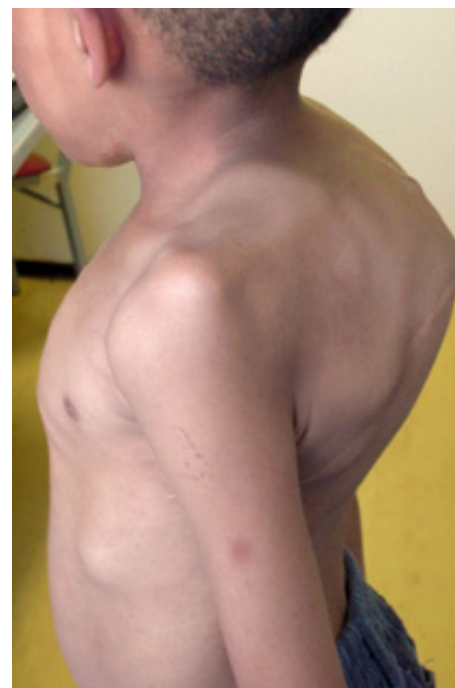5 years old — Cape Town, South Africa

In early 2008, Paki, just five years old, developed a severe deformity of his spine. He was referred to a hospital in Cape Town, where a scan revealed a large, infected abscess. Despite Paki's not having known contact with anyone with the disease, his doctors wisely suspected TB and started him on first-line anti-TB treatment. After staying in the hospital for two months, Paki could finally return home to finish his treatment.

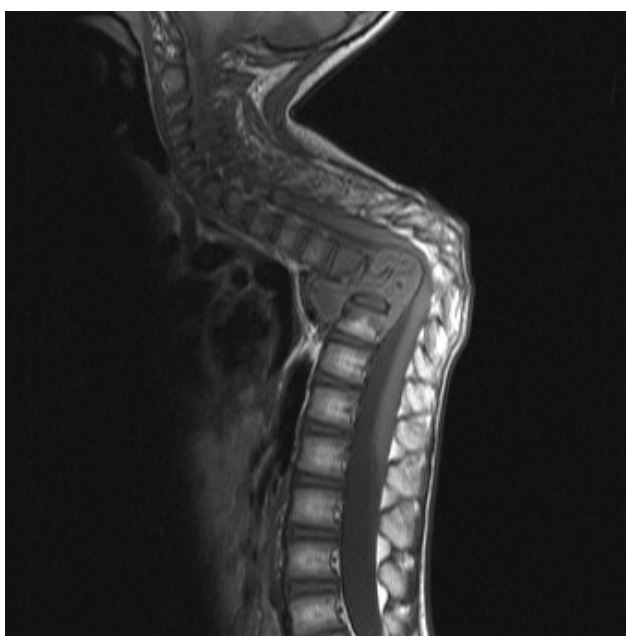
But months after Paki returned home, his spine was worsening. Returning to the hospital, he had a second scan. The abscess had worsened, and Paki's spinal deformity had become more pronounced. Again his parents said that there had been no contact with anyone with TB.

A further drug was added to his treatment, but one month later, his spine had deteriorated still further. Six-year-old Paki underwent surgery.

The surgeons removed the infected area and fused a number of the vertebrae together. The laboratory detected TB bacteria in the removed samples, but they could not perform testing for drug resistance because the bacteria wouldn't grow in the lab. Paki's doctors continued to monitor him, and after seeing his condition worsen a month later, started him on treatment for MDR-TB. Each day, Paki had to have an injection and take seven tablets. He also had to have a second operation to further decompress and straighten his spine.



After a few days, it was discovered that Paki's family member and former caregiver had been diagnosed with MDR-TB of the lung in 2008. Paki was transferred to the regional drug-resistant TB hospital, where he remained for six months, receiving daily injections. He also had to have regular blood tests to monitor the functioning of his kidneys and thyroid, as well as audiology testing to monitor his hearing (commonly damaged by second-line anti-TB drugs). Finally, Paki returned home, where he continued his grueling treatment for an additional year. Paki finished his treatment and is clinically very well, but his deformed spine bears witness to his struggle against DR-TB.



The name of the child in this story has been changed to protect confidentiality.

Sonnu

11 years old — Kandivali, India

Sonnu, 11 years old, was living in the Kandivali slums outside of Mumbai with his uncle, his older sister, and his younger brother. The siblings had sadly lost their mother a few years earlier. Sonnu had been diagnosed with HIV and been monitored since he was 10 years old by a nongovernmental health care organization. In 2007, when he was 11, he developed TB, and began taking first-line drugs. Soon after, his doctors confirmed that his strain of TB

was resistant to six drugs. They counseled Sonnu and his uncle before starting a DR-TB treatment regimen of six drugs.

However, in later adherence counseling sessions, it appeared that Sonnu's uncle had become less caring toward Sonnu and his siblings—he treated the children like servants, ordering them to cook for him and clean the house. The uncle was also trying to take the house (which was in Sonnu's

mother's name) away from them. As a result, Sonnu and his siblings stopped respecting and listening to their uncle, and this affected Sonnu's treatment adherence. He would take his tablets at home in front of his uncle, and vomit them out in the bathroom. His uncle, indifferently and irresponsibly, did not report this to Sonnu's doctors, nor did he enforce Sonnu's attendance to important medical appointments.

Sonnu's counselors worked intensively with Sonnu and his uncle, both independently and together, to address these behavioral issues. They added a directly observed therapy provider to monitor treatment. Sonnu's siblings were enrolled in boarding school so that the uncle could pay closer attention to Sonnu. After seven months of DR-TB treatment, and additional counseling, Sonnu began first-line antiretroviral therapy for HIV.

Over time, Sonnu's adherence to both the DR-TB treatment and antiretroviral therapy improved. At the age of 13, Sonnu completed his course of DR-TB treatment. After rapid improvement in his CD4 count, his HIV care was transferred to a government center, where he continued to receive treatment.

The name of the child in this story has been changed to protect confidentiality.



Molahlehi

11 years old — Maseru, Lesotho


Molahlehi was fifteen years old, and weighed just 73 pounds, when he was referred to treatment in an MDR-TB program. Having first been treated for TB when he was 11, he had already received two previous, ineffective courses of first-line anti-TB treatment. Molahlehi had lost his mother, father, and brother to TB while they were receiving the same first-line treatment.

Molahlehi's new clinicians realized that his family members had probably had MDR-TB. As such, they began Molahlehi on MDR-TB treatment immediately. Three months later, Molahlehi's culture-based drug susceptibility testing surprisingly revealed that his TB was actually still susceptible to four of the main first-line anti-TB drugs. However, these results could not be confirmed because of difficulties in obtaining further positive cultures. Because Molahlehi had such extensive damage in both lungs (including fibrosis and cavitory lesions), his

doctors continued administering second-line drugs, and added three first-line drugs.

Molahlehi suffered many adverse effects from his treatment, including vomiting; joint pain; low potassium levels in his blood; hypothyroidism; and damage to his kidneys, ears and nerves. At one point, Molahlehi's lung collapsed, and he required a chest tube. His clinicians monitored him closely and addressed these concerns as quickly as possible.

In addition to the painful and invasive procedures, and the difficulties of tolerating multiple toxic drugs, Molahlehi experienced severe depression and social isolation. It turned out that the depression was due to his hypothyroidism, and his mood improved immediately when he was started on thyroxine replacement therapy. Molahlehi's aunt had been taking care of him before his diagnosis of probable MDR-TB, but she abandoned him



when he received his diagnosis. After some discussion between his physicians and his family, the aunt eventually took him back into her care, but she made him stay outside of the house, even after he was not contagious. Molahlehi dropped out of school; he couldn't stand his classmates making fun of how thin he was.

But Molahlehi was strong, and stuck with his MDR-TB treatment for all 20 months until he was cured. With support from a nongovernmental organization, he began income-generating activities, including making and selling jerseys, rearing and selling rabbits, and gardening. Molahlehi has returned to school, and now supports his aunt and his cousins with his hard-earned income.

The name of the child in this story has been changed to protect confidentiality.



Juan

4 years old — Lima, Peru

Four-year-old Juan has captured the heart of every doctor and nurse in the tuberculosis unit in which he has been living and receiving treatment for the last six months. Despite his separation from his family and his confinement to a wheelchair, Juan has maintained both his sweet demeanor and his playfulness. Although he says only a few words, he likes to give hugs and greets everyone with a smile. The resident physicians often wheel him out to their work area, where they let him play with their stethoscopes. Juan embodies the innocence of childhood: oblivious to the severity of his own illness and to his family's tragedy, he continues to laugh and play. Nevertheless, there is little doubt that tuberculosis will leave both physical and emotional scars on this young boy.

Until six months ago, Juan lived with his family in El Agustino, the district with the highest incidence of tuberculosis in Lima. Approximately one year ago, Juan's mother first became ill with pulmonary TB. Initially, she complied with her treatment, and her health improved. However, after a few months, Juan's father left her for another woman,

and she plunged into a deep depression and stopped taking her medicines.

A couple of months later, Juan developed a progressive cough. He was diagnosed with bacterial pneumonia and treated with a course of antibiotics, which failed to cure his cough. One day while playing, Juan fell and injured his back. He was brought to a referral hospital, where doctors diagnosed him with a fractured spine. Luckily, his spinal cord had not been damaged. However, the accident left him with a prominent hump in his back, and significant pain when walking.

Testing revealed that Juan actually had both pulmonary TB and Pott's disease (TB of the spinal column)—which predisposed him to his injury. Furthermore, his TB was due to a drug-resistant strain, most likely transmitted from his mother. As a result, he was hospitalized not only for TB treatment but also to prevent further injury to his spine.

Juan's mother never visited her son in the hospital. She was too sick, and eventually died of respiratory failure as a result of her TB. Juan's grandmother, the family's sole wage earner,

visits Juan when she has time between working and caring for her disabled son. Juan's treatment has so far been successful, but he still has a long road ahead of him. After another year of treatment, he will finally be ready for spinal surgery. Thanks to the excellent medical care he is receiving at the referral hospital, Juan will likely be able to walk again without pain and fully recover his lung function. Unfortunately, modern medicine cannot heal the emotional scars that he will undoubtedly have from the loss of his mother to DR-TB.



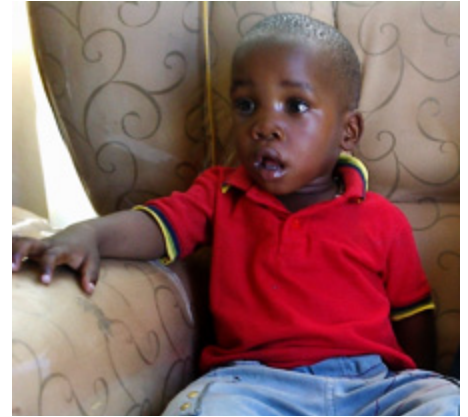Lesedi

1 year old — Cape Town, South Africa

In late 2009, Lesedi and his twin sister were born. Their mother had suffered from highly drug-resistant TB during pregnancy and tragically died soon after giving birth. Because their mother had been so ill, the twins had had no contact with her after they were born. Orphaned by TB, their aunt and grandmother cared for them.

In mid-2010, Lesedi was admitted to a hospital with a chest infection. There, after having a suspicious chest X-ray, he was found

to have a strain of TB resistant to many of the standard anti-TB drugs. He began treatment for XDR-TB. This involved six months of treatment in the hospital with second-line anti-TB drugs, both oral and injectable. He then received a further year of treatment at home. Fortunately, Lesedi's sister was well, and was given preventive therapy as an extra precaution. Currently, both Lesedi and his sister are growing and developing well, and are free of TB.



The name of the child in this story has been changed to protect confidentiality.

Oyella Mercy

15 years old — Kitgum, Uganda



Oyella Mercy is a 15-year-old schoolgirl from Kitgum, in northern Uganda. She is receiving treatment for MDR-TB in a program run by a nongovernmental organization. Oyella Mercy describes how she caught the disease: “It was transmitted from our father. He died in 2008 at the hospital. I was 13 years old when I got TB. I had stomach pains, and a cough, and I used to vomit. I went to hospital, just me myself, for one year.”

Her original treatment course failed, and in 2010 she was diagnosed with MDR-TB. She began treatment for her disease, which is now being provided within her

own home. “I started getting injections for six months. After stopping, I started taking drugs. Some drugs are difficult: I felt pain in the joints and stomach pains.”

Oyella Mercy is living in a thatched hut constructed for her by the nongovernmental organization in her family's compound. Now in the last few months of her treatment, and no longer infectious, she is well enough to have returned to school. “Now I am feeling a little good. I'm going to school—I like learning. When the treatment is finished in May, I'll feel happy, I'll play with my friends and I'll dance, because I'll be cured.”

A call to action

The stories shared in this collection are both heartbreaking and inspirational. The lives of these children—and the many thousands more they represent—demonstrate a clear need for better diagnosis and treatment for DR-TB. More accurate and more rapid diagnostics are necessary; immediate access to more tolerable and successful regimens is essential. Providing access, better tools, and support to children and their families is the only way for childhood DR-TB treatment—as well as growth and development—to truly succeed.

These children's stories reveal many challenges related to DR-TB, and highlight the next steps to be taken to ensure that no more children suffer and die from this curable disease. Scientists, clinicians, and advocates need to develop and disseminate better tools for helping children with DR-TB. Governments and funding agencies must provide the necessary support to identify and treat all children with DR-TB. Policy makers and lawmakers must ensure there is a framework to protect children affected by DR-TB. The Sentinel Project for Pediatric Drug-Resistant Tuberculosis is one forum in which this long-term, collaborative work will take place.



It always
seems
impossible
until it is done.

— Nelson Mandela,
former president of
South Africa

The road to success against childhood DR-TB will no doubt be a difficult one. Yet there are things that can be done today. A commitment to fighting the problem of DR-TB in children is urgently needed. Make that commitment, and advocate for both increased access to existing tools and for improved tools to fight pediatric DR-TB, by doing the following:

- Sign on to the Stop TB Partnership's Call to Action for Childhood TB at www.stoptb.org/getinvolved/ctb_csa.asp
- Share these children's stories with the people you know
- If you know a child affected by DR-TB, please share his or her story with us at sentinel_project@hms.harvard.edu

Individual contributors

Erica Lessem (Treatment Action Group), Javid Syed (Treatment Action Group), Alberto Colorado (Advocates for Health International and acTBistas), Mercedes Becerra (Harvard Medical School and Partners In Health), and Jennifer Furin (TB Research Unit at Case Western Reserve University) convened the contributors and edited this collection. Courtney Yuen (Harvard Medical School) designed and prepared the print layout. Kaori Ihara designed the Sentinel Project logo. Brian Bendlin edited copy. The following individuals gathered and wrote the children's stories:

When the System Fails

Thabo—Soweto, South Africa

Jennifer Furin, TB Research Unit at Case Western Reserve University

Cristina—Junín, Peru

Hernán del Castillo, National Institute of Child Health (Instituto Nacional de Salud del Niño)
Silvia Chiang, Children's Hospital Boston and Partners In Health
Leonid Lecca, Partners In Health

Anna—Karachi, Pakistan

Farhana Amanullah, Indus Hospital

Fetene—Addis Ababa, Ethiopia

Daniel Meressa, Global Health Committee, St. Peter's Hospital
Rocío Hurtado, Global Health Committee, Massachusetts General Hospital, and Harvard Medical School
Anne Goldfeld, Global Health Committee, Brigham and Women's Hospital, and Harvard Medical School
Sok Thim, Global Health Committee

Access Saves Lives

Luka, Giorgi, and Maryam—Tbilisi, Georgia

Jennifer Furin, TB Research Unit at Case Western Reserve University
Medea Gegia, National Center for Tuberculosis and Lung Disease

Yousra—Karachi, Pakistan

Farhana Amanullah, Indus Hospital

Lesedi—Cape Town, South Africa

Simon Schaaf, Desmond Tutu TB Centre
James Seddon, Desmond Tutu TB Centre

Naleli—Mafeteng, Lesotho

Megan McLaughlin, Partners In Health
Hind Satti, Partners In Health
KJ Seung, Partners In Health

Paki—Cape Town, South Africa

Simon Schaaf, Desmond Tutu TB Centre
James Seddon, Desmond Tutu TB Centre

Sonnu—Kandivali, India

Médecins Sans Frontières staff

Molahlehi—Maseru, Lesotho

Megan McLaughlin, Partners In Health
Hind Satti, Partners In Health
KJ Seung, Partners In Health

Juan—Lima, Peru

Hernán del Castillo, Instituto Nacional de Salud del Niño
Silvia Chiang, Children's Hospital Boston and Partners In Health
Leonid Lecca, Partners In Health
Photo credit: Otsuka Pharmaceuticals/Riccardo Venturi

Oyela Mercy—Kitgum, Uganda

Natasha Lewer, Médecins Sans Frontières
Andrea Stultiens, freelancer

Contributing organizations

The following organizations contributed stories for this collection. For more information about their work on behalf of children with tuberculosis, please see the websites below.

Treatment Action Group

www.treatmentactiongroup.org/tb

Advocates for Health International/AcTBistas

www.facebook.com/acTBistas

Desmond Tutu TB Centre, South Africa

www.sun.ac.za/tb

Global Health Committee

www.globalhealthcommittee.org

Indus Hospital, Pakistan

www.indushospital.org.pk

Médecins Sans Frontières

www.msf.org

National Institute of Child Health, Peru

www.isn.gob.pe

Partners In Health

www.pih.org

TB Research Unit at Case Western Reserve University

www.cwru.edu/affil/tbru/



OSI/Pep Bonet

The Sentinel Project on Pediatric Drug-Resistant Tuberculosis

c/o the Department of Global Health and Social Medicine
Harvard Medical School
641 Huntington Avenue
Boston, MA 02115
USA

www.sentinel-project.org

