



WE CAN HEAL

PREVENTION, DIAGNOSIS, TREATMENT, CARE, AND SUPPORT:
ADDRESSING DRUG-RESISTANT TUBERCULOSIS IN CHILDREN

MARCH 2013



TAG
Treatment Action Group

THE SENTINEL PROJECT ON PEDIATRIC DRUG-RESISTANT TUBERCULOSIS

Every year, thousands of children die from drug-resistant tuberculosis (DR-TB)—a disease with a known cure. This happens because children often do not have access to effective diagnosis or treatment.

In spite of global advances made against tuberculosis (TB), children have been left behind. The Sentinel Project on Pediatric Drug-Resistant Tuberculosis is a global partnership of more than 250 researchers, caregivers, and advocates from more than 50 countries who share a vision of a world where no child dies from this curable disease. Since October 2011, network members have been collaborating to raise the visibility of this vulnerable population of children, and to share evidence and resources that can increase children's access to prompt and effective treatment. Toward this end, task forces have begun working on joint projects, such as developing a practical field handbook to guide treatment, and compiling this collection of stories.

TREATMENT ACTION GROUP

Treatment Action Group (TAG) is an independent AIDS research and policy think tank fighting for better treatment, a vaccine, and a cure for AIDS. TAG works to ensure that all people with HIV receive lifesaving treatment, care, and information. We are science-based activists working to expand and accelerate vital research and effective community engagement with research and policy institutions. TAG catalyzes open collective action on the part of all affected communities, scientists, and policy makers to end AIDS.

ACKNOWLEDGMENTS

In addition to the contributors listed for each story, the following individuals formed the team that completed this March 2013 collection. Lindsay McKenna (Treatment Action Group) led the collection of stories and wrote the copy, with extensive support from Vanessa Van Doren (Harvard Medical School), Arielle Tolman (Harvard Medical School), Erica Lessem (Treatment Action Group), Colleen Daniels (Treatment Action Group), Jennifer Furin

(TB Research Unit at Case Western Reserve University), and Mercedes Becerra (Harvard Medical School and Partners In Health). In addition, Grania Brigden (Médecins Sans Frontières) and Alberto Colorado (Advocates for Health International and acTBistas) assisted in convening the contributors and in editing this collection. This team also revised and expanded the story collection framework, including the questionnaire and consent form, which we used to compile the first group of stories compiled in March 2012. Tara Banani (Harvard School of Public Health) translated the framework into French; Norma Gutierrez (Cleveland Clinic) translated the framework into Spanish; and Anna Bondar (University of Pittsburgh) translated the framework into Russian and the Russian story submissions into English. Andrea Benzacar (Treatment Action Group) edited the collection. Kaori Ihara designed the Sentinel Project logo.

DEDICATION

This collection is dedicated to children all over the world who have been affected by DR-TB, and to the providers and caretakers who have worked to provide effective services and give them support.

CONTACT

The Sentinel Project on Pediatric Drug-Resistant Tuberculosis
c/o The Department of Global Health and Social Medicine
Harvard Medical School
641 Huntington Avenue
Boston, MA 02115 USA
sentinel_project@hms.harvard.edu
www.sentinel-project.org

Treatment Action Group
261 Fifth Avenue, Suite 2110
New York, NY 10016
tag@treatmentactiongroup.org
www.treatmentactiongroup.org

© 2013 by Treatment Action Group

May be copied with attribution for noncommercial use



TAG
Treatment Action Group

WE CAN HEAL

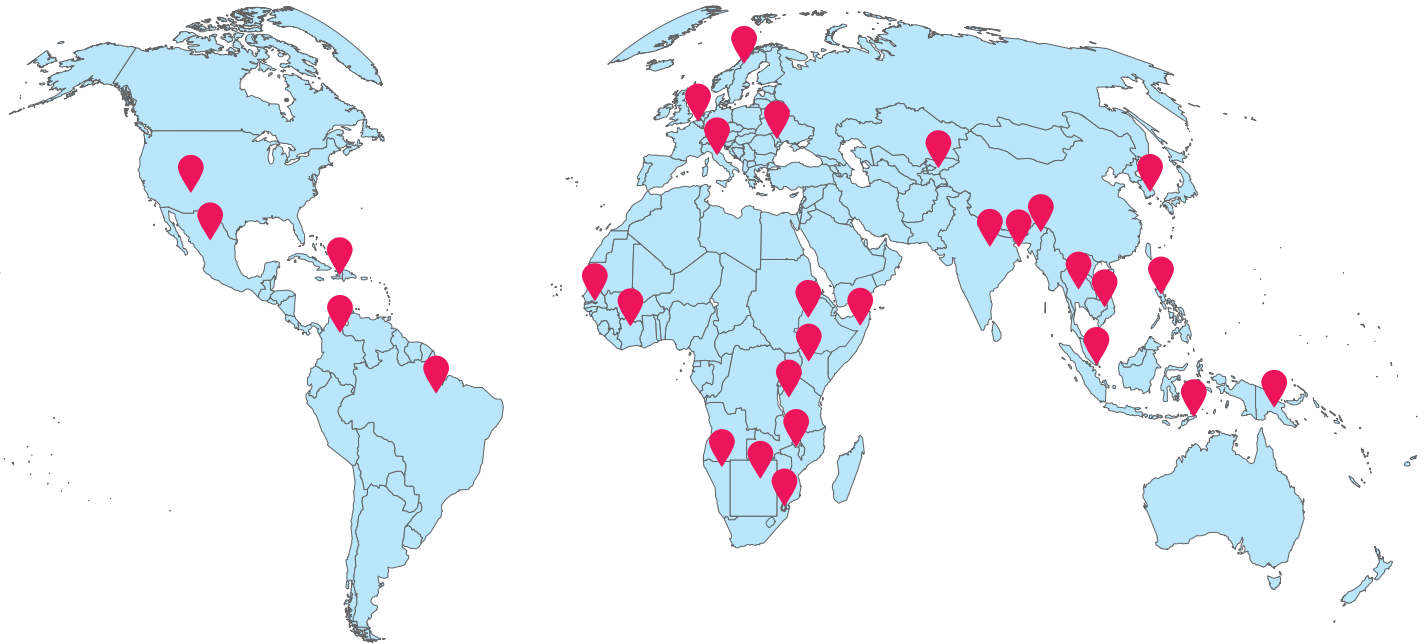**PREVENTION, DIAGNOSIS, TREATMENT, CARE, AND SUPPORT:
ADDRESSING DRUG-RESISTANT TUBERCULOSIS IN CHILDREN**

MARCH 2013

TABLE OF CONTENTS

EXECUTIVE SUMMARY	1
INTRODUCTION	3
PREVENTION	5
Ikram - Tanzania	5
Tanya - Moldova	7
Semmi - South Korea	7
Greg - United States of America	8
Endalemaw - Ethiopia	9
<i>Prevention Recommendations</i>	10
DIAGNOSIS	11
Mala - Bangladesh	11
Lebogang - Botswana	12
Olesya - Italy	13
Hamid - Kyrgyzstan	13
Simon - Namibia	14
Duba - Papua New Guinea	15
JB - Philippines	16
Malick - Senegal	16
Nyein - Singapore	17
Nqobile - Swaziland	18
Jane - Sweden	19
Jose - Timor-Leste	19
<i>Diagnosis Recommendations</i>	20
TREATMENT, CARE, AND SUPPORT	21
Menkhu - Nepal	22
Mustkeen - India	23
Jomo - Kenya	23
Phu - Southeast Asia	24
Adam - Belgium	25
Fanny - Malawi	25
Ploy - Thailand	26
Alessandra - Brazil	27
Sofia - Colombia	27
Edwige - Côte d'Ivoire	29
Cordaro - Mexico	29
Ismael - Somalia	30
Marie - Haiti	30
<i>Treatment, Care, and Support Recommendations</i>	32
CONCLUSIONS	34
RESOURCES	35

LOCATION OF STORIES OF CHILDREN WITH DRUG-RESISTANT TB, MARCH 2013



EXECUTIVE SUMMARY

This collection of 30 stories from 30 countries identifies what the TB community needs to achieve zero TB deaths, new infections, and suffering—a target recently called for by more than 500 individuals and organizations.¹ Addressing the gaps in prevention, diagnosis, treatment, care, and support that this report outlines will bring us closer to realizing zero child deaths from drug-resistant tuberculosis (DR-TB), a preventable and curable disease.

To **prevent** new childhood DR-TB infections we need

- a more effective vaccine to prevent all forms of TB and provide lasting immunity;
- development and delivery of preventive therapy (with child-friendly formulations) for individuals exposed to patients with DR-TB;
- improved infection control in TB clinics and hospitals; and
- community education about how to prevent TB transmission.

To more effectively **diagnose** childhood DR-TB we need

- application of a family-centered approach to screening for TB that includes screening of all child contacts of patients with drug-resistant TB;
- improved referral systems and follow-up for child contacts;
- improved training for clinicians and community health workers to detect TB in children;
- improved clinical evaluation guidelines;
- better tests to detect TB and drug resistance in children, specifically point-of-care tests that are rapid and do not rely on sputum specimens; and
- streamlined communication strategies between diagnostic labs and health care providers and patients.

To improve **treatment** for children with DR-TB we need

- implementation of a patient-centered approach to care that provides comprehensive services (pain management, hearing tests [audiometry], nutritional support, and travel allowances) and psychosocial support to children with drug-resistant TB and their families;
- delivery of DR-TB treatment regimens for children that promise the best chance of cure, including the use of empirical regimens in patients without bacteriologic confirmation or who are awaiting DST results;
- integration of care with other health programs, including migrant services, HIV services, and existing child health programs;
- child-friendly formulations of TB drugs that have a low pill burden, are easier to ingest, taste better, and do not require injections;
- faster-acting, more tolerable drugs with fewer side effects; and
- a steady and reliable supply of TB drugs.

1. Treatment Action Group. The zero declaration [Internet]. 2012 July 22 (cited 2013 February 2012). Available from: <http://www.treatmentactiongroup.org/tb/advocacy/zero-declaration>. (Accessed 2013 February 12)

INTRODUCTION

TB in a child is considered a sentinel health event as it signals recent transmission of tuberculosis (TB), which is preventable and curable. A child infected with TB is likely to progress to disease and death more rapidly than an adult. Drug-resistant forms of TB are also curable in children if they are found and treated promptly and correctly. However, because a diagnosis of drug-resistant TB (DR-TB) requires isolating the TB bacteria—something that is often difficult to do in children—it is a challenge to obtain a diagnosis even in a child that is very sick. As a result, little information is available about the extent of the problem of pediatric DR-TB across the globe.

Children with DR-TB around the world require urgent attention because they point to the unrelenting spread of the TB epidemic itself: each child case is a warning signal that transmission of DR-TB strains is ongoing in that child's community. At the same time, the experiences of children with DR-TB shed light on what needs to be done to achieve zero TB deaths from this curable disease. The Zero TB Deaths, New Infections and Suffering Campaign calls on the global TB community to reject unambitious targets and demand global action and a new global attitude in the fight against TB.²

This collection of stories illustrates the problems we face with DR-TB in children. We reached out to colleagues around the world who submitted stories of children with drug-resistant TB. Our first collection in March 2012 compiled the stories of 15 children in 8 countries. Here we present an updated collection that contains the stories of 30 children from 30 countries. These stories reveal the widespread problems of prevention, diagnosis, and treatment of DR-TB. They also bear witness to the courage of the children who fight for their lives against DR-TB, and to the crucial roles of family members and care providers who fight alongside them. Finally, these stories speak pointedly to the gaps in programs and policies that are failing children with TB around the world.

The voices of children like that of Sofia from Colombia—who tells us “we can heal”—should give us optimism that with more attention and better tools, we can achieve zero child deaths from all forms of TB.

2. Treatment Action Group. The zero declaration [Internet]. 2012 July 22 (cited 2013 February 2012). Available from: <http://www.treatmentactiongroup.org/tb/advocacy/zero-declaration>. (Accessed 2013 February 12)



PREVENTION

The existing bacille Calmette-Guérin (BCG) vaccine does not prevent all cases of tuberculosis (TB) in children, and its protective effects do not last beyond adolescence. A large majority of children who are known contacts of active drug-resistant tuberculosis (DR-TB) patients are not evaluated for TB infection. Moreover, there is no established effective preventive therapy to prevent people exposed to DR-TB from developing active disease—by definition, DR-TB cases are resistant to the main drugs normally used to preventively treat TB infection. Each year, thousands of children die of DR-TB as a result of these failures.

A family-centered approach to screening for TB would place children at the center of care and ensure the complete investigation of DR-TB patient contacts to prevent the spread of DR-TB among family members. The prevention section of this collection offers stories of children whose DR-TB infection, suffering, and in one case death could have been prevented. These stories underscore areas for improvement in the prevention of pediatric DR-TB.

IKRAM (2 YEARS OLD) TANZANIA

Ikram and his mother live with his grandmother. His parents are divorced and his father does not provide the family with any support. Ikram's grandmother supports his mother and eight other family members by selling gravel and stone. She collects larger stones and crushes them by hand using a hammer to produce the gravel. Seven tons of gravel sells for Tanzanian shillings 40,000 (US\$26). The family of 10 survives on this meager amount.

In 2009, Ikram's mother was diagnosed with pulmonary TB (TB of the lungs). She was pregnant at the time, but completed treatment. She gave birth, but the child died of unknown causes two months later. In 2010, when she was again pregnant, this time with Ikram, she was diagnosed with TB for a second time. She completed treatment and was declared cured; a culture was sent for drug susceptibility testing (DST). In the meantime, Ikram was born a healthy baby and immunized with BCG. When Ikram's mother's culture results came back, they were positive, but at the time she felt she was in good health.



Ikram (2 years old) - Tanzania

In May 2011, after counseling and close follow-up, Ikram's mother agreed to be referred to the national TB hospital, but finding someone to care for baby Ikram posed a challenge. The district welfare system was weak, and Ikram's mother was scared she would lose her baby. She decided to keep Ikram with her at the hospital while she received DR-TB treatment.

Ikram's mother was told that her baby was receiving treatment to prevent TB, but in July 2011 Ikram developed a cough and a fever. Ikram, just a baby, was unable to cough up phlegm to test for TB. A gastric lavage (an uncomfortable procedure where a tube is inserted through the nose or mouth) was used to obtain a culture for testing. The culture results and chest X-ray suggested that Ikram had TB. When the DST results showed resistance to isoniazid, rifampicin, and ethambutol, a DR-TB expert panel started Ikram on DR-TB treatment.

In early December 2011, the national TB hospital ran out of second-line drugs. Ikram and his mother stopped treatment and returned home. During his treatment interruption, Ikram began to lose weight, refused to eat, and developed a fever that would not respond to paracetamol (acetaminophen). Not only was Ikram growing weak, but his mother's condition also began to deteriorate. In late January 2012, Ikram and his mother returned to the hospital and began their DR-TB treatment regimens again.

Once they were thought to no longer be infectious, Ikram and his mother were discharged from the hospital to complete treatment. Ikram's mother picks his medications up from a facility five kilometers (three miles) from their home. Ikram's treatment relies on adult formulations, with his doses based on his body weight. His mother must crush the drugs and prepare them with juice to conceal their bitter taste and keep Ikram from spitting them out or vomiting.

Ikram is scheduled to complete treatment in February 2013. Ikram is doing well on treatment, but is experiencing slight bending in his lower limbs, a result of treatment with fluoroquinolones. Ikram and his mother are also experiencing stigma. The community knows that Ikram and his mother are being treated for TB, and assume they are coinfecting with HIV. As Ikram's mother says, "my child likes to play with other children in our community, but some parents don't like that and they chase my child away from theirs."

SUBMITTED BY:

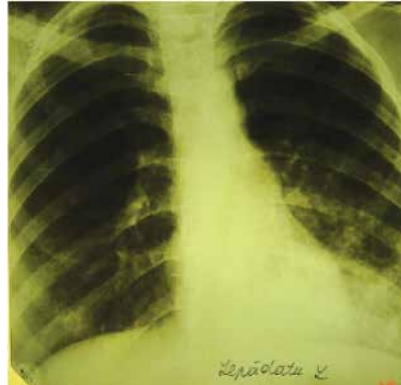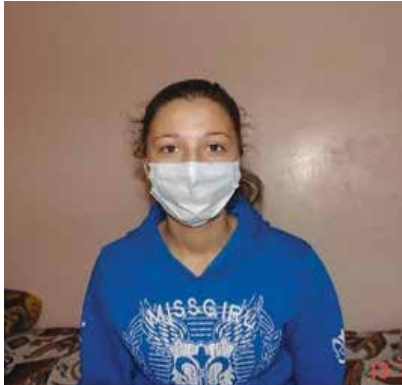Kibongoto National Tuberculosis Hospital, Tanzania

PATH, Tanzania

**Rose Olotu, MD, Technical Officer,
TB/HIV Project, PATH, Tanzania**

**John Minde, District TB and Leprosy Coordinator,
National TB and Leprosy Program, Tanzania**

**Amina Ngombo, District TB/HIV Coordinator,
TB/HIV Project, PATH, Tanzania**



Tanya (14 years old) - Moldova

TANYA* (14 YEARS OLD) MOLDOVA

Tanya began feeling sick in June 2012. Relatives from Moscow, previously diagnosed with TB, had recently visited Tanya and her family in Moldova. A month later she was diagnosed with TB. In August 2012, one month after being diagnosed with TB, Tanya's doctor performed drug susceptibility testing. The results showed that Tanya's strain of TB was resistant to isoniazid, rifampicin, ethambutol, and streptomycin.

By September 2012, Tanya had started receiving treatment with second-line drugs. The treatment placed a significant financial burden on Tanya's family.

Once on second-line drugs, Tanya's liver began to show signs of failure. She was quickly taken off of pyrazinamide and put on para-aminosalicylic acid (PAS), and her liver function recovered.

Throughout the course of her treatment, Tanya's doctor stressed the importance of adhering to treatment by ensuring that Tanya "[understood] her role in completing the treatment."

**The name of the child in this story has been changed to protect confidentiality.*

SUBMITTED BY:

Stela Kulcitki, Instituia Medico-Sanitară Publică (IMSP), Spitalul Clinic Municipal de Ftziopneumologie (SCMF), Moldova

SEMMI* (8 YEARS OLD) SOUTH KOREA

Semmi's father had been on irregular TB treatment for years, but Semmi's battle with TB began in 1996. At eight years old, Semmi tested positive for TB infection. Semmi likely acquired this latent infection from her father. She received preventive therapy with the first-line drug isoniazid to stop the infection from progressing to active disease, but was given isoniazid for only four months (rather than the recommended nine months of treatment).

Semmi's family's struggle with TB did not end then. In 1998, when Semmi was 10 years old, her mother was diagnosed with MDR-TB and her brother was diagnosed with drug-sensitive TB (DS-TB). Eventually, Semmi's mother and brother were cured of TB, but her father unfortunately died of XDR-TB.

In 2001, Semmi was 13 years old and experiencing symptoms of illness. In March, she was diagnosed with TB and began treatment with isoniazid, rifampicin, ethambutol, and pyrazinamide. After three months of treatment, Semmi's chest X-rays did not improve, and her doctors switched her to a regimen of second-line drugs to treat what they suspected was DR-TB. Semmi kept up with her second-line therapy for eight months. In February 2002, she began having trouble taking her treatment regularly and stopped treatment altogether.

Two years later, in May 2004, Semmi returned to her doctor in poor condition. Her chest X-rays showed cavitory lesions in the lungs (or holes where TB had destroyed the lung tissue). Semmi's doctor reinitiated her on second-line treatment, but Semmi had problems taking her medications, which resulted in several interruptions in her treatment.

Finally, in June 2005, Semmi's doctor performed DST. A month later, the results showed her strain of TB was resistant to nearly all TB drugs: isoniazid, rifampicin, ethambutol, kanamycin, capreomycin, PAS, ofloxacin, moxifloxacin, and rifabutin. Semmi had extensively drug-resistant tuberculosis (XDR-TB).

In January 2007, Semmi had surgery to remove the cavitory lesions from her lungs. In September 2011, Semmi's doctor initiated her on a new regimen including linezolid. At first, Semmi showed signs of improvement; however, Semmi became anemic, and her doctors had to lower the dose of her TB medications. In summer 2012, after spending 16 years fighting TB, Semmi died of chronic XDR-TB.

**The name of the child in this story has been changed to protect confidentiality.*

SUBMITTED BY:

Myungsun Lee, MD, International Tuberculosis Research Center (ITRC), South Korea

GREG* (2 YEARS OLD) UNITED STATES OF AMERICA

Greg was diagnosed with TB meningitis in April 2011 in El Paso, Texas. Greg was put on a standard four-drug regimen consisting of rifampicin, isoniazid, pyrazinamide, and ethambutol. After conducting a contact investigation, Greg's doctors discovered that his father had undiagnosed pulmonary TB. DST further revealed that Greg's father had MDR-TB. Greg's father, originally from Vietnam, knew that he had tested positive with tuberculin skin tests in the past, but never received

any diagnosis or treatment for active TB. Greg's father had been working in a nail salon at a large mall in El Paso; it is unknown if others were infected.

Following the contact investigation in May 2011, Greg was diagnosed with MDR-TB. DST revealed Greg's strain of TB was resistant to isoniazid, rifampicin, and ethambutol, three of the four drugs he was being treated with, as well as to streptomycin. He was admitted to the hospital and started on second-line TB therapy consisting of amikacin, levofloxacin, cycloserine, and pyrazinamide.

Greg remained in isolation for the first six weeks of treatment. His mother felt an overbearing sense of loneliness and depression while her one-year-old son was in isolation at the hospital for six weeks. While tending to Greg at the hospital she was separated from her daughter, adding to her depression. Toward the end of the six weeks of isolation, Greg's health had improved, and his mother struggled to cope with his increased energy and activity in such a small space. Greg was doing well on treatment, but after several months, he began to experience hearing loss, likely an effect of treatment with amikacin. Greg's doctors replaced amikacin with linezolid. Greg has now completed 21 months of therapy and is doing well. Unfortunately, Greg still has to wear hearing aids. Thankfully, he appears to be catching up to where he should be developmentally.

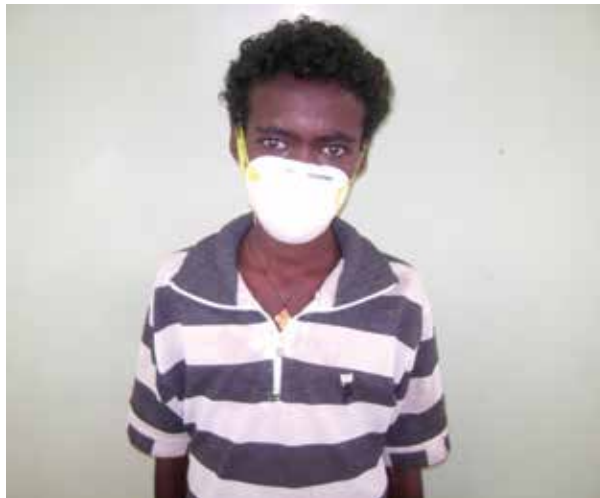As Greg's mother reflects on his treatment experience, she tells stories of the difficulties she faced getting him to take pills designed for adults. Greg's doctor expressed his admiration for parents who are able to get their children through TB therapy: "In many ways, it is more difficult that cancer chemotherapy because, even with DOT [direct observation of therapy by staff], the onus is on the parents to administer all of the medication." Greg's mother also struggled to work with the local health department, where over the course of Greg's treatment, there was regular turnover of staff. Greg's mother felt she knew

more about TB and TB treatment than the health department workers did. Greg's mother faced stigma and described subtle discrimination by the community, which added to her sense of isolation. Unfortunately, Greg's parents divorced during his treatment. There is no doubt that the stress TB placed on Greg's family contributed to the demise of his parents' relationship.

**The name of the child in this story has been changed to protect confidentiality.*

SUBMITTED BY:

**Jeffrey R. Starke, MD, Baylor College of Medicine,
Texas Children's Hospital, United States of America**



Endalemaw (15 years old) - Ethiopia

ENDALEM AW (15 YEARS OLD) ETHIOPIA

Endalemaw is from a poor district of northern Ethiopia, where his parents are farmers. He shares a single room with 10 family members. Endalemaw's 17-year-old sister was diagnosed with active TB by the local health clin-

ic, and had been on treatment for five months with little sign of improvement. Endalemaw's sister eventually received DST and was found to have MDR-TB. Endalemaw helped care for his older sister both at home and in the hospital while she was receiving treatment, but neither of them wore any type of protective mask.

In early March 2012, Endalemaw developed a fever and abdominal pain. He was treated at the local health clinic before he was referred to a local hospital. At the hospital he was told that he had schistosomiasis, an intestinal parasite.

Three months later, in June 2012, Endalemaw went to the hospital where his sister's MDR-TB was diagnosed because he was experiencing fever, weight loss, excessive sweating, abdominal pain, cough, quickened breathing, and weakness. Endalemaw was diagnosed with TB, but after his doctors took a detailed family history and learned of his sister's condition, they quickly changed his diagnosis to MDR-TB and admitted him to the hospital's MDR-TB ward. Endalemaw's doctor initiated treatment for MDR-TB a few days later, without confirmed DST. Five months into treatment, Endalemaw is improving, with no signs of hearing loss or depression. While Endalemaw's actual treatment for TB was free, he lives far from the hospital. Both Endalemaw and his family could have benefited from financial support for costs incurred traveling to and from the hospital.

SUBMITTED BY:

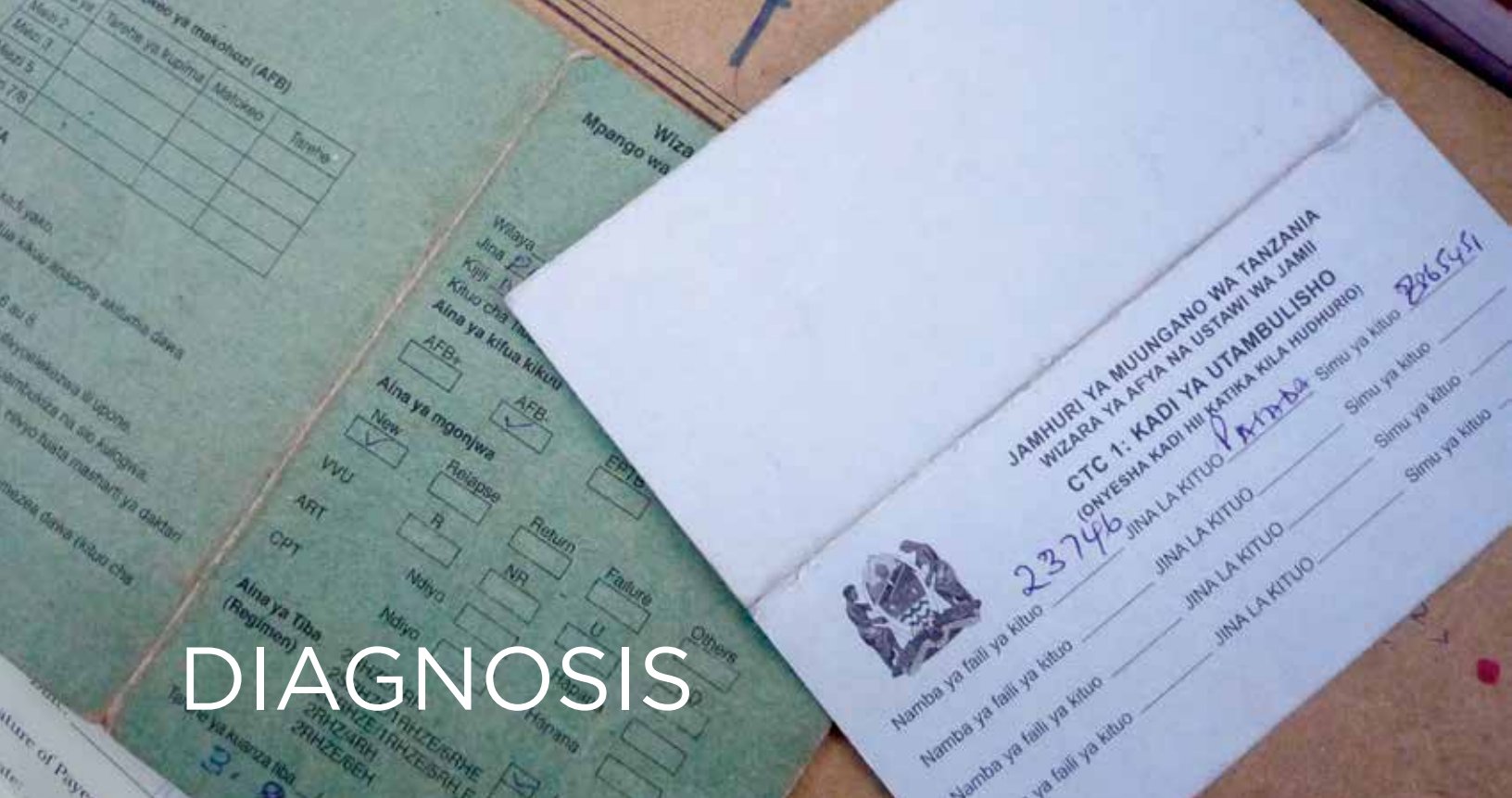
**Bekana Kebede, BSc, MPH, University of Gondar,
Ethiopia**

Gondar University Referral Hospital, Ethiopia

RECOMMENDATIONS

A more effective vaccine that provides lasting immunity, and treatment to prevent TB infection from developing into active disease, are urgently needed. However, in the absence of such a vaccine or preventive therapy, it is essential to prevent the spread of TB using the best knowledge of how to prevent infections. In sum, we need

- a more effective vaccine to prevent all forms of TB and provide lasting immunity;
- development and delivery of preventive therapy (with child-friendly formulations) for individuals exposed to patients with DR-TB;
- improved infection control in TB clinics and hospitals; and
- community education about how to prevent TB transmission.



DIAGNOSIS

Diagnosis of tuberculosis (TB) in children remains an enormous challenge. Children can progress quickly from infection to disease to severe disease, meaning there is not a large window of time for diagnosis to occur, as there often is with adults, whose infection and disease tend to progress more slowly. Another major barrier to diagnosis is the lack of diagnostic tools that specifically address the needs of children. Microscopy, the mainstay of TB diagnosis, as well as culture and new rapid tests including GeneXpert, are based on sputum samples. Sputum, or phlegm, is difficult to obtain in children. Though there are techniques such as gastric aspiration and sputum induction to gather samples, they require trained specialists and equipment, and are invasive and uncomfortable for the patient. Children with TB tend to have fewer bacteria than adults, which means tests often cannot detect their TB. Children are also more likely to have TB outside of their lungs, in which case their sputum may not even contain bacteria.

A third obstacle is that existing tests are not accessible in many low-resource settings. The unavailability of DST in many settings makes

DR-TB diagnosis in children even more challenging. Even when DST is available, there are long delays in obtaining the results and difficulties transferring the results back to those treating the child.

The pain and suffering that children experience while waiting for a diagnosis are unacceptable. The diagnosis section of this collection offers stories that highlight how children with DR-TB are affected by long delays in diagnosis and in the start of appropriate treatment.

MALA* (16 YEARS OLD) BANGLADESH

Mala grew up in a slum in Bangladesh where MDR-TB is endemic. In March 2006, Mala first began to show signs of illness, but she was not diagnosed with TB until June 2007, more than a year later. Another year and seven months after being diagnosed, Mala received DST. Her strain of tuberculosis was resistant to three of the four most commonly used first-line drugs—ethambutol, rifampicin,

and isoniazid, as well as streptomycin, another drug often used to treat TB. Bangladesh's national MDR-TB treatment guidelines require hospitalization until four cultures come back negative for TB. However, when Mala was diagnosed with MDR-TB, the hospital was overcrowded and she had to wait three weeks to be admitted and begin treatment. Despite this delay in treatment, Mala was eventually cured of TB. Even though Mala is cured of TB, she still must deal with other hardships that come with poverty. Mala's doctor wishes that rehabilitation programs existed in Bangladesh so patients like Mala could receive financial and nutritional support during treatment. Mala's doctor also would like to see patients receive vocational training so that when they do get better, they can lift themselves out of poverty.

**The name of the child in this story has been changed to protect confidentiality.*

SUBMITTED BY:

Asif Mujtaba Mahmud, Respiratory Medicine, National Institute of Diseases of the Chest and Hospital, Dhaka, Bangladesh

Nazmul Hossain, MD, Medical Officer, National Institute of Diseases of the Chest and Hospital, Dhaka, Bangladesh

Ali Hossain, MD, Respiratory Medicine, National Institute of Diseases of the Chest and Hospital, Dhaka, Bangladesh

Rashidul Hassan, Respiratory Medicine, National Institute of Diseases of the Chest and Hospital, Dhaka, Bangladesh

LEBOGANG* (3 YEARS OLD) BOTSWANA

By the age of just two years old, Lebogang, a child from a small village in Botswana, had already been through more than most people experience in a lifetime. Lebogang is HIV-positive and has been on treatment since his first year of life. In early 2010, Lebogang's mother was diagnosed with TB.

A few months after his mother got sick with TB, Lebogang too began experiencing symptoms of illness; he lost weight and suffered from a severe cough. A few months later, his doctor diagnosed him with TB without any culture confirmation. In March 2010, Lebogang started taking first-line TB medicines, and during this same time, unfortunately, lost his mother to TB.

After eight months of treatment, the recently orphaned Lebogang appeared to be getting better. In November 2010, after less than a month's reprieve from his own battle with TB, Lebogang's symptoms returned. This time, Lebogang also had symptoms of central nervous system disease, including abscesses on his brain. Lebogang's doctor did not think this resurgence of symptoms could be caused by TB as Lebogang had already completed treatment with first-line drugs. Despite Lebogang's symptoms and his mother's poor outcome from TB, his doctor did not consider drug-resistant TB. Instead, he considered other diagnoses such as toxoplasmosis, a parasitic disease.

Finally, in late 2010, a TB culture was done for Lebogang and a positive TB result was produced in January 2011. Lebogang was not put onto appropriate therapy until February of 2011—nearly a full year after his initial diagnosis of TB. In addition to the failure of his doctor to provide a timely diagnosis, this delay was in part due to the lengthy time required for DST—which showed resistance to several first-line drugs including isoniazid, rifapentine, streptomycin, and ethambutol. Appropriate treatment was further delayed as a result of difficulties in finding a caregiver for Lebogang who could commit to directly observing his daily treatments. Eventually, the clinic agreed to administer treatment at Lebogang's home. An aunt put her studies on hold in order to care for her orphaned nephew, at the cost of her own education and potential for future increased income generation.

By the time Lebogang accessed appropriate treatment, his brain lesions were extensive. A painful brain abscess biopsy confirmed that he had DR-TB of the central nervous system. Lebogang initially responded to his treatment, but it was too late—because of the extensive damage already done to his central nervous system, he passed away in July 2011. Just three years old, Lebogang spent half of his life fighting a losing battle against drug-resistant TB.

**The name of the child in this story has been changed to protect confidentiality.*

SUBMITTED BY:

Tonya Arscott-Mills, MD, Botswana-UPenn Partnership, Gaborone, Botswana

OLESYA (10 YEARS OLD) ITALY

Both of 10-year-old Olesya's parents were being treated for TB. Olesya lived in Ukraine with her father, who was on first-line therapy for DS-TB. Her mother was living in Italy, where she was being treated for MDR-TB with second-line drugs. Unsurprisingly, in August 2007, Olesya fell ill. Shortly after, in September 2007, Olesya was diagnosed with TB.

Olesya was on her fifth month of first-line therapy when her mother made a dangerous voyage across the border and snuck her back into Italy. Olesya's mother's doctor evaluated her for TB, but her tests came back negative. She was discharged and instructed to complete her remaining six months of first-line therapy.

In June 2008, one month after she was discharged from the hospital in Italy, and nine months after her initial diagnosis with TB in Ukraine, Olesya's cultures came back positive for MDR-TB. DST found Olesya's strain of TB resistant to streptomycin, isoniazid, rifampicin, ethambutol, pyrazinamide, cycloserine, ethionamide, PAS, and kanamycin.

Olesya's doctor in Italy put her on a regimen of the second-line drugs amikacin, moxifloxacin, ethionamide, and linezolid.

A few months later, in September 2008, Olesya was hospitalized for peripheral neuropathy (nerve damage), inflammation of the tongue, and abdominal pain. While in the hospital, her doctor switched her to a more tolerable regimen of linezolid, amoxicillin, moxifloxacin, and clofazimine. After 19 months of treatment, Olesya was cured of MDR-TB.

SUBMITTED BY:

Luigi R. Codecasa, MD, Regional TB Reference Centre, Villa Marelli Institute, Niguarda Hospital-Milano, Italy

Maurizio Ferrarese, MD, Regional TB Reference Centre, Villa Marelli Institute, Niguarda Hospital-Milano, Italy



Hamid (11 years old) - Kyrgyzstan

HAMID* (11 YEARS OLD) KYRGYZSTAN

When he was three years old, Hamid was one of nine children who became infected with HIV at a health facility in Kyrgyzstan. Eight years have passed since Hamid was diagnosed with HIV, but each year has been a constant fight against disease.

The same year Hamid was diagnosed with HIV, he was also diagnosed with hepatitis A, for which he was successfully treated, but a year

later, in 2003, he became sick with TB meningitis. Hamid's compromised immune system made him especially susceptible to TB. With much support from his mother and health care providers, Hamid completed treatment.

Unfortunately, in 2010, Hamid was diagnosed with TB again, but this time disseminated TB with septic shock. He was treated for TB at a local health facility for 10 months before being transferred to a national center with a children's MDR-TB department. At the national center, they performed DST and discovered that Hamid's strain of TB was resistant to all four of the first-line drugs (isoniazid, ethambutol, rifampicin, and streptomycin). Hamid was switched to second-line drugs for eight months and given antiretroviral therapy for his HIV. Over the course of the eight months, Hamid experienced fever, vomiting, rashes, and shortness of breath. Hamid's doctors provided auxiliary treatment to mediate these side effects and offer some relief to Hamid. Hamid was a brave patient and unafraid of "injections and people in white gowns."

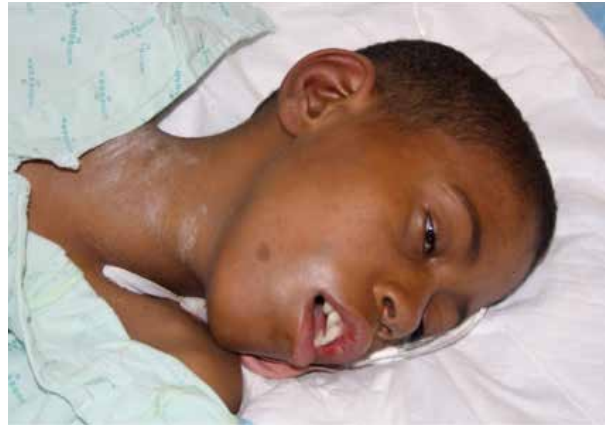A year and a half after Hamid was diagnosed with TB for the second time, he completed treatment and returned home. Hamid returned to his favorite activities: drawing and watching cartoons. His favorite cartoon is "My Neighbor Totoro," in which Totoro, "a big, kind cat," is a superhero. Hamid believes that "one day [he] will meet Totoro, who will protect [him] from diseases under a big umbrella."

**The name of the child in this story has been changed to protect confidentiality.*

SUBMITTED BY:

Zhyldyz Ysykeeva, Project HOPE, Kyrgyzstan

Tom Mohr, Project HOPE, USAID/Quality Health Care Project, Central Asia



Simon (13 years old) - Namibia

SIMON (13 YEARS OLD) NAMIBIA

When he was 12 years old, Simon's mother took him to see a private doctor for a persistent cough. The doctor prescribed antibiotics for him and when he did not get better, the doctor prescribed another course of antibiotics. Still, Simon did not respond. The mother took him back and he started a third course of antibiotics. Simon's health continued to deteriorate, so his mother requested a TB test. She had been treated for TB in 2002. The test confirmed Simon's mother's fear; he had TB.

By the time Simon was diagnosed with TB, protracted and consistent use of medical aid and insurance had depleted Simon's benefits. Simon's mother had no choice but to approach the public health sector to obtain TB treatment for Simon. Based on the positive result of the TB test administered by Simon's private practitioner, Simon was initiated on TB treatment at his first visit with the doctor at the public clinic. At that same visit, DST was ordered on Simon's sputum.

When DST results came back after two weeks, they showed resistance to all first-line TB medicines except ethambutol. Simon was diagnosed with MDR-TB. Given Simon's deteriorating clinical condition, treatment for MDR-TB was initiated soon after the DST results were received. In addition to the DST, Simon, with his mother's consent, was tested and found to have HIV. His mother, who

also had a persistent cough, provided a sputum sample, which tested positive for TB. It was later discovered that Simon's mother had not completed her prior course of TB treatment in 2002. A DST result showed that Simon's mother also had MDR-TB. Simon and his mother were now both being treated for MDR-TB.

Simon is still hospitalized and receiving treatment. He cannot walk or even sit up on his own. He has not spoken for many weeks and is rapidly deteriorating. Sores in his throat make it too painful to swallow his TB medications. As a result, Simon's mother watches her 13-year-old son die a little more each day and asks, "Is there no other way to help my child than giving him pills that he cannot swallow?"

SUBMITTED BY:

Penny Uukunde, Ministry of Health and Social Services (MOHSS), National Tuberculosis and Leprosy Program (NTLP), Namibia

Pinehas Iiping, Ministry of Health and Social Services (MOHSS), Namibia



Duba and his mother when he was first admitted to the hospital

**DUBA (5 YEARS OLD)
PAPUA NEW GUINEA**

When Duba, a five-year-old boy, was admitted to the hospital, his parents and doctors had little hope that he would survive. He was extremely frail and had an enlarged spleen. Duba's mother recollected, "He didn't even look human."



Seven months into treatment

Duba had no history of TB and neither did any of his familial contacts. Like most children, Duba was unable to cough up sputum, but was clinically diagnosed with TB based on his symptoms and admitted to the TB ward of the hospital.

Just prior to Duba's admission to the TB ward, a new program began to scale up TB services in Western Province. The new program focused on the diagnosis and treatment of MDR-TB patients like Duba and piloted a new, rapid diagnostic tool, GeneXpert, which can detect resistance to the first-line drug rifampicin in just 90 minutes, a process that previously had taken more than two months. The program also benefits from a specialized TB ward staffed with eight highly qualified TB doctors and health workers and four outreach staff.

Duba's doctors noticed that he was unresponsive to first-line drugs, diagnosed him with MDR-TB, and initiated second-line treatment. Duba quickly began to put on weight and showed signs of improvement. He was discharged from the hospital and continued treatment under the care of his mother.

Duba's mother has been instrumental in her son's treatment. She offers support and makes sure that Duba takes his medications twice a day. Duba and his mother still report

to the hospital every day so Duba can receive his injections and TB medications. Duba has now completed seven months of treatment and no longer receives the painful injections. He continues to take his oral medications and will do so until he is cured.

SUBMITTED BY:

Western Provincial TB Program, Papua New Guinea

Australian Agency for International Development (AusAID), Papua New Guinea

Health and HIV Implementation Services Provider (HHISP), Papua New Guinea

World Vision, Papua New Guinea

JB (13 YEARS OLD) PHILIPPINES

JB is the fourth child in a family of six children. JB's father works part-time in construction, and his mother is a housewife. In 2005, JB's mother began coughing and vomiting up blood. She was soon diagnosed with MDR-TB at a health facility. The year following JB's mother's diagnosis, the health facility conducted a contact investigation and found that JB, too, had MDR-TB. It was September 2006, and JB was six years old. JB, an honors student, had to stop going to school and instead focus on taking the second-line TB drugs and dealing with their side effects.

Initially, JB's family had trouble making their meager family budget meet JB's daily transportation costs to get to and from the health facility. Support from the Global Fund, in the form of a transportation allowance, eased the financial burden of JB's treatment on his family. Further support was received from a community leader, who offered JB and his mother temporary housing closer to the health facility. Eventually, the health facility agreed that JB could continue his treatment under the observation of a public facility closer to his home. In addition, a food basket was provided for JB each month to improve treatment tolerability and adherence.

JB's mother offered encouragement throughout her son's treatment. JB's mother gave him daily consolation prizes for treatment compliance and made sure that despite the intensity and long duration of JB's treatment, he still had time to play and mingle with friends.

Two years later, at the age of eight years old, JB completed treatment and exclaimed, "at last!" JB is now 13 years old and in his first year of high school. He is still an honors student and receives education assistance from his school for displaying a positive attitude and commitment to his studies.

SUBMITTED BY:

Lung Center of the Philippines

Implementing Arm for Programmatic Management of Drug-Resistant TB (PMDT), Republic of the Philippines

National TB Control Program (NTP), Department of Health, Republic of the Philippines

MALICK* (19 YEARS OLD) SENEGAL

Malick, 17 years old at the time, was first diagnosed with TB in February 2010. He was treated as an outpatient at a health center 30 kilometers (19 miles) from his home for two months with rifampicin, isoniazid, pyrazinamide, and ethambutol, followed by four months of treatment with rifampicin and isoniazid. After completing six months of treatment with first-line drugs, Malick was declared cured of TB.

Unfortunately, Malick's symptoms returned four months later, in early December 2010. This time Malick was evaluated at a health facility closer to his home, where they performed microscopy and sent a culture to the national reference laboratory for DST. Malick was re-treated, but this time his regimen consisted of two months of streptomycin, rifampicin, isoniazid, pyrazinamide, and ethambutol, followed by six months of rifampicin, isoniazid, pyrazinamide, and ethambutol.

Two months into treatment, microscopy done at the local health facility came back negative. At the same time, however, the results from the national reference laboratory came back positive and showed that Malick's strain of TB was resistant to rifampicin, isoniazid, streptomycin, and ethambutol. According to the national reference laboratory results, Malick had MDR-TB. Malick and his parents disagreed with this diagnosis; Malick's physical condition had improved, and the recently performed microscopy from the local health facility was negative. Malick and his parents stopped his treatment.

Three months later, Malick returned to the local health facility where they again performed microscopy and sent a culture to the national reference laboratory. Both came back positive. Malick then refused to be treated at the local health facility; he preferred to travel the 30 kilometers each day to the health center at which he was initially treated. Malick did not reinstate treatment with second-line drugs until September 2011, eight months after he was diagnosed with MDR-TB by the national reference laboratory.

Once Malick was back on track with his second-line therapy, his health began to show signs of improvement; however, one unfortunate effect of his treatment was that Malick experienced memory loss. His doctors monitored him closely for other signs of cardiac, neuropsychiatric, and biochemical trouble. Malick's refusal to receive treatment at the local health facility placed a significant financial burden on his family, who now had to cover the costs of his daily trips to the health center.

Throughout the duration of his lengthy treatment, Malick desperately wanted to return to his studies in transportation logistics, however Malick's father was opposed: they did not have the financial means, and he did not want Malick to risk spreading MDR-TB to others.

Malick, now 19 years old, with the financial support of his brothers, is currently enrolled in his first year of college and is studying transportation logistics.

**The name of the child in this story has been changed to protect confidentiality.*

SUBMITTED BY:

Ramatoulaye Sall Touré, MD, National TB Control Program (NTP), Senegal

Momar Talla Mbodji, MD, Plan International, Senegal

NYEIN* (5 YEARS OLD) SINGAPORE

Nyein was born in Singapore in 2007 to parents originally from Burma. Nyein first began to show signs of illness in March 2008, when she was just one year old.

Nyein's doctors were unable to isolate the bacterium that causes TB in Nyein's sputum samples, but diagnosed her with MDR-TB based on her clinical symptoms and her mother's previous DST-confirmed diagnosis of MDR-TB that was smear-positive (meaning contagious). Nyein's mother's strain of TB was resistant to isoniazid and streptomycin.

Nyein was hospitalized for the first six months of her treatment due to persistently low levels of both red and white blood cells. While she was in the hospital, nurses administered Nyein's daily MDR-TB treatments.

Throughout Nyein's treatment she suffered from multiple intracranial hemorrhages (bleeding in her brain), Candida septicemia (blood poisoning caused by a yeast-like fungus which inhabits the intestines), and severe pneumonia, which resulted in acute respiratory distress syndrome.

After six months in the hospital, Nyein was discharged to the care of her parents. Nyein's mother was experienced in MDR-TB treatment, as she was receiving treatment at the same time, and understood the importance of strict treatment compliance for Nyein at home.

Nyein successfully completed one year of MDR-TB treatment, and at her last clinical visit

review, in June 2011, was cheerful, active, and developing normally. Since then, Nyein and her parents have moved back to Burma.

**The name of the child in this story has been changed to protect confidentiality.*

SUBMITTED BY:

Koh Pei Lin, MD, Department of Pediatrics, National University Hospital, Singapore



Nqobile Nkambule (16 years old) – Swaziland

NQOBILE (16 YEARS OLD) SWAZILAND

When Nqobile was five years old, she lost her father; when she was 12 years old, she lost her mother. Following her mother's death, a grandmother and aunt took care of her. Nqobile is HIV-positive and has been on antiretroviral (ARV) treatment for several years.

For several months, Nqobile was wasting and losing weight, and in April 2010 she developed a cough. Nqobile went to a local health clinic and then followed up at a primary health care facility, but no test for TB was performed at either site. In May 2010, Nqobile was referred to the district hospital. When she arrived at the district hospital, she was 14 years old and weighed only 14 kilograms (31 pounds). Shortly after being admitted to the hospital, Nqobile's doctors determined that she had immunological failure and switched

her to second-line ARV treatment for HIV. After a month and a half on her new ARV treatment, Nqobile continued to lose weight and her cough persisted.

In June 2010, Nqobile's doctors started her on MDR-TB treatment, but they never managed to obtain a positive culture to confirm the diagnosis. Nqobile spent four months in the hospital, where DR-TB treatment was free. While Nqobile was undergoing treatment, her aunt died. Nqobile's grandmother struggled to support Nqobile and two other children. Nqobile's grandmother would spend nights at the hospital, while the two other children under her care stayed with an uncle. Nqobile's grandmother would rush home in the morning to tend to the other two children and return to Nqobile's bedside at night.

After Nqobile was discharged from the hospital, Médecins Sans Frontières and her grandmother paid for transportation costs to the district hospital for daily treatment.

Nqobile often complained about the number of pills she had to take. In addition to her HIV medicines, Nqobile had to take 12 more tablets a day for her MDR-TB treatment. For the first six months of MDR-TB treatment, Nqobile received daily painful injections: "If only the injections could be at least once per month....they were so painful!" Nqobile also suffered from severe diarrhea, a side effect of PAS, one of the TB drugs with which she was being treated; Nqobile would skip taking PAS every other day to have a break from diarrhea. Another side effect of her medications was a burning sensation in her feet.

Even though Nqobile completed treatment and was cured of MDR-TB, she ended up missing a full year of school while undergoing treatment. Nqobile's friends did not know her HIV status; she returned to school and disclosed it to them. She felt accepted, as some of her friends are also HIV-positive.

SUBMITTED BY:

Pilar Ustero, Global Health Corps, Baylor International Pediatric AIDS Initiative (BIPAI), Baylor College of Medicine (BCM), Baylor College of Medicine Children's Foundation, Swaziland

Padma Swamy, Global Child Health Residents, Baylor College of Medicine, Texas Children's Hospital, Baylor College of Medicine Children's Foundation, Swaziland

JANE* (13 YEARS OLD) SWEDEN

Jane, suffering from a mild intellectual disability, was born in India and was diagnosed with TB at age three, but treated only with rifampicin and isoniazid. In 2002, while receiving treatment, Jane was adopted by a family in Sweden. She finished her treatment in Sweden, and her parents and doctor assumed her to be cured.

As Jane approached puberty, her TB infection reactivated, but this time with a vengeance. Jane, now 12 years old, was seriously ill. Her parents took her to see several physicians in Sweden, who all misdiagnosed her symptoms as pneumonia and offered her ineffective treatments for her actual disease. While Jane waited to be correctly diagnosed, her condition became more and more severe.

In July 2011, Jane went to the hospital, where physicians performed cultures and DST. They also obtained sputum as well as other samples using bronchoalveolar lavage (an uncomfortable procedure where a tube is passed through the mouth or nose into the lungs to collect a sample) and gastric lavage. In August 2011, Jane was diagnosed with MDR-TB; her strain of TB was resistant to isoniazid, rifampicin, ethambutol, ofloxacin, moxifloxacin, and rifabutin.

Jane began treatment for MDR-TB and was confined to an isolated room in the hospital for three months. Once her sputum became negative for TB, she was discharged from the

hospital. Nurses then visited Jane at home three days a week for the next coming six months of treatment to administer her injections and perform blood tests.

While receiving treatment, Jane suffered from bone marrow depression, which resulted in five blood transfusions. Jane also suffered from severe vomiting in the first six months of treatment; diarrhea; and fatigue.

Jane and her family did not suffer financially because of TB (treatment is free in Sweden), but they did find themselves socially isolated both as result of the circumstance of the disease and the fact that they spent a majority of their time in the hospital and then at home with Jane.

The fact that TB and MDR-TB are rare in Sweden could result in delayed diagnosis and treatment. Luckily, no one else in Jane's environment was infected, and Jane responded well to treatment, which she completed in February 2013, and is today considered in good health again.

**The name of the child in this story has been changed to protect confidentiality.*

SUBMITTED BY:

Rutger Bennet, MD, Astrid Lindgren Children's Hospital at Karolinska University Hospital, Sweden

JOSE (17 YEARS OLD) TIMOR-LESTE

Jose, like many teenagers in Timor-Leste, is an avid soccer fan who hopes to learn to play guitar one day. Jose was receiving treatment for TB from a local health care organization. When his condition began to worsen, he went to the only MDR-TB facility in Timor-Leste. Jose was diagnosed with MDR-TB in October 2012. He is receiving free treatment, but struggles to adhere to his treatment because



Jose (17 years old) – Timor-Leste

of the horrible side effects of the TB drugs, including blurred vision, ringing in the ears, stomach pains, headache, and vomiting. DST has not yet confirmed Jose's diagnosis; he is currently waiting for the results of a sputum test, which was sent to Adelaide in Australia for pathology.

Jose has several weeks left of intensive facility-based treatment, and another 12 months of community-based treatment will follow. He is an orphan with no education or job. His nurses worry that once released from the facility and started on community-based treatment, Jose won't get the proper nutrition required for treatment tolerability, adherence, and ultimately success.

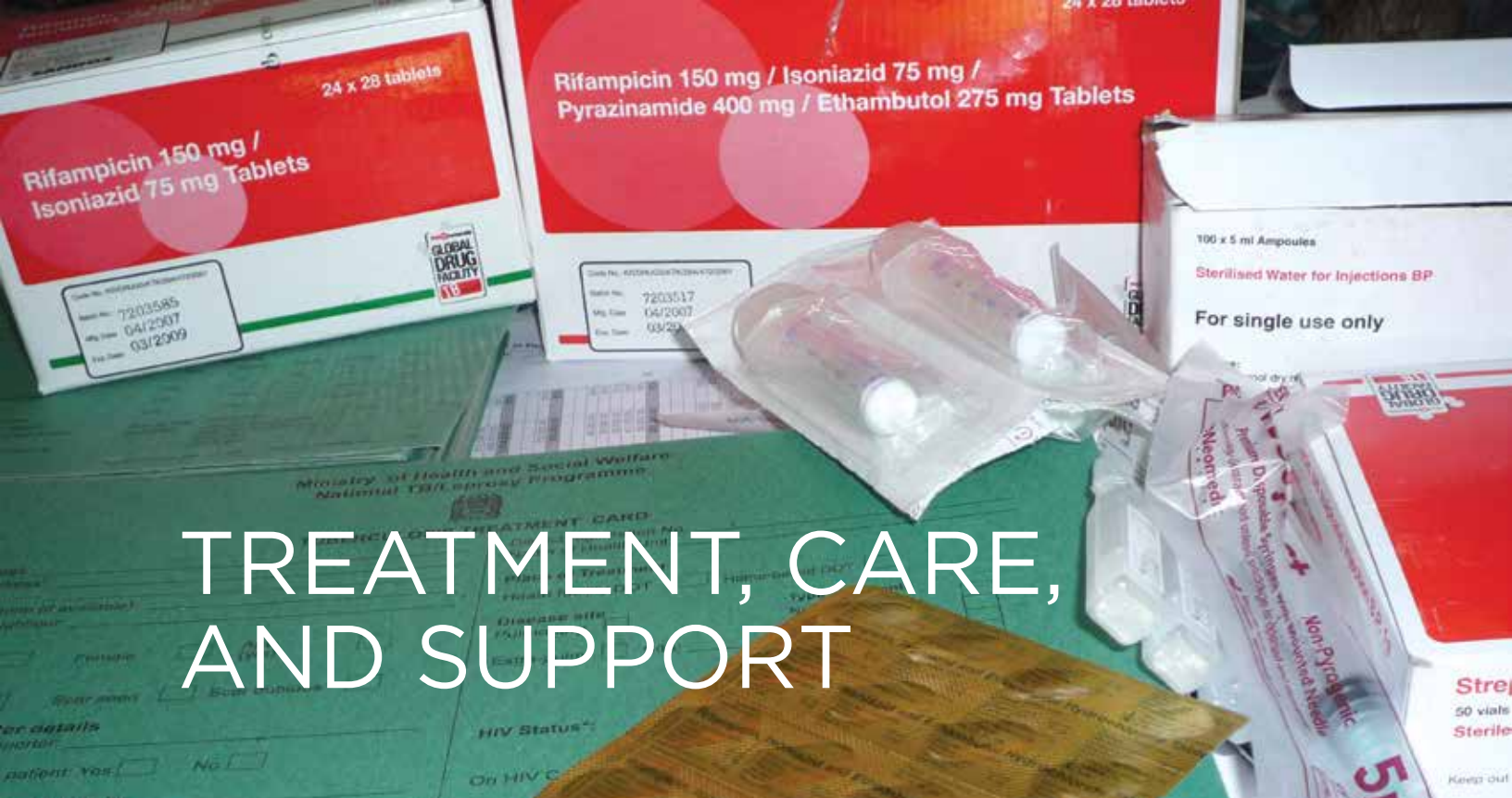SUBMITTED BY:

Joaquim Soares, Klibur Domin Foundation, Timor-Leste

RECOMMENDATIONS

New rapid, accurate tests for children are urgently needed. Traditionally children have been excluded from research in diagnostics and treatment, but it is essential that we develop affordable diagnostic tests for TB in children in all settings. In particular, we need tests that will offer a diagnosis on the day the child comes into the health facility so that treatment can begin immediately where necessary. As such, we need

- application of a family-centered approach to screening for TB, which includes screening of all child contacts of patients with drug-resistant TB;
- improved referral systems and follow-up for child contacts;
- improved training for clinicians and community health workers to detect TB in children;
- improved clinical evaluation guidelines;
- better tests to detect TB and drug resistance in children—specifically, point-of-care tests that are rapid and do not rely on sputum specimens; and
- streamlined communication strategies between diagnostic labs and health care providers and patients.



TREATMENT, CARE, AND SUPPORT

Currently, there are no drug formulations for treating DR-TB in children. Children are forced to take adult formulations that are difficult to ingest and cause horrible side effects, including chronic or irreversible conditions. Existing DR-TB treatments have a high pill burden, require daily injections, and can last up to two years.

Currently, when a child is known to have had contact with another patient with a history of irregular TB treatment or confirmed DR-TB, this information is often overlooked when determining which TB drugs will be included in his or her treatment regimen. While waiting for DST results, children are often started on drugs to which their strain of TB is unlikely to be susceptible.

In many countries, there is an unreliable supply of, or no access at all to, the second-line TB drugs necessary to treat DR-TB. This results in treatment interruptions and delays in treatment initiation, which both jeopardizes patients' health and means they have more opportunity to spread DR-TB to others.

TB treatment, HIV testing and treatment, and other child health services currently exist in silos, exacerbating the burden already placed on the families of children with DR-TB.

The existing standard of treatment in most countries does not include services beyond the provision of TB drugs; auxiliary services are not available to children with DR-TB or their families. However, the need for pain management, hearing tests, nutritional support, travel allowances, and psychosocial support are echoed throughout this collection of stories.

The treatment, care, and support section of this collection offers stories of children with DR-TB who would have benefited greatly from better TB drugs and a more comprehensive approach to treatment. Such an approach includes services, care, and support beyond the provision of TB drugs. These stories underscore areas for improvement in the treatment of pediatric DR-TB.



Menkhu (15 years old) - Nepal

MENKHU* (15 YEARS OLD) NEPAL

Menkhu was living in Nepal with her sisters in impoverished conditions when she first began coughing and experiencing chest pain. One sister took her to a hospital, but the doctor did not diagnose or treat Menkhu's symptoms. That hospital was the first of many that Menkhu would visit while seeking a diagnosis for her respiratory symptoms.

Finally, in July 2011, a community health worker sent Menkhu's sputum sample to the national TB center lab. When the results came in, Menkhu was diagnosed with TB and told to go to the nearest treatment center. When Menkhu reported to the treatment center, they again tested her sputum and, when it came back positive, initiated a full course of first-line drugs. Menkhu took her oral medications and received injections for nine months. Menkhu started to feel better and stopped taking her medications.

Two months later, in March 2012, her symptoms returned. When Menkhu returned to the clinic, they tested her sputum and performed DST. DST found Menkhu's strain of TB was resistant to isoniazid, rifampicin, and ethambutol. Menkhu was diagnosed with MDR-TB, but she was not started on second-line treatment for three months. Second-line drugs are not available at all hospitals in Nepal, and as

a result patients travel from all different districts to the same treatment clinics. Because patients are not provided with housing and travel support, they all prefer to stay at the hospital, leaving little room for new patients and causing delays in treatment initiation.

Eventually, in June 2012, Menkhu was started on second-line drugs. Eight months into her treatment for MDR-TB, Menkhu's condition is deteriorating. She was admitted to the hospital because she is unable to keep her TB medicines down: "If I take any medicine, I immediately start vomiting and the medicine comes out. Again, I have to take another one." Menkhu is taking 13 pills each day and has lost her ability to hear, a side effect of one of her medications. She is also losing weight. While her sisters still take care of Menkhu, ever since her MDR-TB diagnosis, they treat her differently: "I have separate dishes, utensils, and clothes now," which makes Menkhu sad.

**The name of this child in this story has been changed to protect confidentiality.*

SUBMITTED BY:

Britain Nepal Medical Trust (BNMT), Nepal



Mustkeen (12 years old) - India

MUSTKEEN (12 YEARS OLD) INDIA

Mustkeen is 12 years old and lives with his parents and three younger siblings in a crowded slum of Jaipur. Even though Mustkeen's father works as an autorickshaw driver to support his family, he earns less than US\$3 a day, making it a struggle for his family to manage two meals a day. Mustkeen's mother takes care of the children at home. She and her husband hope to give their children a bright and educated future.

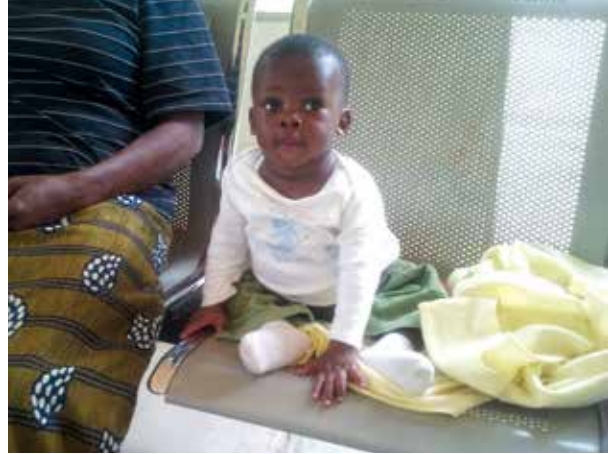In early 2012, Mustkeen developed a cough, chest pain, and difficulty breathing. His family took him to the local medical practitioner who prescribed some drugs, but after two months of treatment, Mustkeen's health worsened. Realizing his own failure to take necessary action, the local doctor referred Mustkeen to a nearby TB hospital. After a positive test result, Mustkeen was put on TB treatment with first-line drugs. When his condition showed no signs of improvement, the medical officer ordered a culture for DST.

In July 2012, Mustkeen was diagnosed with MDR-TB and began treatment at the nearest center, which was not far from his home. Mustkeen dreads the daily injections and hates swallowing the pills that make him nauseous. Sometimes his thin body is doubled over and racked with retching. The worst is the ridicule he endures from neighbors; he has no friends left and was asked to leave school.

Mustkeen keeps a clean cloth on his mouth to prevent the spread of TB to others. This selfless act has made him an object of ridicule. His friends and other children in the neighborhood make fun of him, and his parents have asked his siblings to maintain a distance from him. He feels dejected and alone. The fact that he is responding to his heavy doses of medication and is on the road to recovery is his only consolation.

SUBMITTED BY:

Shelly Batra, MD, Operation ASHA, India



Jomo (1 year old) - Kenya

JOMO* (1 YEAR OLD) KENYA

Jomo never knew his mother. Five days after giving birth to him, Jomo's mother died. She was HIV-positive and treated for TB during her pregnancy.

In April 2012, three-month-old Jomo began showing signs of illness. His family brought him to a private hospital to be evaluated. The clinicians struggled to obtain a sputum sample from three-month-old Jomo, but were eventually successful. They performed cultures and a GeneXpert test. Jomo's family had to pay for these expensive tests, placing a significant financial burden on the family.

Four months later, in August 2012, Jomo was diagnosed with MDR-TB. His cultures and GeneXpert results showed that his strain of TB was resistant to streptomycin, isoniazid, and rifampicin, three of the four first-line drugs.

Jomo experienced delays not only in obtaining a diagnosis, but also in treatment initiation. The private hospital where Jomo was diagnosed did not have an isolation facility for MDR-TB patients, and none of the clinicians felt confident in their ability to treat an infant with MDR-TB. Jomo finally started treatment in October 2012, after he was referred to a government hospital.

The government hospital is far from where Jomo and his family live. The distance makes daily DOT visits difficult, but the treatment is free, providing some financial relief for the family. Audiometry (the testing for hearing loss, a common side effect of second-line TB treatment) is uncommon, and the health care workers who do perform audiometry do not want to go near Jomo or other patients with known DR-TB. Jomo is too young to voice complaints, and as a result Jomo's doctor struggles to detect adverse events.

**The name of the child in this story has been changed to protect confidentiality.*

SUBMITTED BY:

Eunice Wahome, MD, Kenyatta National Hospital, Kenya

**PHU* (17 YEARS OLD)
SOUTHEAST ASIA**

For two years, Phu's father was treated for DR-TB in a TB specialist hospital. The family had to bear the entire cost of his treatment and hospitalization. Phu's mother, who looked after her father while he was hospitalized, died suddenly with no known underlying cause, leaving Phu to look after her father.

In early 2009, Phu's father was discharged from the hospital in good condition, but in June, Phu, 13 years old at the time, developed a persistent cough as well as other worrying respiratory symptoms. She was diagnosed as smear-positive for TB that same month and initiated on first-line TB treatment even though she had a known DR-TB family contact. Phu was supposed to receive DOT, where a health care worker pays daily visits to Phu's home in order to administer her TB treatment, but this was not the case. Phu's aunt reported that "the health staff came just once or twice a month, and sometimes prepared some drugs, such as para-aminosalicylic acid [PAS], packed in plastic bags for daily doses making appointments to return." Poor support and oversight from the DOT health care worker, coupled with financial struggles

resulting in nutrition insufficiencies, made it difficult for Phu to tolerate and adhere to her treatment.

Five months later, in November 2009, Phu was still positive for TB. She was regarded as a treatment failure and re-treated with first-line drugs. After an additional five months, Phu was still testing positive for TB. Her doctor sent a culture for DST to a TB center in the north. While waiting for the DST results, Phu and her family relocated to a northern part of the country without informing the township medical officer.

Once Phu settled in the north, the national program reinitiated her on first-line drug therapy. Phu stayed on first-line drugs for another 12 months, but her health began to deteriorate. Phu's concerned aunt brought her back to her original doctor, who immediately had Phu admitted to the TB specialist hospital where her father had been previously treated. Phu began treatment for MDR-TB in June 2011. While she finally received appropriate treatment for her MDR-TB, she unfortunately developed chronic conditions from her intense MDR-TB treatment regimen, including hypothyroidism and deafness.

Two months into treatment for MDR-TB, Phu's sputum and culture came back negative, her body weight improved dramatically (from 34 kg to 47 kg, or 75 lbs to 104 lbs), and her respiratory symptoms were relieved. But 14 months later, while her sputum smear was still negative, the culture came back positive for TB, and a month later the sputum, too, tested positive. Phu's doctor sent a sputum sample to Bangkok, Thailand, where they will perform second-line DST. While they wait for the DST results, Phu is continuing with second-line drugs for MDR-TB.

**The name of the child in this story has been changed to protect confidentiality.*

SUBMITTED BY:

Anonymous

ADAM (7 YEARS OLD) BELGIUM

Adam is from a region of Somalia where TB is common. There, he had a close relationship with an aunt, who suffered from a severe cough. When Adam was six years old, he and his father moved to Belgium.

Five months later, weighing just 16 kg (35 lbs) and experiencing symptoms of illness, Adam was diagnosed with TB. Adam, like many other children, had trouble producing the sputum normally used to culture the TB organism and determine whether it is drug-resistant. His doctors in Belgium therefore had to perform gastric aspiration to obtain a culture to test for TB. One month and three gastric aspirations later, Adam's doctors discovered that his strain of TB was in fact resistant to all four first-line drugs (isoniazid, rifampicin, ethambutol, and pyrazinamide), as well as two other commonly used TB drugs (streptomycin and rifabutin).

Fortunately, Adam's doctor was able to start him immediately on treatment for DR-TB. Adam began taking pyrazinamide, moxifloxacin, prothionamide, and amikacin, an injectable TB drug. After four months, the lesions on Adam's lungs disappeared from his X-rays. Another gastric aspirate came back culture-negative, confirming that the TB bacteria in his system had been killed, and Adam's general status and weight improved.

In terms of his recovery from TB, Adam, now seven years old, is doing well on treatment. His doctor has to closely monitor Adam's kidney function and hearing, however, as damage to these organs is a potential side effect of the strong medications he is taking. Adam has also developed hypothyroidism as a result of his treatment with prothionamide. In addition to these serious health concerns, throughout the course of his treatment Adam has had to endure nausea and vomiting, painful injections, and swallowing a plethora of pills whose taste he hates.

Despite these complications, Adam was fortunate to access affordable, timely, and quality care, unlike many of his counterparts worldwide. Despite TB's being uncommon in Belgium, Adam's physician promptly suspected and diagnosed TB and initiated DST. Moreover, in Belgium, all costs, including expensive second-line drugs and home-based nursing care for daily injections, are covered. Not only did that spare Adam's family significant expense, but it also allowed for the comfort of home-based treatment. Adam's caregivers also tried to alleviate his suffering by administering local anesthetics before his normally painful injections. Timely diagnosis, DST, access to medicines, and initiation of treatment—along with thoughtful, patient-centered care—have saved Adam's life; however, improved treatment options that shorten time to cure, are injection-free, and have fewer side effects are still needed to improve quality of life for children like Adam with DR-TB.

SUBMITTED BY:

Guido Groenen, MD, Belgian Lung and Tuberculosis Association (BELTA)-Tuberculosis Network European Trialsgroup (TBNET), Belgium

Sophie Blumental, MD, Pediatric Infectious Diseases Department, Hôpital Universitaire des Enfants Reine Fabiola, Belgium

FANNY (9 YEARS OLD) MALAWI

Fanny, who is HIV-positive, developed a fever, generalized body pains, and a persistent cough at six years old. She had no appetite and rapidly began losing weight.

A month after first experiencing these symptoms, Fanny's tested positive for TB. Living with HIV and a weakened immune system made Fanny especially susceptible to acquiring TB.



Fanny (9 years old) - Malawi

Following Fanny's positive TB test, her doctor investigated further, and two months later discovered that Fanny's father had previously been diagnosed with DR-TB. Fanny was diagnosed with DR-TB without any DST confirmation.

The treatment itself was free, but because TB and HIV services are not integrated, Fanny and her family had to travel to two separate health facilities to access Fanny's treatments for TB and HIV. They traveled long distances to the health facilities, which resulted in financial loss to the family, both in actual travel costs and in income lost to time spent in transit.

Fanny's doctors have observed moderate improvements in her physical health. Fanny experiences discrimination and stigma on a daily basis and as a result, despite improvements in her physical health, Fanny's mental health state worsens as she struggles with depression.

SUBMITTED BY:

Clara Banya, Malawi Network of People Living with HIV/AIDS (MANET+), Malawi

Joyce Kamwana, Coalition of Women Living with HIV and AIDS (COWLHA), Malawi

PLOY* (20 YEARS OLD) THAILAND

Ploy is living with HIV and has been taking antiretroviral treatment since the age of 11. Ploy went through a phase of poor treatment adherence when he entered adolescence, which further suppressed his immune system, making him even more vulnerable to TB.

Ploy suffered from prolonged fever, chest pain, and oral candidiasis (an opportunistic fungal infection in the mouth), which led to rapid weight loss for weeks before he was diagnosed, in September 2010, with pulmonary TB. His TB treatment included isoniazid, rifampicin, pyrazinamide, and ethambutol. His TB treatment was taxing both physically and emotionally. Ploy struggled with the large number of pills he had to take each day to fight both TB and HIV; his TB treatment alone involved ten pills.

From September 2010, when Ploy started treatment, to October 2010, his health improved dramatically and his weight increased from 34 kg to 37 kg (75 lbs to 82 lbs); however, Ploy stopped taking his medications consistently and his health began to deteriorate. According to Ploy, "taking medications every day reminds me that I have HIV and TB. It is so painful. I want to hang out with my friends and not have to worry about taking medications on time. I just want to live and feel like a normal teenager."

Ploy has always been afraid of being stigmatized for his positive HIV status due to his very low weight; he is afraid that his friends and work colleagues will discover that he is unwell.

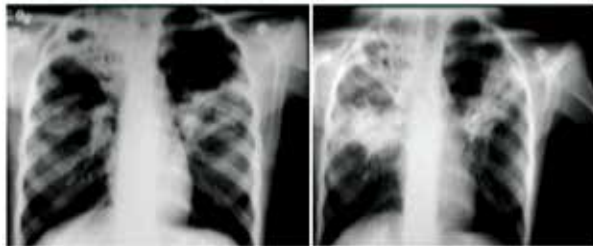
Despite many setbacks, Ploy continued to follow up at the clinic and in May 2011, he became very sick. This time Ploy's sputum grew drug-resistant *M. tuberculosis* and *M. abscessus* (one of many environmental mycobacteria found in water, soil, and dust and distantly related to the mycobacteria that cause TB and leprosy). Ploy had to restart TB treatment with five drugs including a daily injection with streptomycin for two months.

Ploy is determined to continue with his TB/HIV treatment. He quit his job and is staying with his mother. They are helping each other to follow their treatment regimens. Thanks to support from his mother, Ploy's health has improved. Realizing that he might not have contracted active TB had he better adhered to his HIV treatment regimen, Ploy now shares the lessons he learned about the importance of adherence with other HIV-positive children and adolescents at camps and sessions.

**The name of the child in this story has been changed to protect confidentiality.*

SUBMITTED BY:

Thai Red Cross AIDS Research Centre, Thailand



Alessandra - Taken at initiation of treatment (l) Taken 50 days after initiation of treatment (r)

ALESSANDRA (12 YEARS OLD) BRAZIL

In September 2006, Alessandra was 11 years old and experiencing symptoms of TB. Alessandra was often in close contact with her 18-year-old brother, who had been receiving irregular treatment for pulmonary TB. In November 2006, two months after her symptoms appeared, Alessandra was diagnosed with TB.

Her doctor had limited experience treating children with TB, but immediately started her on a treatment regimen containing rifampicin, isoniazid, and pyrazinamide. After two months of treatment, pyrazinamide was removed from her treatment regimen. In January 2007, Alessandra's chest X-rays showed

that she was not improving on her current treatment, and her doctor, who also knew of her older brother's failure to complete treatment, suspected that Alessandra had MDR-TB. A month later, while waiting for the DST results, Alessandra died (February 2007). The DST results later showed that Alessandra's strain of TB was resistant to rifampicin and isoniazid, the two first-line drugs with which her doctor had treated her.

SUBMITTED BY:

Clemax Couto Sant'Anna, MD, PhD, Faculty of Medicine, Federal University of Rio de Janeiro, Brazil

Maria de Fátima Bazhuni Pombo March, MD, PhD, Faculty of Medicine, Federal University of Rio de Janeiro, Brazil



Sofia - 2007 - 15 years old (l), 2010 - 17 years old (r)

SOFIA* (20 YEARS OLD) COLOMBIA

Sofia was 14 years old and focused on her studies when she first started to experience symptoms of illness. In April 2006, a month after she began to feel sick, she was diagnosed with TB. Sofia was treated with streptomycin, isoniazid, rifampicin, and pyrazinamide for six months, but the bacteria persisted. In January 2007, Sofia was prescribed the standard re-treatment regimen in Colombia given to patients who do not successfully culture-convert after their first six months of treatment. This regimen consists of a mix of first- and second-line drugs: three months of streptomycin, ethambutol, pyrazinamide, rifampicin, and ethionamide, and nine months

of ethionamide, ethambutol, isoniazid, rifampicin, and ciprofloxacin. On her new treatment regimen, Sofia began to show signs of clinical improvement, but the bacteria still persisted. During her 18 months of treatment, Sofia struggled to produce sputum samples. Some did not have enough bacteria, while those that did became contaminated, but in October 2007, Sofia was able to successfully produce a culture for DST.

While Sofia and her doctor awaited the DST, they learned that Sofia's father had confirmed MDR-TB in 2003—a strain that was resistant to all first-line drugs. They also learned that he was treated with the available second-line drugs, but did not take his medications regularly and eventually abandoned treatment altogether.

In January 2008, the test results showed that Sofia had MDR-TB and that her strain was resistant to rifampicin and isoniazid, the two most powerful first-line drugs. Sofia went to see a specialist and describes her disheartening experience: "I lived discrimination. A specialist told me that I was going to die, so why would he see me? Saying that I was resistant made all the medical personnel make me feel bad, even though I was using a mask. My family helped me a lot; for them I was not infectious."

In February 2008, Sofia began her treatment for DR-TB, which consisted of 24 months of daily moxifloxacin, linezolid, amikacin, cycloserine, PAS, ethambutol, ethionamide, and amoxicillin. For the first three months of treatment, Sofia was hospitalized for malnutrition, coughing up blood, and adverse effects of the second-line drugs. Her chest X-rays showed extensive lung cavitations (holes where the TB had destroyed lung tissue). Hospitalization and illness forced Sofia to put her studies on hold for 15 months. Sofia disliked the taste of the second-line drugs. She had difficulty swallowing the large pills, and the sheer number of pills she had to take each day ampli-

fied this difficulty. Sofia experienced constant nausea and a loss of appetite. The second-line drugs Sofia needed were not always available; this resulted in treatment interruptions, which are dangerous and can exacerbate drug resistance.

Sofia had medical insurance and received what she described as decent care, but she saw the difficulties other patients without insurance faced in obtaining diagnosis and access to the medications they needed. Even though medical personnel stigmatized Sofia, the support of her family and other patients she had met who were being treated for DR-TB made her feel less alone.

In March 2010, Sofia was cured of TB, but not without cost. The second-line drugs she was treated with caused bilateral hearing loss: 50% of her left-side hearing and 80% of her right-side hearing. Sofia has hearing aids, but they are not enough, and she is unable to continue her education or find work. "Though they don't consider me disabled, they don't give me work because I can't hear." Sofia's hearing loss serves as a daily reminder of her fight with TB, as Sophia said, "*pero logramos curarnos*" (but we can heal).

**The name of the child in this story has been changed to protect confidentiality.*

SUBMITTED BY:

Sandra Ariza Matiz, Enfermera Epidemióloga, Instituto Departamental de Salud, Norte de Santander, Programa de Tuberculosis, Colombia

Santiago Fadul Pérez, Medico Epidemiólogo, Instituto Nacional de Salud (INS), Punto Focal TBFR, Colombia

Cesar Moreira, Medico Magister en Salud Pública (MSP), Colombia

Karime Negrón, Enfermera de Promoción y Prevención, SaludCoop Empresa Promotora de Salud (EPS), Colombia

Román Reyes, Médico Familiar, SaludCoop Empresa Promotora de Salud (EPS), Colombia

EDWIGE* (10 YEARS OLD) CÔTE D'IVOIRE

Edwige, nine years old and HIV-positive, began to experience symptoms of illness at the end of November 2011. She was diagnosed with TB the first week of December 2011. Previously, Edwige's mother had been diagnosed with TB. Edwige was treated with first-line drugs, but did not show signs of improvement. Her doctor performed molecular DST and, in May 2012, diagnosed Edwige with MDR-TB. Her strain of TB was resistant to isoniazid and rifampicin, the two most powerful first-line drugs.

Even though Edwige was diagnosed with MDR-TB seven months earlier, in December 2012 she was still waiting to start treatment. The hospital that Edwige's doctor works at has a list of 258 patients waiting for second-line drugs. Both the Both the Cote d'Ivoire government and the Global Fund purchase second-line drugs for TB patients in Côte d'Ivoire, but the Global Fund drugs are delayed, and there are only 50 treatment kits available in the country. Edwige's doctor knows that the drugs they ordered will not be enough to treat all of their patients.

Edwige's mother passed away in 2012 and left her daughter waiting to initiate treatment. If desperately needed second-line drugs do not arrive soon, it is possible that Edwige will lose her fight with TB and share her mother's fate.

**The name of the child in this story has been changed to protect confidentiality.*

SUBMITTED BY:

Serge Agbo, MD, MPH, Elizabeth Glaser Pediatric AIDS Foundation, Washington, D.C.

Clement Adje Tchomian, MD, Elizabeth Glaser Pediatric AIDS Foundation, Côte d'Ivoire

Adadé Olivier, MD, National TB Program (PNTL), Côte d'Ivoire

CORDARO* (8 YEARS OLD) MEXICO

Cordaro, an HIV-positive and malnourished seven-year-old, began experiencing symptoms of illness in December 2011. A full year after his symptoms first started, Cordaro was diagnosed with TB. He began taking first-line TB drugs with his HIV medications, but had trouble adhering to his treatment regimen. Cordaro struggled with the side effects of his TB medications. Eventually, poor treatment adherence resulted in Cordaro's strain of TB developing resistance to some of the TB medications he was being treated with.

Using gastric aspiration, Cordaro's doctors were able to obtain a culture for DST. In May 2012, five months after initiating treatment with first-line drugs, Cordaro's doctors determined that his strain of TB was resistant to isoniazid and rifampicin, the two most powerful first-line drugs. Cordaro was diagnosed with MDR-TB. At the time of his MDR-TB diagnosis, Cordaro was discriminated against and stigmatized by his health care providers because he was HIV-positive. Cordaro's father believes that if Cordaro's health care providers had received sensitivity training, his son would not have experienced stigma and discrimination at the health care facility and would have received better quality care.

The health institution was overburdened with patients, and as a result, Cordaro's doctors could not start him on second-line TB drugs for four months. Cordaro's health was declining, a direct result of TB/HIV coinfection. Cordaro was admitted to the hospital with respiratory complications, excessive sweating, shortness of breath, fever, and opportunistic infections. While receiving treatment, Cordaro became depressed and his sense of taste changed. He also experienced liver and kidney damage, likely caused by the toxic second-line drugs he was taking. Unfortunately, public health insurance only covered some of the health services Cordaro desperately needed, the others



Ismael (17 years old) - Somalia



were too expensive for Cordaro's family. As a result, Cordaro was denied necessary health services, adversely affecting his quality of life during treatment.

**The name of the child in this story has been changed to protect confidentiality.*

SUBMITTED BY:

Francisco Rosas, Vivir, Participación, Incidencia y Transparencia, A.C., Mexico

**ISMAEL (17 YEARS OLD)
SOMALIA**

Ismael grew up in a migrant community in Somalia. He first began experiencing symptoms of illness in November 2007, when he was 12 years old. The same month his symptoms began, Ismael was diagnosed with TB. Ismael successfully finished treatment in 2008, but two years later tested smear-positive for TB. Ismael was treated as a relapse case and hospitalized for three months. After leaving the hospital Ismael defaulted on his re-treatment. He was working as a bus conductor and could not leave work to receive his directly observed treatment.

In July 2012, Ismael's sputum was tested for resistance to rifampicin using the GeneXpert system. The result came back positive and Ismael was diagnosed with DR-TB, but there is currently no treatment for DR-TB in Somalia. Even though GeneXpert improves Somalia's

clinicians' capacity to diagnose DR-TB, they are limited in their ability to treat DR-TB patients once they are diagnosed. Ismael is still waiting for second-line drugs to initiate treatment.

Ismael now knows the importance of treatment adherence and desperately wants to be treated for DR-TB. Ismael cannot work and faces discrimination from his own family. His siblings fear him and keep a distance. Only his father offers support. He feels weak and is losing hope: "I don't know if I can survive for the next three months. I have suffered for a long time."

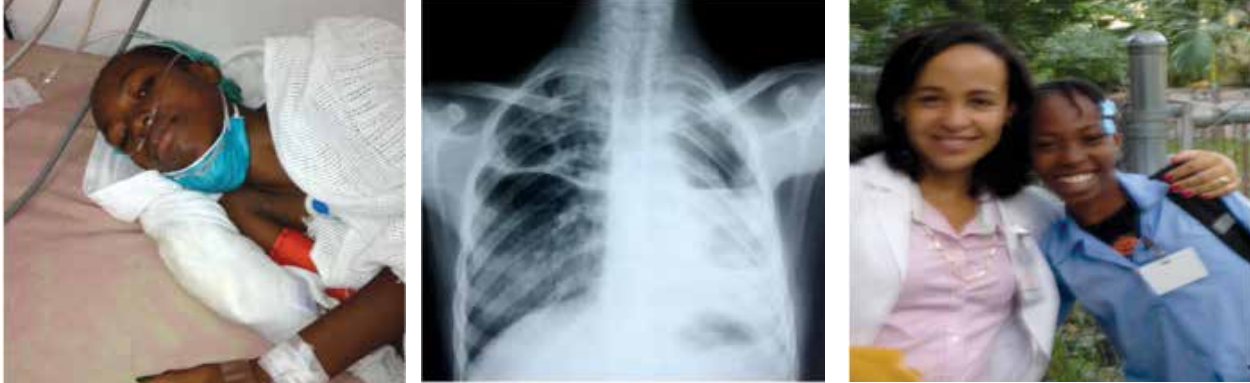SUBMITTED BY:

Hassan Mohamed Sheik Noor, National TB Program (NTP), Hargeisa, Somalia

Vianney Rusagara, MD, Global Fund Director, World Vision International, Somalia

**MARIE* (13 YEARS OLD)
HAITI**

Marie's mother, Yolande, is HIV-positive and Yvenson (her fifth child) was being followed as part of a mother-to-child transmission prevention program. Yvenson, only 14 months old, was very ill with severe acute malnutrition, anemia, and persistent fever. Marie went with her mother to bring Yvenson to the doctor where he would be worked up for probable TB. At Yvenson's doctors visit the physi-



Marie (13 years old) – Haiti post lung surgery (l), post surgery December 2012 (c), Marie and her pediatrician

cian noticed that Marie, a very thin but active and joyful nine-year-old girl at the time, had a terrible cough. A chest X-ray and sputum smears confirmed that Marie had pulmonary TB, and was the index case in the home. Marie's five-year-old brother, Jamesley, who is HIV-positive, was later also diagnosed with pulmonary TB.

Marie was found to be HIV-negative and initiated standard first-line TB therapy in November 2009, but Marie struggled to adhere to her treatment; she missed her appointments and did not take her medication regularly. As the only girl in a family of five children, Marie was left in charge of her two younger siblings while her mother went to work at the markets each day.

Despite multiple calls and reminders to come to appointments, all three children were failing their treatment by the end of the first month; shortly thereafter, Haiti was devastated by the earthquake of January 2010.

Shortly after the earthquake, Yvenson began suffering from severe seizures. His doctors discovered that Yvenson's untreated TB in his lungs had spread to his brain (TB meningitis). He was hospitalized for three weeks at a field hospital. It is remarkable that Yvenson survived after being intubated and on life support in the field hospital for an entire week. Even though Yvenson survived, he was left blind. Marie's other brother, Jamesley, was removed from their mother's care and sent to

live with an aunt who was able to ensure that he took his HIV and TB medications regularly.

Sadly, no one in the family was able to oversee Marie's care, and her partially treated TB slowly acquired resistance. By March 2010, Marie had developed resistance to isoniazid. Streptomycin was added to her TB regimen, and she was hospitalized for part of the treatment to ensure directly observed therapy (DOT), but she again stopped regularly taking her TB medications after she was discharged from the hospital.

At the end of March 2011, a neighbor found Marie vomiting blood at home and brought her back to the hospital. Her sputum tests were again positive for TB, and the GeneXpert test confirmed that in addition to her existing resistance to isoniazid, Marie had developed resistance to the rifampicin; Marie now had MDR-TB. Her chest X-ray showed multiple large cavities in both lungs with destruction of the entire left lung. She was hospitalized at an MDR-TB field hospital in critical condition, coughing up large amounts of blood, and requiring multiple blood transfusions. MDR-TB treatment was initiated in April 2011, and Marie improved quickly thereafter.

Marie's mother abandoned her at the hospital, visiting her only four times during her 14-month stay. Marie was preadolescent and became depressed. She started to refuse her MDR-TB treatment, hiding from the nurses or spitting the drugs out.

Six months after initiation of MDR-TB treatment, Marie's sputum smears and cultures were again positive. Support strategies were reinforced and initially helped, and her sputum cultures were again negative.

The injectable drug, kanamycin, was stopped 14 months after initiation of MDR-TB treatment, since Marie had had five consecutive negative TB cultures. In May 2012, following the discontinuation of treatment with kanamycin, Marie was discharged from the field hospital and went to live with her uncle, as her doctors were concerned about Marie's mother's willingness to supervise her care.

The same month Marie was discharged from the hospital, her sputum smears and cultures were again positive despite twice-daily DOT by a nurse. After 18 months of MDR-TB treatment, Marie's sputum cultures remained persistently positive. Repeated drug susceptibility tests confirmed that she had not acquired drug resistance to any other TB medications. Scans of her lung demonstrated severe scarring and fibrosis throughout her left lung, which was functionally dead. Multiple MDR-TB specialists evaluated her case and came to the decision that it would not be possible to cure her without removing the left lung, because the drugs could not penetrate the dead and infected left lung tissue. The only way to save Marie would be to remove her left lung so that her right lung could be effectively treated. This was an extremely difficult decision, because there is no thoracic surgeon or pulmonary specialist in all of Haiti. A pediatric surgeon from California who regularly works in Haiti evaluated Marie's case and agreed to operate.

The surgery went well, and currently Marie is in stable condition, but she remains culture-positive one month after her lung surgery. Over the course of Marie's treatments, the left lung, now removed, had continually reinfected the right lung. Ideally Marie would be treated again with several months of an injectable drug such as kanamycin, in

addition to her oral MDR-TB medications; however, Marie has already received 14 months of kanamycin, which severely damaged her hearing. A recent audiogram showed that Marie has severe bilateral hearing loss. If Marie is retreated with kanamycin, it is likely that she will become deaf. To avoid retreatment with kanamycin, Marie's doctors are in the process of completing an application for the compassionate use of bedaquiline (a new MDR-TB drug that just received FDA approval for the treatment of MDR-TB in the United States) to optimize her treatment regimen without worsening her hearing.

In spite of all of her difficulties, Marie is back in school and optimistic about her future. She has bonded with her doctors and nurses, and is taking all of her medications as prescribed. She looks forward to being cured of her MDR-TB, graduating from high school, and starting a new life.

**The name of the child in this story has been changed to protect confidentiality.*

SUBMITTED BY:

Vanessa Rouzier, Haitian Group for the Study of Kaposi's Sarcoma and Opportunistic Infections (GHESKIO), Port-au-Prince, Haiti

Serena Patricia Koenig, MD, Partners In Health, Brigham and Women's Hospital, Boston, United States of America

RECOMMENDATIONS:

Better drugs—including faster-acting and less-toxic drugs that do not require injections— and drug formulations for children are urgently needed. While better TB drugs are necessary for cure, they are not sufficient. For successful treatment completion and outcomes, it is essential to take a more comprehensive approach to TB treatment, which includes services, care, and support beyond the provision of TB drugs. We therefore need

- implementation of a patient-centered approach to care, which provides comprehensive services (pain management, hearing tests (audiometry), nutritional support, and travel allowances) and psychosocial support to children with drug-resistant TB and their families;
- delivery of DR-TB treatment regimens for children that promise the best chance of cure, including the use of empirical regimens in patients without bacteriologic confirmation or who are awaiting DST results;
- integration of care with other health programs, including migrant services, HIV services and existing child health programs;
- child-friendly formulations of TB drugs that have a low pill burden, are easier to ingest, taste better, and do not require injections;
- faster-acting, more tolerable drugs with fewer side effects; and
- a steady and reliable supply of TB drugs.

CONCLUSIONS

This collection of 30 stories of children from 30 countries reveals the geographically broad distribution of drug-resistant forms of TB in children of all ages. Moreover, these stories are a testament to the need for improvements in systems and tools.

Numbers can certainly paint a picture of the extent of a disease, but it is the human faces behind them that allow us to truly see what is lost—and what can be saved—when we commit ourselves to better health for all children. Millennium development goal (MDG) 4, reduce child mortality, will remain elusive until we commit political will and resources to the goal of tackling all forms of TB in children. Only then will we be able to ensure that all children can lead healthy and productive lives.

These stories illustrate the need for better preventive, diagnostic, and treatment approaches to ensure that no child dies from DR-TB, a disease we know how to cure. As young Sofia from Colombia states, “We can heal,” but it is our job as a global community to help these children heal with strong commitment and unwavering support.

RESOURCES

FROM THE SENTINEL PROJECT ON DRUG-RESISTANT TUBERCULOSIS

Management of Multidrug-Resistant Tuberculosis in Children: A Field Guide. Boston, USA: The Sentinel Project for Pediatric Drug-Resistant Tuberculosis; November 2012.

Available from: <http://sentinel-project.org/treatment-guidance/>. Printed copies are also available. Please send a request to: sentinel_project@hms.harvard.edu

Seddon J, Furin J, Gale M, et al; Sentinel Project on Pediatric Drug-Resistant Tuberculosis. Caring for children with drug-resistant tuberculosis: practice-based recommendations. *Am J Respir Crit Care Med.* 2012 Nov 15;186(10):953-64.

Abstract available from: <http://ajrccm.atsjournals.org/content/186/10/953.abstract>

Seddon J. The use of practical tools and approaches to the diagnosis and treatment of children with DR-TB. Paper presented at: Preventing child deaths from drug resistant tuberculosis. 43rd Union World Conference on Lung Health; 2012 November 13-17; Kuala Lumpur, Malaysia.

Available from: <http://sentinel-project.org/workshops>

FROM COMPANIONS IN THE FIGHT AGAINST TB AND PEDIATRIC TB

Aspiring to Zero TB Deaths, New Infections, and Suffering Symposium Presentations.

Kuala Lumpur, Malaysia, November 2012

TB/HIV in Children; Ben Marais

Family Centered Approach; Mercedes Becerra

<http://www.treatmentactiongroup.org/tb/advocacy/zero-symposium>

Children and Tuberculosis, From Neglect to Action

[http://www.action.org/images/general/Children_and_TB_Update_-_English_\(4\).pdf](http://www.action.org/images/general/Children_and_TB_Update_-_English_(4).pdf)

Desk-Guide for Diagnosis and Management of TB in Children. International Union Against Tuberculosis and Lung Disease (IUATLD)

http://www.uphs.upenn.edu/bugdrug/antibiotic_manual/iautldtbkidsdxrx2010.pdf

Guidance for National Tuberculosis Programmes on the Management of Tuberculosis in Children. Stop TB Partnership Childhood TB Subgroup, World Health Organization

http://www.stoptb.org/wg/dots_expansion/assets/documents/IJTLD_OS_ChildhoodTB_Chapter1.pdf

New Reference Standards for TB Diagnostics in Children; Grania Brigden. Global Health Diagnostic

<http://globalhealthdiagnostics.tghn.org/articles/new-reference-standards-tb-diagnostics-children/>

No More Crying, No More Dying. Towards Zero TB Deaths in Children.

http://www.stoptb.org/assets/documents/news/ChildhoodTB_report_singles.pdf

Rapid Advice: Treatment of Tuberculosis in Children.

http://whqlibdoc.who.int/publications/2010/9789241500449_eng.pdf



A drawing from Hamid,* 11 years old, from Kyrgyzstan. Hamid has HIV and is a survivor of drug-resistant tuberculosis and hepatitis A. He believes that one day he will meet Totoro, a superhero cat, who “will protect [him] from diseases under a big umbrella.”

*This child's name has been changed to protect confidentiality.

Front cover: Nqobile, Swaziland, now cured of multidrug-resistant tuberculosis (MDR-TB)