

## Abdominal and pelvic actinomycosis due to longstanding intrauterine device: a slow and devastating infection

Evelyn Sue Nakahira<sup>a</sup>, Linda Ferreira Maximiano<sup>b</sup>, Fabiana Roberto Lima<sup>c</sup>,  
Edson Yassushi Ussami<sup>b</sup>

Nakahira ES, Maximiano LF, Lima FR, Ussami EY. Abdominal and pelvic actinomycosis due to longstanding intrauterine device: a slow and devastating infection. *Autopsy Case Rep* [Internet]. 2017;7(1):43-47. <http://dx.doi.org/10.4322/acr.2017.001>

### ABSTRACT

Actinomycosis is a chronic or subacute bacterial infection characterized by large abscess formation, caused mainly by the gram-positive non-acid-fast, anaerobic, or microaerophilic/capnophilic, obligate parasites bacteria from the *Actinomyces* genus. Although pelvic inflammatory disease is an entity associated with the longstanding use of intrauterine devices (IUDs), actinomycosis is not one of the most frequent infections associated with IUDs. We present the case of a 43-year-old female patient who was referred to the emergency facility because of a 20-day history of abdominal pain with signs of peritoneal irritation. Imaging exams revealed collections confined to the pelvis, plus the presence of an IUD and evidence of sepsis, which was consistent with diffuse peritonitis. An exploratory laparotomy was undertaken, and a ruptured left tubal abscess was found along with peritonitis, and a huge amount of purulent secretion in the pelvis and abdominal cavity. Extensive lavage of the cavities with saline, a left salpingo-oophorectomy, and drainage of the cavities were performed. The histopathological examination of the surgical specimen revealed an acute salpingitis with abscesses containing sulfur granules. Therefore, the diagnosis of abdominal and pelvic actinomycosis was made. The postoperative outcome was troublesome and complicated with a colcutaneous fistula, which drained through the surgical wound. A second surgical approach was needed, requiring another extensive lavage and drainage of the recto-uterine pouch, plus the performance of a colostomy. Broad-spectrum antibiotics added to ampicillin were the first antimicrobial regimen followed by 4 weeks of amoxicillin during the outpatient follow-up. The patient satisfactorily recovered and is already scheduled for the intestinal transit reconstitution.

### Keywords

Actinomycosis; Salpingitis; Oophoritis; Abscess, Intestinal Perforation; Fistula

### CASE REPORT

A 43-year-old female inmate was referred to the emergency facility complaining of diffuse abdominal pain for the last 20 days that had recently

worsened. On admission, the physical examination revealed an ill-looking patient, dehydrated, tachypneic (30 respiratory movements per minute), and tachycardic

<sup>a</sup> Faculty of Medicine - Universidade de São Paulo, São Paulo/SP – Brazil.

<sup>b</sup> Division of Surgery - Hospital Universitário - Universidade de São Paulo, São Paulo/SP – Brazil.

<sup>c</sup> Anatomy Pathology Service - Hospital Universitário - Universidade de São Paulo, São Paulo/SP – Brazil.

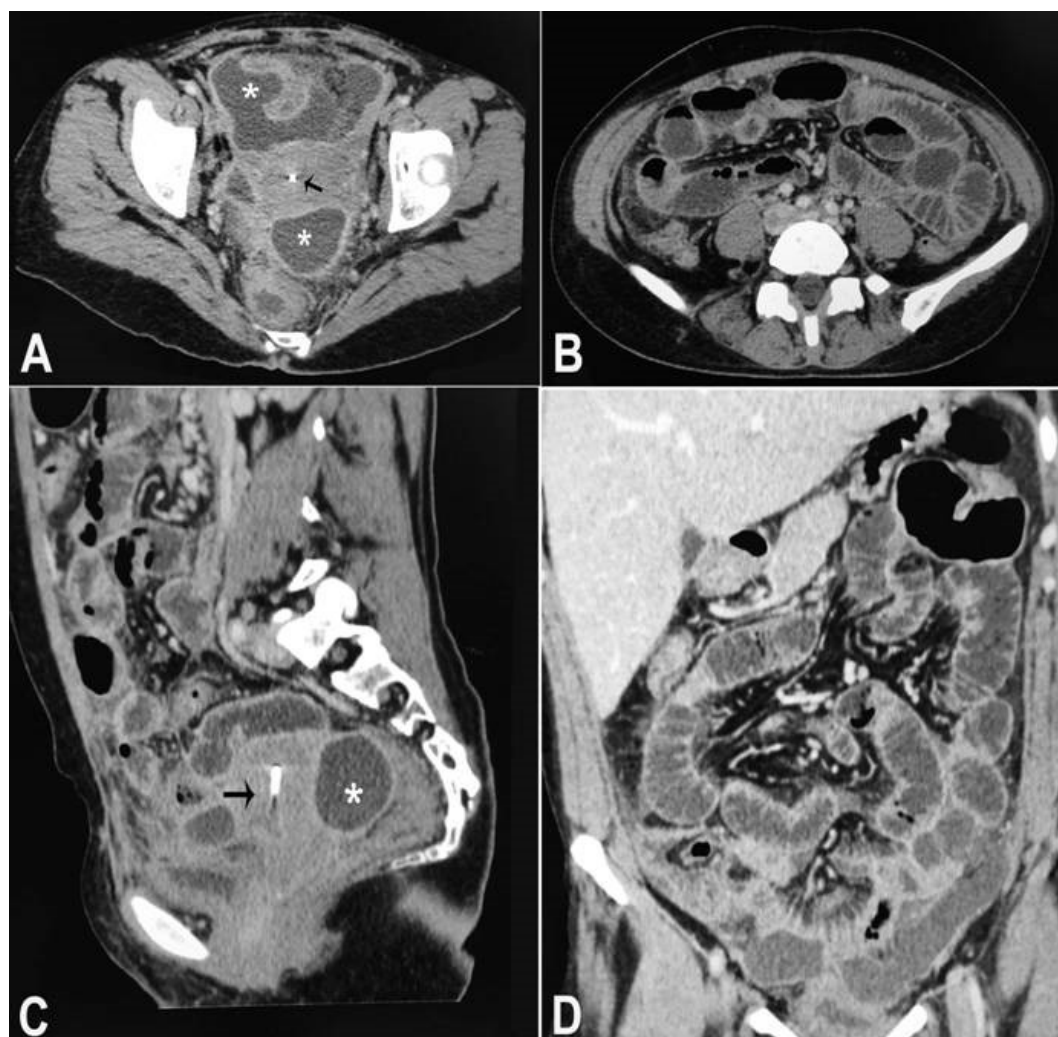


(124 beats per minute) with a blood pressure of 100/60 mmHg. The abdominal examination showed tenderness on superficial and deep palpation of the lower abdomen and left iliac fossa. On gynecological examination, there was a small amount of yellowish vaginal discharge and pain during the internal pelvic exam (cervix mobilization). The patient had had an intrauterine device (IUD) for 7 years. The initial laboratory work-up revealed mild anemia; leukocytosis with left shift; acute renal failure; mild elevation of liver and canalicular enzymes; direct hyperbilirubinemia; and elevated C-reactive protein. Blood and urine cultures and HIV were negative.

The abdominal and pelvic computed tomography (CT) showed the presence of at least three poorly defined collections in the pelvis with densification of the fat adnexal planes, besides the dilation and thickening of some small bowel loops, and the presence of an IUD (Figure 1).

Because of the signs of peritoneal irritation and sepsis, and the imaging findings, an exploratory laparotomy was performed. Surgical findings included diffuse purulent peritonitis with a huge amount of pus covering the intestinal loops. The digital dissection disclosed purulent collections and extensive phlogosis mainly over the left pelvic region where a left tubo-ovarian abscess with tubal rupture was found. The rectum, although also involved in the inflammatory process, was apparently non-injured. The patient underwent a left salpingo-oophorectomy and drainage of the abdomen and pelvis by Waterman drain tube. The IUD was removed. The culture of the peritoneal fluid was positive to *Escherichia coli*.

The postoperative recovery was troublesome and required vasoactive drugs for hemodynamic stabilization and the prescription of broad-spectrum antibiotics. The patient outcome worsened and a surgical wound dehiscence with fecaloid secretion drainage occurred.



**Figure 1.** Abdominopelvic CT showing diffuse thickening of the bowel loops' wall, multiple thick fluid collections (asterisk) and IUD (black arrow). **A, B** - axial plane; **C** - sagittal plane; and **D** - coronal plane.

A second laparotomy was performed at which a rectal lesion was found. The lesion was sutured and an extensive peritoneal cavity lavage with saline and a loop sigmoidostomy were performed.

The histopathologic examination of the left tube and ovary revealed an acute salpingitis with abscess formation, and bacterial colonies and granules of *Actinomyces* sp. (Figure 2). Ampicillin was added to the antibiotic regimen and the patient's clinical condition improved substantially. She was discharged with the prescription of amoxicillin for the next 4 months. Currently, she is attending our outpatient clinic with the transit reconstruction scheduled.

## DISCUSSION

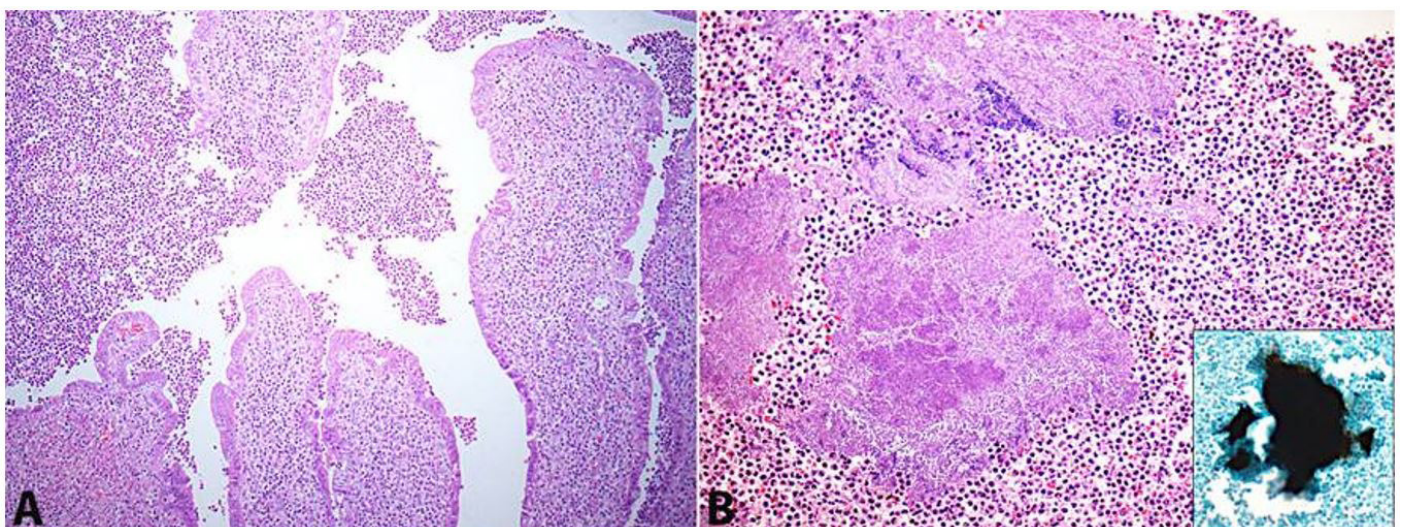
Actinomycosis is a rare, subacute, or chronic suppurative disease, which, in more than 98% of the cases, is caused by the Gram-positive non-acid-fast, anaerobic or microaerophilic/capnophilic, filamentous, obligate bacteria of the *Actinomyces* species. The incidence of this infection is 1:300,000.<sup>1</sup> However, other associated bacterial genera may also be involved in the etiology of this entity, such as *Propionibacterium* and *Bifidobacterium*. Microorganisms from *Actinomyces* spp. are opportunistic pathogens that are usually present in the tonsillar crypts, oral cavity, and gastrointestinal and genital flora of healthy individuals, and play an important role in soil ecology.<sup>2,3</sup> In 1878,

James Israel, a German surgeon, was the pioneer in demonstrating this infection in humans, reporting two cases of actinomycosis.<sup>4,5</sup>

Actinomycosis involves the facial and cervical region in up to 60% of the cases, the abdominal region in 30%, the thoracic region in 20%, and the pelvic region in approximately 3-5%.<sup>2</sup> Pelvic actinomycosis is usually associated with the longstanding use of IUDs,<sup>6-8</sup> and frequently represents a challenging diagnostic task because of the similarity with tuberculosis, malignancy, or other abdominopelvic inflammatory disease.<sup>1,6,7</sup>

Most of the actinomycotic infections are polymicrobial, which are directly associated with the severity of the infection and the invasiveness of the *Actinomyces* spp. in addition to the injury to mucous membranes, and the presence of foreign bodies and devitalized tissue.<sup>1,9</sup>

Preoperative diagnosis of pelvic actinomycosis is quite difficult. The presence of *A. israelii* in the female genital tract may represent colonization when symptoms are absent. Cervical or endometrial cytology positive for *Actinomyces* spp. is not necessarily diagnostic of pelvic actinomycosis. The culture of the IUD or the endometrial biopsies is another diagnostic strategy.<sup>6</sup> However, lower abdominal pain, mass, vaginal discharge, hematuria, fever, leukocytosis, and an elevated erythrocyte sedimentation rate—although non-specific—may raise the suspicion.<sup>9,10</sup> Imaging methods also lack specificity and cannot distinguish



**Figure 2.** Photomicrography of the surgical specimen. **A** - Acute salpingitis with ulceration and pus filling the lumen (H&E, 100X). Additionally, there were transmural inflammatory infiltrate and abscess formation in the fallopian tube; **B** - Basophilic granules of *Actinomyces* sp. which are enveloped by the purulent exudate (H&E, 200X). The inset shows a positive granule highlighted by Grocott's methenamine silver stain (200X).



actinomycosis from tumoral, inflammatory, and infectious causes.<sup>6</sup> The CT findings of our patient, such as bowel wall thickening and a regional pelvic or peritoneal mass with an extensive infiltration pattern, are common findings in patients with actinomycosis.<sup>11</sup>

When cervical or endometrial cytology is positive for *Actinomyces* spp., it usually does not mean an association with pelvic actinomycosis. The culture of the IUD and endometrial biopsies are other strategies of diagnosis.<sup>6</sup>

Bacteriological diagnosis of actinomycosis is difficult and laborious. *Actinomyces* spp. are very sensitive to oxygen, cultures should be processed within 15 minutes and placed immediately in anaerobic conditions and incubated for a long time to show positive growing (from 5 to 20 days, and up to 76% of the cultures are negative).<sup>2,6,12,13</sup> Gram staining of the pus and the histopathology of the infected tissue are more sensitive than the culture for the diagnosis. The presence of sulfur granules, which stain Gram-positive with a mycelium-like structure, is consistent with actinomycosis and may be present in 50% of the cases.<sup>2,12,14</sup>

Up to 71% of the cases of actinomycosis have been diagnosed by surgical biopsies, which demonstrates the importance of surgical intervention and sampling for the diagnosis.<sup>15</sup> The combined surgical and antibiotic treatments produce satisfactory results in more than 90% of the cases.<sup>16</sup> The long-term antibiotic regimen is of paramount importance for the treatment. However, all the severe and complicated cases need to be treated in association with surgical intervention.<sup>12,14</sup> There are no randomized controlled studies concerning antibiotic regimens;<sup>15</sup> however, prolonged antimicrobial use is recommended and the surgical resection of infected tissue may shorten the length of therapy. Penicillin G or amoxicillin are the most commonly used antibiotics,<sup>16</sup> but *Actinomyces* spp. are susceptible to other beta-lactams.<sup>14,16</sup>

Our patient presented a severe case of abdominopelvic actinomycosis associated with a longstanding use of an IUD. She was brought to the emergency facility with 20 days of abdominal pain, but no other complaint was recorded, such as vaginal discharge or fever. The delay in seeking medical care was probably because she resided in prison, what favored the dissemination and the severity of the infection. The first surgical intervention

focused on the peritoneal lavage, the drainage, and the salpingo-oophorectomy, as the primary source of infection and the devitalized tissue. The adnexal fat tissue was infiltrated and surrounded by pus. We consider that at the time of the first operation, the rectum was already invaded by the infection, but no fistula was present. During the postoperative period, the rectum injury evolved and the fistula ensued, which required a second procedure. Secondary involvement of gastrointestinal tract in actinomycosis had already been reported, and perforation may have occurred in many sites of the large and small bowel.<sup>10,11,17-24</sup>

## CONCLUSION

Actinomycosis is an under-reported infection probably because of misdiagnosis, difficulties in confirming the diagnosis, and the empiric use of antibiotics.<sup>15</sup> However, the awareness of the association of peritonitis, pelvic inflammatory disease, pseudotumoral images, and intestinal fistula with the longstanding use of IUDs may help early diagnosis and provide better incidence data.

## REFERENCES

1. Montori G, Allegri A, Merigo G, et al. Intra-abdominal actinomycosis, the great mime: case report and literature review. *Emerg Med Heal Care*. 2015;3(1):2. <http://dx.doi.org/10.7243/2052-6229-3-2>.
2. Boyanova L, Kolarov R, Mateva L, Markovska R, Mitov I. Actinomycosis: a frequently forgotten disease. *Future Microbiol*. 2015;10(4):613-28. PMID:25865197. <http://dx.doi.org/10.2217/fmb.14.130>.
3. Baraket O, Itaimi A, Triki W, et al. Difficultés diagnostiques et thérapeutiques de l'actinomyose abdominale : à propos d'une observation chez une patiente tunisienne. *Bull Soc Pathol Exot*. 2016;109(2):84-6. PMID:27100860. <http://dx.doi.org/10.1007/s13149-016-0482-5>.
4. Israel J. Neue Beobachtungen auf dem Gebiete der Mykosen des Menschen. *Arch Pathol Anat Physiol Klin Med*. 1878;74(1):15-53. <http://dx.doi.org/10.1007/BF01881092>.
5. Cone LA, Leung MM, Hirschberg J. *Actinomyces odontolyticus* bacteriemia. *Emerg Infect Dis*. 2003;9(12):1629-32. PMID:14720410. <http://dx.doi.org/10.3201/eid0912.020646>.
6. Mbarki C, Ben Abdelaziz A, Sahnoun R, et al. Actinomyose pelvienne: aspects diagnostiques et thérapeutiques.

- Gynecol Obstet Fertil. 2016;44(3):168-74. PMID:26857044. <http://dx.doi.org/10.1016/j.gyobfe.2016.01.003>.
7. Yilmaz M, Akbulut S, Samdanci ET, Yilmaz S. Abdominopelvic actinomycosis associated with an intrauterine device and presenting with a rectal mass and hydronephrosis: a troublesome condition for the clinicians. *Int Surg*. 2012;97(3):254-9. PMID:23113856. <http://dx.doi.org/10.9738/CC121.1>.
  8. Evans DT. Actinomyces israelii in the female genital tract: a review. *Genitourin Med*. 1993;69(1):54-9. PMID:8444484.
  9. Wagenlehner FM, Mohren B, Naber KG, Männl HF. Abdominal actinomycosis. *Clin Microbiol Infect*. 2003;9(8):881-5. PMID:14616714. <http://dx.doi.org/10.1046/j.1469-0691.2003.00653.x>.
  10. Desteli GA, Gürsu T, Bircan HY, Kizilkiliç E, Demiralay E, Timurkaynak F. Thrombocytosis and small bowel perforation: Unusual presentation of abdominopelvic actinomycosis. *J Infect Dev Ctries*. 2013;7(12):1012-5. PMID:24334952. <http://dx.doi.org/10.3855/jidc.2837>.
  11. Lee IJ, Ha HK, Park CM, et al. Abdominopelvic actinomycosis involving the gastrointestinal tract: CT features. *Radiology*. 2001;220(1):76-80. PMID:11425976. <http://dx.doi.org/10.1148/radiology.220.1.r01j1376>.
  12. Onal ED, Altinbas A, Onal IK, et al. Successful outpatient management of pelvic actinomycosis by ceftriaxone: a report of three cases. *Braz J Infect Dis*. 2009;13(5):391-3. PMID:20428643. <http://dx.doi.org/10.1590/S1413-86702009000500016>.
  13. Koneman EW, Allen SD, Janda WM. Schreckenberger. In: Winn WC Jr, editors. *Color atlas and textbook of diagnostic microbiology*. 5th ed. Philadelphia: Lippincott-Raven; 1997.
  14. Valour F, Sénéchal A, Dupieux C, et al. Actinomycosis: etiology, clinical features, diagnosis, treatment, and management. *Infect Drug Resist*. 2014;7:183-97. PMID:25045274.
  15. Bonnefond S, Catroux M, Melenotte C, et al. Clinical features of actinomycosis: a retrospective, multicenter study of 28 cases of miscellaneous presentations. *Medicine (Baltimore)*. 2016;95(24):e3923. PMID:27311002. <http://dx.doi.org/10.1097/MD.0000000000003923>.
  16. Valour F, Sénéchal A, Dupieux C, et al. Actinomycosis: etiology, clinical features, diagnosis, treatment, and management. *Infect Drug Resist*. 2014;7:183-97. PMID:25045274.
  17. Ferrari TCA, Couto CA, Murta-Oliveira C, Conceição SA, Silva RG. Actinomycosis of the colon: a rare form of presentation. *Scand J Gastroenterol*. 2000;35(1):108-9. PMID:10672844. <http://dx.doi.org/10.1080/003655200750024623>.
  18. McDermott M, Tanner A, Hourihane D. Abdominal actinomycosis following small intestinal perforation in an umbilical hernia: a case report and review of literature. *Ir J Med Sci*. 1993;162(5):182-3. PMID:8335456. <http://dx.doi.org/10.1007/BF02945181>.
  19. Fesołowicz S, Kwiatkowski A, Chmura A. Actinomycosis associated with perforation of jejunum in patient after cholecystectomy: a case report. *Pol Merkuriusz Lek*. 2010;29:318-9.
  20. Belak J, Vajo J, Boor A, et al. Actinomycosis of the small intestine: an unusual cause of acute abdomen. *Rozhl Chir*. 2001;80(11):602-4. PMID:11794061.
  21. Norwood MGA, Bown MJ, Furness PN, Berry DP. Actinomycosis of the sigmoid colon: an unusual cause of large bowel perforation. *ANZ J Surg*. 2004;74(9):816-8. PMID:15379826. <http://dx.doi.org/10.1111/j.1445-1433.2004.03156.x>.
  22. Jung EY, Choi SN, Park DJ, You JJ, Kim HJ, Chang SH. Abdominal actinomycosis associated with a sigmoid colon perforation in a patient with a ventriculoperitoneal shunt. *Yonsei Med J*. 2006;47(4):583-6. PMID:16941752. <http://dx.doi.org/10.3349/ymj.2006.47.4.583>.
  23. Nunoo-Mensah JW, Joglekar VM, Nasmyth GD, Partridge SM. Abdominal actinomycosis: can early diagnosis prevent extensive surgery? *Int J Clin Pract*. 2010;64(1):106-9. PMID:20089023. <http://dx.doi.org/10.1111/j.1742-1241.2006.00935.x>.
  24. Ikeda SI, Kato T. A case of pelvic actinomycosis unrelated to an intrauterine device. *Jpn J Clin Oncol*. 2012;42(3):237-8. PMID:22375028. <http://dx.doi.org/10.1093/jjco/hys015>.

**Conflict of interest:** None

**Submitted on:** December 5<sup>th</sup>, 2016

**Accepted on:** January 21<sup>st</sup>, 2017

### Correspondence

Linda Ferreira Maximiano

Surgery Division - Hospital Universitário - Universidade de São Paulo (USP)

Avenida Professor Lineu Prestes, 2565 – Butantã/SP – Brasil

CEP: 05508-000

Phone: +55 (11) 3091-9491

[linda@usp.br](mailto:linda@usp.br)