

Rickettsia sibirica mongolitimonae Infections in Spain and Case Review of the Literature

Sonia Santibáñez, José Manuel Ramos-Rincón, Paula Santibáñez, Cristina Cervera-Acedo, Isabel Sanjoaquín, Encarnación Ramírez de Arellano, Sara Guillén, María del Carmen Lozano, Marta Llorente, Mario Puerta-Peña, Elena Aura Bularca, Alejandro González-Praetorius, Isabel Escribano, Lorenzo Sánchez, Valvanera Ibarra, Jorge Alba, Ana M. Palomar, Antonio Beltrán, Aránzazu Portillo, José A. Oteo



In support of improving patient care, this activity has been planned and implemented by Medscape, LLC and Emerging Infectious Diseases. Medscape, LLC is jointly accredited with commendation by the Accreditation Council for Continuing Medical Education (ACCME), the Accreditation Council for Pharmacy Education (ACPE), and the American Nurses Credentialing Center (ANCC), to provide continuing education for the healthcare team.

Medscape, LLC designates this Journal-based CME activity for a maximum of 1.00 **AMA PRA Category 1 Credit(s)**[™]. Physicians should claim only the credit commensurate with the extent of their participation in the activity.

Successful completion of this CME activity, which includes participation in the evaluation component, enables the participant to earn up to 1.0 MOC points in the American Board of Internal Medicine's (ABIM) Maintenance of Certification (MOC) program. Participants will earn MOC points equivalent to the amount of CME credits claimed for the activity. It is the CME activity provider's responsibility to submit participant completion information to ACCME for the purpose of granting ABIM MOC credit.

All other clinicians completing this activity will be issued a certificate of participation. To participate in this journal CME activity: (1) review the learning objectives and author disclosures; (2) study the education content; (3) take the post-test with a 75% minimum passing score and complete the evaluation at https://www.medscape.org/qna/processor/73261?showStandAlone=true&src=prt_jcme_eid_mscpedu; and (4) view/print certificate. For CME questions, see page 215.

NOTE: It is Medscape's policy to avoid the use of Brand names in accredited activities. However, in an effort to be as clear as possible, trade names are used in this activity to distinguish between the mixtures and different tests. It is not meant to promote any particular product.

Release date: December 20, 2024; Expiration date: December 20, 2025

Learning Objectives

Upon completion of this activity, participants will be able to:

- Analyze trends in infection with *Rickettsia sibirica mongolitimonae*
- Assess demographic variables associated with *R. sibirica mongolitimonae* infections
- Evaluate symptoms associated with *R. sibirica mongolitimonae* infections
- Distinguish treatment outcomes of *R. sibirica mongolitimonae* infections

CME Editor

Susan Zunino, PhD, Technical Writer/Editor, Emerging Infectious Diseases. *Disclosure: Susan Zunino, PhD, has no relevant financial relationships.*

CME Author

Charles P. Vega, MD, Health Sciences Clinical Professor of Family Medicine, University of California, Irvine School of Medicine, Irvine, California. *Disclosure: Charles P. Vega, MD, has the following relevant financial relationships: served as a consultant or advisor for Boehringer Ingelheim; GlaxoSmithKline.*

Authors

Sonia Santibáñez, BSc, PhD; José Manuel Ramos-Rincón, MD, PhD, DTM&H; Paula Santibáñez, BSc, PhD; Cristina Cervera-Acedo, BPharm, PhD; Isabel Sanjoaquín, MD, PhD; Encarnación Ramírez de Arellano, MD, PhD; Sara Guillén, MD, PhD; María del Carmen Lozano, MD, PhD; Marta Llorente, MD; Mario Puerta-Peña, MD; Elena Aura Bularca, MD; Alejandro González-Praetorius, MD, PhD; Isabel Escribano, BPharm, PhD; Lorenzo Sánchez, MD; Valvanera Ibarra, MD, PhD; Jorge Alba, MD, PhD; Ana María Palomar, BSc, PhD; Antonio Beltrán, MD, PhD; Aránzazu Portillo, BSc, PhD; José Antonio Oteo, MD, PhD.

Rickettsia sibirica mongolotimonae is an emerging cause of tickborne rickettsiosis. Since the bacterium was first documented as a human pathogen in 1996, a total of 69 patients with this infection have been reported in the literature. Because of the rising rate of *R. sibirica mongolotimonae* infection cases, we evaluated the epidemiologic and clinical features of 29 patients who had *R. sibirica mongolotimonae* infections confirmed during 2007–2024 at the Center for Rickettsiosis and Arthropod-Borne Diseases, the reference laboratory of San Pedro University Hospital–Center for Biomedical Research of La Rioja, Logroño, Spain. We also reviewed all cases published in the literature during 1996–2024, evaluating features of 94 cases of *R. sibirica mongolotimonae* infection (89 in Europe, 4 in Africa, and 1 in Asia). Clinicians should consider *R. sibirica mongolotimonae* as a potential causative agent of rickettsiosis, and doxycycline should be administered promptly to avoid clinical complications.

The bacterium *Rickettsia sibirica mongolotimonae* (formerly *R. mongolotimonae*) has become an emerging cause of tickborne rickettsiosis since the 1990s. *R. sibirica mongolotimonae* was first documented as a human pathogen in France in 1996 in a woman who manifested a febrile rash and a single inoculation eschar on the groin; a rope-like lymphangitis also developed in the patient from the eschar to the draining lymph node (1). Four years later, *R. sibirica mongolotimonae* infection was diagnosed in a second patient, also in France. That patient manifested an inoculation eschar on the leg, fever, and lymphangitis that expanded from the eschar to an enlarged and painful lymph node in the groin (2). The first case reported outside of Europe occurred in South Africa in 2004; a man manifested an inoculation eschar on a toe, fever, headache, and lymphangitis expanding from the eschar to an enlarged inguinal lymph node (3). The first case series of infections, published in 2005, reported 7 new case-patients in France, 1 of whom was a traveler returning from southern Algeria (4). Clinical symptoms in those patients were fever, eschar, rash, and lymphangitis, and because of the lymphangitis symptom, it was named lymphangitis-associated rickettsiosis (4). Since 2005, most cases have been reported

in the Mediterranean area, including France, Greece, Portugal, Spain, Turkey, and North Macedonia (5–10), and in other geographic areas, such as Africa and Asia (11,12). The clinical spectrum of infections has broadened; the bacterium has been shown to cause retinal vasculitis, septic shock, myopericarditis, and encephalitis (13–16). Since 2014, *R. sibirica mongolotimonae* has also been implicated as an etiologic agent of scalp eschar and neck lymphadenopathy after tick bite syndrome (17).

Few case series have been published worldwide (4,8,18); a total of 69 patients with *R. sibirica mongolotimonae* infections have been reported in case series or as isolated cases. Of those 69 patients, >30% (n = 22) were reported in Spain, the first of which was described at the Center for Rickettsiosis and Arthropod-Borne Diseases (CRETAV) in La Rioja, Spain (7). All of those cases were autochthonous. CRETAV, located at the Center for Biomedical Research of La Rioja, is a specialized laboratory and a center of excellence within the Network of Biologic Alert Laboratories that supports research on special pathogens, including those transmitted by ticks and other arthropods. CRETAV is also the reference laboratory for San Pedro University Hospital in La Rioja, receiving samples from other health services throughout the country. Thus, from June 2007 (when the first case was described) (7) through May 2024, *R. sibirica mongolotimonae* infections were confirmed at CRETAV in 29 of 365 patients who had tickborne rickettsioses. Diagnoses in the remaining 336 patients were *Dermacentor*-borne necrosis erythema lymphadenopathy (n = 187), boutonneuse fever (n = 130), African tick bite fever (n = 12, imported cases), and 5 other *Rickettsia* infections: *R. helvetica* (n = 2), *R. massiliae* (n = 2, 1 imported), *R. monacensis* (n = 1), *R. aeschlimannii* (n = 1), and *R. parkeri* (n = 1, imported case). Aware of the rising rate of patients with *R. sibirica mongolotimonae* infections diagnosed at CRETAV since 2020, and because only 4 cases from this 29-case series had been previously reported (7,14,15,19), we described the epidemiologic and clinical features of patients with confirmed *R. sibirica mongolotimonae* infections

Author affiliations: San Pedro University Hospital-Center for Biomedical Research of La Rioja, Logroño, Spain (S. Santibáñez, P. Santibáñez, C. Cervera-Acedo, V. Ibarra, J. Alba, A.M. Palomar, A. Portillo, J.A. Oteo); Dr. Balmis General University Hospital and Institute for Health and Biomedical Research, Alicante, Spain (J.M. Ramos-Rincón); Dr. Balmis General University Hospital, Alicante (I. Escribano); Lozano Blesa University Clinical Hospital, Zaragoza, Spain (I. Sanjoaquín, E.A. Bularca, A. Beltrán); Virgen Macarena University Hospital, Seville, Spain

(E. Ramírez de Arellano); Getafe's University Hospital and Centro de Investigación Biomédica en Red Enfermedades Infecciosas Instituto de Salud Carlos III, Madrid, Spain (S. Guillén); Virgen del Rocío University Hospital, Seville (M.C. Lozano); University Hospital of the Southeast, Madrid (M. Llorente); 12 de Octubre University Hospital, Madrid (M. Puerta-Peña); University General Hospital Guadalajara, Guadalajara, Spain (A. González-Praetorius, L. Sánchez)

DOI: <https://doi.org/10.3201/eid3101.240151>

processed at CRETAV. We also reviewed all published cases because a comprehensive literature review was lacking. We obtained study approval from the regional ethics committee (Comité Ético de Investigación Clínica-Consejería de Sanidad de La Rioja; approval no. CEICLAR PI-37) and informed consent from all patients in this study. All procedures were in accordance with the ethical standards of the research committee and with the 1964 Helsinki declaration and its later amendments.

Patients and Methods

Infections Diagnosed at CRETAV

Patients were asked about medical antecedents during their clinical interview, and variables, including epidemiologic data, were written down in their medical chart. In those cases in which relevant information was not recorded, patients were called later and asked for those data. For children, information was confirmed by their parents.

We defined a diagnosis of *R. sibirica mongolitimonae* infection on the basis of clinical suspicion (fever with or without rash, with or without eschar, and with or without lymphangitis) and positive PCR and sequencing results in patients with a history of tick bite or tick exposure. During June 2007–May 2024, cases were confirmed at CRETAV by using EDTA-blood samples, eschar biopsies, eschar swab samples, and tick samples from patients who were investigated at CRETAV because of clinical or epidemiologic suspicion of rickettsiosis. CRETAV diagnosed infections by using PCR of *ompA* and *ompB* genes corresponding to *R. sibirica mongolitimonae*. We subsequently reviewed clinical data of patients who had positive *ompA* and *ompB* PCR results for *R. sibirica mongolitimonae*.

Using molecular methods as described (20), we had previously extracted DNA from clinical samples from the Zoonosis Collection registered in the National Registry of Biobanks from Carlos III Health Institute

(reference no. C.0006409), located at CRETAV–Centre of Biomedical Research of La Rioja. Whenever possible, we tested both acute phase and convalescent serum samples (collected 4–12 weeks apart), or only acute serum samples if the second sample was not available, by using immunofluorescence assays (IFA) to detect cross-reacting *R. conorii* IgG (CRETAV in-house assay or commercial assay [Vircell Microbiologists]).

Literature Review

We performed a systematic review of the literature by searching PubMed using the search terms “sibirica” or “mongolitimonae” or “mongolotimonae” and “*Rickettsia*” and a date range of January 1996–May 2024. We excluded nonhuman studies. We included human case reports and case series only if *R. sibirica mongolitimonae* infections were confirmed by either PCR and sequencing, except for 1 case, which was confirmed by indirect IFA and showed *R. sibirica mongolitimonae* IgG seroconversion.

Results

***R. sibirica mongolitimonae* Infection Cases Diagnosed at CRETAV**

Tickborne rickettsiosis caused by *R. sibirica mongolitimonae* was confirmed in 29 (7.9%) of 365 patients during 2007–2024. The number of *R. sibirica mongolitimonae* infections compared with the total number of tickborne *Rickettsia* spp. infections increased from 12.5% to 41.7% during 2020–2023 (Figure 1). Twenty-three (79.3%) of 29 patients were men, 6 (20.7%) women. The mean age was 58 (range 5–82) years; the median age was 67 years. Three (10.3%) patients were <15 years of age. All patients sought medical care during March–September of each year: 1 in March, 3 in April, 5 in May, 7 in June, 4 in July, 2 in August, and 7 in September (Figure 2).

Only 6 (20.7%) patients remembered a tick bite, 1 had an attached tick, and 11 recalled tick exposure

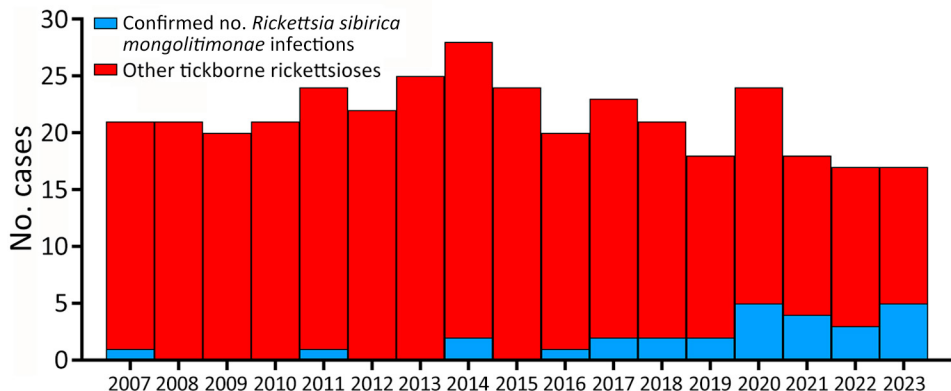


Figure 1. Number of confirmed rickettsioses cases in study of *Rickettsia sibirica mongolitimonae* infections in Spain. Numbers of patients with a confirmed case of *R. sibirica mongolitimonae* infection and total numbers of other tickborne rickettsioses are indicated for each year during 2007–2023. Cases were diagnosed at the Center for Rickettsiosis and Arthropod-Borne Diseases, La Rioja, Spain.

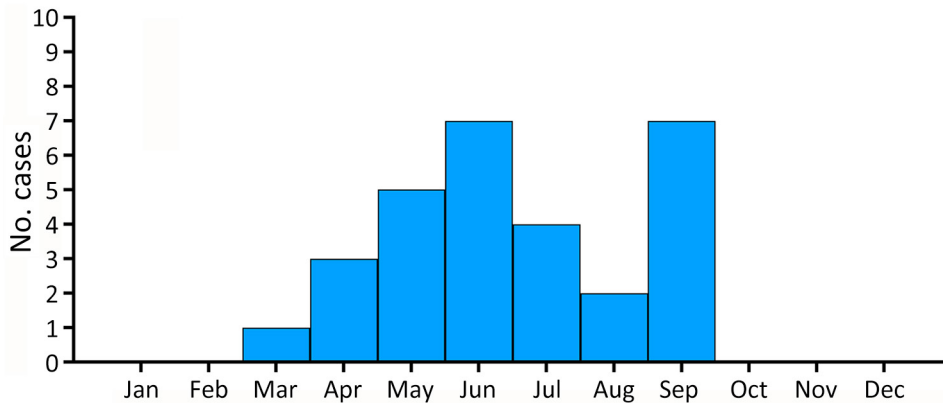


Figure 2. Monthly prevalence of *Rickettsia sibirica mongolitimonae* infections in Spain during 2007–May 2024. Patients sought medical care for *R. sibirica mongolitimonae* infections during March–September of each year.

from hunting, gardening, living in a rural environment, or contact with dogs that had ticks. Patients resided in different regions in Spain: Aragón (n = 8), La Rioja (n = 8), Comunidad Valenciana (n = 4), Andalucía (n = 3), Madrid (n = 3), Vizcaya (n = 2), and Castilla-La Mancha (n = 1). The place of residence was within the same geographic region of the tick bite or exposure for all patients, even for those who did not recall activities associated with tick contact (n = 11) but denied recent travel outside of their residential region.

Symptoms at disease onset included fever (dysthermia, fever detected by thermometer) for all patients (Appendix Table 1, <https://wwwnc.cdc.gov/EID/article/31/1/24-0151-App1.pdf>). Inoculation eschars manifested in 27/29 (93.1%) patients as single (n = 20 [69.0%]) or multiple (n = 7 [24.1%]) eschars. They were located on lower limbs (n = 9 patients) (Figure 3), upper limbs (n = 7) (Figure 4), head (n = 3), hips (n = 3), buttocks (n = 3), groin (n = 2), abdomen (n = 2) (Figure 5, panel A), iliac fossa (n = 1) (Figure 5, panel B), and scrotum (n = 1) (19). A rope-like lymphangitis from the eschar to the draining lymph node was detected in 10/29 (34.5%) patients (Figure 3), and a generalized maculopapular rash was observed in 14/29 (48.3%) patients. One patient experienced septic shock and myopericarditis developed in another patient who had no remarkable medical history (14,15).

Hematologic and biochemical parameters were missing for several patients. When available, laboratory investigations showed leukopenia, thrombocytopenia, and raised lactate dehydrogenase, C-reactive protein, and liver enzymes (alanine aminotransferase, aspartate aminotransferase, and gamma glutamyl transaminase) as main findings.

We administered doxycycline (100 mg 2×/d for 10–14 days) to 26 patients, whereas 3 patients (2 children <15 years of age and 1 pregnant woman) received azithromycin (10 mg/kg 1×/d for 5 days

for the children and 500 mg/kg 1×/d for 5 days for the adult). We observed improvement of signs and symptoms in all cases. We added supportive therapy with fluids and inotropic agents and intravenous meropenem (1 g every 8 hours) and vancomycin (1 g every 12 hours) for the patient who had septic shock.

For microbiologic tests, 1 clinical sample was available for 22/29 patients: EDTA-blood sample (n = 4), eschar biopsy (n = 5), and eschar swab sample (n = 12) (Appendix Table 1). For 1 patient, the only available clinical sample was the attached tick, which was identified as a *Rhipicephalus pusillus*. The remaining 7 patients had 2 different clinical samples available: eschar biopsy and eschar swab samples (n = 4), eschar

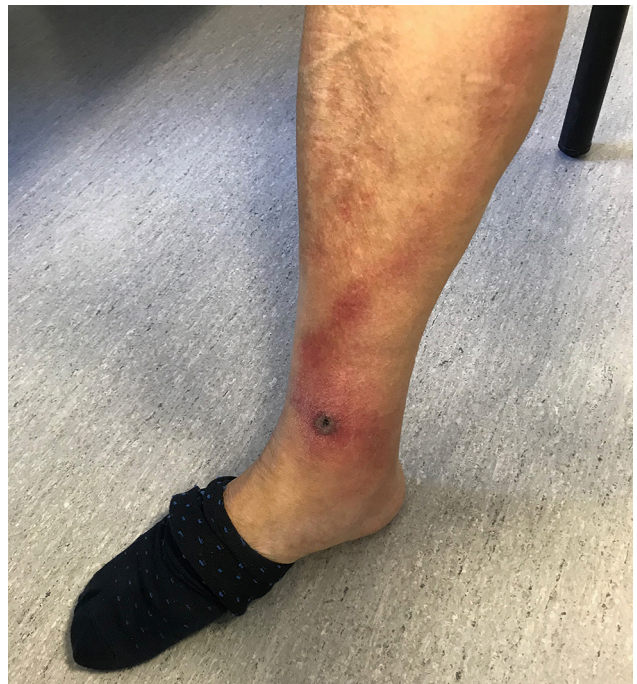

Figure 3. Eschar from *Rickettsia sibirica mongolitimonae* infection located on lower limb of patient in Spain.

swab and EDTA-blood samples (n = 2), and eschar biopsy and EDTA-blood sample (n = 1).

The *ompA* and *ompB* gene sequences obtained from 7 blood samples, 7 eschars, 18 eschar swab samples, and the *R. pusillus* tick showed the 100% similarity to those genes from *R. sibirica mongolitimoniae* (GenBank accession no. MF379309 for *ompA* and JQ782657 for *ompB*). Acute- and convalescent-phase serum samples were obtained from 7 of 29 patients (Appendix Table 1). For 6 of those samples, we observed seroconversion (n = 5) or a 4-fold increase in titer (n = 1). We did not detect IgG against spotted fever group (SFG) *Rickettsia* in either serum sample for the remaining patient. For 6 patients, only acute serum samples were available; 2 of those showed IgG titers against SPG *Rickettsia* and 4 did not react. No serum specimens were available for the remaining patients (Appendix Table 1).

In July 2023, *ompA* and *ompB* genes from *R. sibirica mongolitimoniae* (100% identity) were amplified by PCR in 1 *R. pusillus* tick attached to a 70-year-old patient. Five days after removing the tick, he had a high fever (39°C); an eschar at the armpit appeared 1 day later. No lymphangitis, lymphadenopathies, or rash were observed. No EDTA-blood, eschar biopsy, or eschar swab samples were available from that patient. He was treated with doxycycline and recovered.

Published *R. sibirica mongolitimoniae* Infection Cases, Including This Study

We found, reviewed, and extracted data from the full text of 26 selected papers from PubMed. Ninety-four cases of *R. sibirica mongolitimoniae* infection were reported worldwide during January 1996–May 2024, including the 29 cases from this study; 89 of those cases were reported in Europe: Spain (n = 47), France (n = 36), Greece (n = 2), Portugal (n = 2), Turkey (n = 1), and Macedonia (n = 1) (Appendix Table 2). Only 4 cases have been published in Africa, including South Africa (unique case occurred in southern hemisphere),

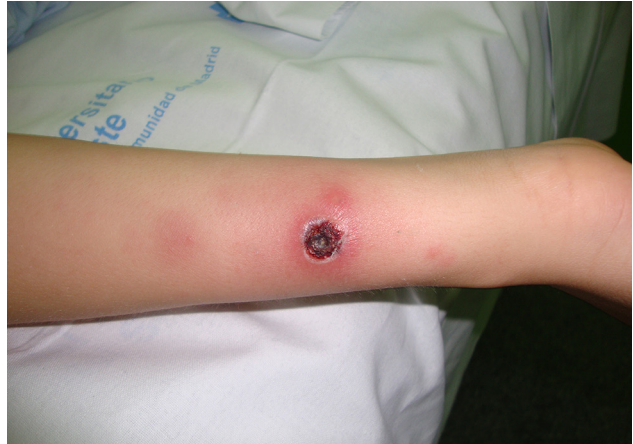

Figure 4. Eschar from *Rickettsia sibirica mongolitimoniae* infection located on upper limb of a pediatric patient in Spain.

Algeria, Egypt and Cameroon, and 1 in Asia (Sri Lanka) (Appendix Table 2).

Of the total number of patients described, 67.0% were men and 31.9% women. The mean age was 49.8 (range 4–82) years; the median age was 55.5 years. Most (n = 77) infection cases occurred during April–July and in September of each year. Only ≈33% of patients remembered a tick bite. Four patients kept the ticks (1 tick/person), which were identified as female *Hyalomma marginatum*, *H. anatolicum excavatum*, *Hyalomma* sp., and *R. pusillus* ticks (5,9,10). The symptoms at disease onset (always after tick removal) included fever for all patients; ≈95% of patients manifested inoculation eschars, and 14 patients had multiple eschars. Eschars were located on lower limbs (n = 28), upper limbs (n = 18), trunk (n = 18), head (n = 15), hip (n = 4) and iliac fossa (n = 1), groin (n = 3), scrotum (n = 2), and buttocks (n = 3) (Figure 6). A rope-like lymphangitis from the eschar to the draining lymph node was noted in 33 (35.1%) of 94 published cases (Figure 3); a generalized maculopapular rash was observed in 66.7% of cases.

In published cases, *R. sibirica mongolitimoniae* genes were amplified by PCR in 43 eschar biopsy specimens, 38 eschar swab samples, 12 blood samples, and 3 ticks

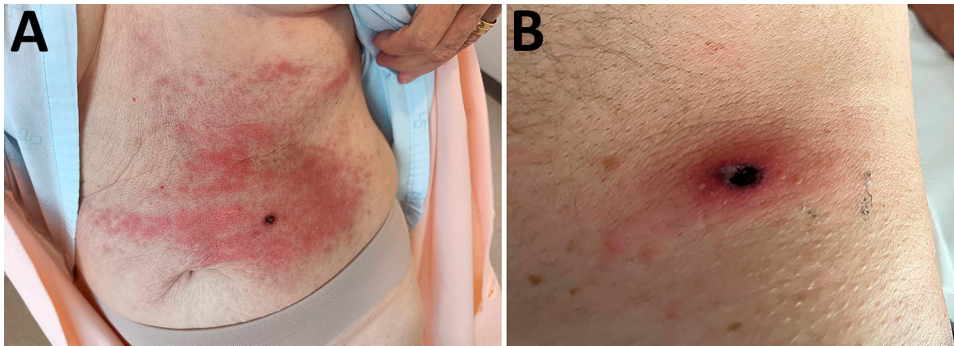


Figure 5. Eschars from *Rickettsia sibirica mongolitimoniae* infections of 2 patients in Spain, located on the abdomen of 1 patient (A) and on the iliac fossa of another patient (B).

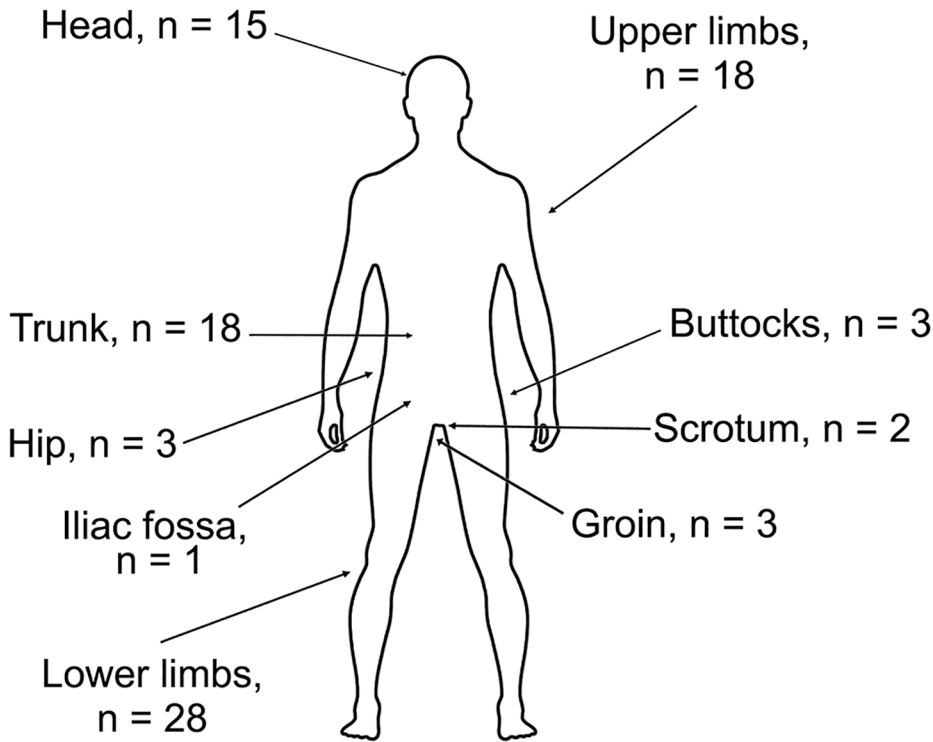


Figure 6. Numbers and body locations of tick bites and inoculation eschars in patients with *Rickettsia sibirica mongolitimonae* infections during 2007–2024, Spain, and from published literature. Patients manifested single or multiple eschars. Cases were diagnosed at the Center for Rickettsiosis and Arthropod-Borne Diseases, La Rioja, Spain and/or identified in PubMed.

(*H. anatolicum excavatum*, *H. marginatum*, and *R. pusillus*) removed from infected patients. Ten patients had >1 PCR-positive clinical sample: eschar biopsy and eschar swab sample (n = 5), eschar biopsy and blood sample (n = 2), eschar swab and blood samples (n = 2), and blood sample and a tick specimen (n = 1). Most (91.9%) patients were treated with doxycycline for 7–14 days, and all patients recovered without sequelae after antimicrobial drug treatment.

Discussion

We describe the epidemiologic and clinical characteristics of *R. sibirica mongolitimonae* infections in 29 patients who had their infection confirmed at CRETAV in Spain during 2007–2024, and we reviewed all available cases published in the literature during January 1996–May 2024. *R. sibirica mongolitimonae* has been considered a rare pathogen. Nevertheless, this bacterium has been the causative agent of ≥94 rickettsiosis cases since 1996, including the case series described in this study, mostly in the Mediterranean area. This infection typically manifests with high fever, myalgia and headache, single or multiple inoculation eschars with a nondefined inflammatory halo, nonpruritic maculopapular rash involving palms and soles, and enlarged draining lymph nodes. Lymphangitis is a typical sign of this infection and occurs in ≈40% of infected patients. Lymphangitis might occur in other

rickettsioses, such as those caused by *R. heilongjiangensis* and *R. africae*, although in lesser proportions. Thus, in Europe, the presence of lymphangitis should suggest *R. sibirica mongolitimonae* infection (21). In this study, 10 (34.5%) of the 29 patients with *R. sibirica mongolitimonae* infections diagnosed at CRETAV had lymphangitis, a slightly higher percentage than that shown in a previous report from France in 2016 (18); a rope-like lymphangitis from the eschar to the draining lymph node was observed in 33/94 (35.1%) cases published worldwide. Fever was present in 100% of published cases; a generalized maculopapular rash was observed in 14 (48.3%) of 29 patients with infections confirmed at CRETAV, whereas 67.0% of patients described in published cases had the rash. Inoculation eschars were noted in 27 (93.1%) of 29 patients with infections confirmed at CRETAV and in 89 (94.7%) patients from published cases. Multiple inoculation eschars developed in 13 (13.8%) patients in published cases; a higher (24.1%) percentage was found in CRETAV cases. The presence of multiple inoculation eschars is common in patients with African tick bite fever (22).

R. sibirica mongolitimonae infection frequently causes a mild, nonlethal disease, but some complications have been described, such as septic shock, disseminated intravascular coagulation, neurologic disorders, acute renal failure, and myopericarditis (13–16,23). In

2020, a case of *R. sibirica mongolitimonae* infection with associated encephalitis was reported (16).

All outcomes, including for severe cases, were successful after antimicrobial drug administration. Doxycycline is the drug of choice for treating rickettsioses, even for children <8 years of age (24). Macrolides, such as azithromycin, are effective against rickettsial diseases and can be safely used during pregnancy. The early start of empirical treatment reduces severity and duration of symptoms (25). For published cases, oral doxycycline (100 mg/12 hours for 7–15 days) was administered to all patients, except 4 who received azithromycin (1 man, 1 pregnant woman, and 2 children 4 and 6 years of age). One patient received pristinamycin for 7 days.

In accordance with previously published reports, we found that *R. sibirica mongolitimonae* infections were seasonal and most cases occurred during the spring and summer (April–July) and in September. The infections affected men more frequently than women. In our case series, 23 (79.3%) patients were men and 6 (20.7%) were women, compared with 67.0% men and 31.9% women in published cases. The mean age was 58 years in the case series and 50 years in the published cases.

R. sibirica mongolitimonae infections are likely underdiagnosed or misdiagnosed as another rickettsiosis because diagnosis is mainly made according to serologic testing, which includes IFAs. Serology is limited by cross-reactions with other *Rickettsia* spp., mostly among SFG *Rickettsia* spp. because they share antigenic characteristics. Using molecular tools, such as PCR and quantitative PCR-based methods, on skin biopsy (eschar) and eschar swab samples appear to be the best methods to detect and identify *R. sibirica mongolitimonae*. For molecular diagnosis, eschar swab samples are preferred over skin biopsies because the sampling procedure is noninvasive and highly effective (26–28). Culture as a diagnostic method is fastidious and performed only in reference laboratories. Nevertheless, 6 eschar biopsies were positive for *R. sibirica mongolitimonae* by culture methods in published cases (1,2,4,6).

R. sibirica mongolitimonae was initially isolated from *H. asiaticum* ticks in Inner Mongolia (29) and from *H. truncatum* ticks in Niger (30). In Europe, *R. sibirica mongolitimonae* was detected in *H. excavatum* ticks in Greece and Cyprus, in *H. marginatum* ticks in Spain (31,32), in *R. pusillus* ticks in Portugal, Spain and France (6,31,33), and in *R. bursa* ticks in Spain (34). In Turkey, it was also detected in *R. bursa*, *Haemaphysalis parva*, *H. excavatum*, and *H. marginatum* ticks (35).

In 2005, the presence of *R. sibirica mongolitimonae* was reported both in a patient and in a *H. anaticum excavatum* tick removed from that patient in Greece (5). In 2016, in Turkey, *R. sibirica mongolitimonae* infection was diagnosed by PCR in a man who had been bitten by a *H. marginatum* tick (9). A case of *R. sibirica mongolitimonae* infection after a *Hyalomma* sp. tick bite has been recently reported in North Macedonia (10). No ticks were associated with the remaining published cases, and many patients did not even remember receiving a tick bite. Nevertheless, because *R. sibirica mongolitimonae* has been detected in *Rhipicephalus* spp. ticks collected from areas close to where infected patients lived (6,33), *Rhipicephalus* ticks are also suspected vectors in Europe.

In published cases, only 18 (19.1%) of 94 patients remembered a tick bite. Four patients kept the ticks, which were identified as *H. marginatum*, *H. anaticum excavatum*, *Hyalomma* sp., and *R. pusillus*; *R. sibirica mongolitimonae* was amplified in 3 of those ticks. *R. sibirica mongolitimonae* has been most frequently associated with *Hyalomma* ticks, the confirmed vectors in Africa. However, adult *Hyalomma* spp. ticks are large, but most patients did not remember a tick bite. This finding suggests that either the *Hyalomma* spp. vector is at an immature stage, which is rare because few bites occur from *Hyalomma* larvae and nymphs, or the vector could also be *R. pusillus*, which is a small tick found in rabbits. Data from case number 93 (Appendix Table 2), obtained from this case series, strengthen the potential role of *R. pusillus* ticks as *R. sibirica mongolitimonae* vectors. Under a One Health perspective, excessive reproduction of rabbits in urban/perurban areas of cities might cause human cases of *R. sibirica mongolitimonae* infection.

In Europe, *R. sibirica mongolitimonae* was confirmed as a human pathogen in 1996, and 94 cases have been reported during 1996–2024. During 1996–2012, only 25 cases were published, whereas during 2013–2024, the number of published cases reached 70. This upward trend of reports might be partly caused by the use of new tools to investigate tick-transmitted agents. In addition, warming weather and the overgrowth of certain wildlife species, among other factors, are involved in the increase in tick threats. Thus, the expansion of wild boar and rabbit populations might favor an increase in adult tick species responsible for *R. sibirica mongolitimonae* transmission. *Hyalomma* spp. ticks are characterized by their aggressive host-seeking behavior, unlike other tick species that use a passive ambush strategy as they wait in vegetation. Although *Hyalomma* ticks are not particularly anthropophilic, a progressive increase in their population has been reported in

Spain and other areas in Europe, probably related to factors previously mentioned.

A strength of this study lies in the large number of clinical cases in Spain that were evaluated, accompanied by a literature review. However, it is possible that not all case data in Spain were collected because, despite the bibliographic search, *R. sibirica mongolitimonae* infections diagnosed in patients at other centers might not have been reported.

In conclusion, when rickettsiosis is clinically suspected, clinicians should be aware that empiric therapy should not wait for microbiologic confirmation. Doxycycline must be administered promptly, even in children, to avoid clinical complications. The rapid identification of *Rickettsia* spp. by using molecular techniques to analyze swab samples from inoculation eschars should be systematized. Because of the broad clinical spectrum of *R. sibirica mongolitimonae* infections, this emerging rickettsiosis is likely underdiagnosed or misdiagnosed as another SFG rickettsiosis. Clinicians should consider *R. sibirica mongolitimonae* as a potential causative agent in patients who have fever and an eschar or rash with or without lymphangitis and should consider the epidemiologic context.

Acknowledgments

We thank Nerea González Romero for her contribution to this case series.

About the Author

Dr. Santibáñez is a researcher at the Center of Rickettsiosis and Arthropod-Borne Diseases, Infectious Diseases Department, San Pedro University Hospital–Center for Biomedical Research of La Rioja, in Logroño, Spain. Her research interests focus on the optimization of diagnostic techniques for arthropod-borne diseases and the isolation of implicated fastidious microorganisms.

References

1. Raoult D, Brouqui P, Roux V. A new spotted-fever-group rickettsiosis. *Lancet*. 1996;348:412. [https://doi.org/10.1016/S0140-6736\(05\)65037-4](https://doi.org/10.1016/S0140-6736(05)65037-4)
2. Fournier PE, Tissot-Dupont H, Gallais H, Raoult DR. *Rickettsia mongolitimonae*: a rare pathogen in France. *Emerg Infect Dis*. 2000;6:290–2. <https://doi.org/10.3201/eid0603.000309>
3. Pretorius AM, Birtles RJ. *Rickettsia mongolitimonae* infection in South Africa. *Emerg Infect Dis*. 2004;10:125–6. <https://doi.org/10.3201/eid1001.020662>
4. Fournier PE, Gouriet F, Brouqui P, Lucht F, Raoult D. Lymphangitis-associated rickettsiosis, a new rickettsiosis caused by *Rickettsia sibirica mongolitimonae*: seven new cases and review of the literature. *Clin Infect Dis*. 2005;40:1435–44. <https://doi.org/10.1086/429625>
5. Psaroulaki A, Germanakis A, Gikas A, Scoulica E, Tselentis Y. Simultaneous detection of *Rickettsia mongolitimonae* in a patient and in a tick in Greece. *J Clin Microbiol*. 2005;43:3558–9. <https://doi.org/10.1128/JCM.43.7.3558-3559.2005>
6. de Sousa R, Barata C, Vitorino L, Santos-Silva M, Carrapato C, Torgal J, et al. *Rickettsia sibirica* isolation from a patient and detection in ticks, Portugal. *Emerg Infect Dis*. 2006;12:1103–8. <https://doi.org/10.3201/eid1207.051494>
7. Aguirrebengoa K, Portillo A, Santibáñez S, Marín JJ, Montejo M, Oteo JA. Human *Rickettsia sibirica mongolitimonae* infection, Spain. *Emerg Infect Dis*. 2008;14:528–9. <https://doi.org/10.3201/eid1403.070987>
8. Ramos JM, Jado I, Padilla S, Masiá M, Anda P, Gutiérrez F. Human infection with *Rickettsia sibirica mongolitimonae*, Spain, 2007–2011. *Emerg Infect Dis*. 2013;19:267–9. <https://doi.org/10.3201/eid1902.111706>
9. Kuscü F, Orkun O, Ulu A, Kurtaran B, Komur S, Inal AS, et al. *Rickettsia sibirica mongolitimonae* infection, Turkey, 2016. *Emerg Infect Dis*. 2017;23:1214–6. <https://doi.org/10.3201/eid2307.170188>
10. Jakimovski D, Mateska S, Simin V, Bogdan I, Mijatović D, Estrada-Peña A, et al. Mediterranean spotted fever-like illness caused by *Rickettsia sibirica mongolitimonae*, North Macedonia, June 2022. *Euro Surveill*. 2022;27:2200735. <https://doi.org/10.2807/1560-7917.ES.2022.27.42.2200735>
11. Cordier C, Tattevin P, Leyer C, Cailleaux M, Raoult D, Angelakis E. *Rickettsia sibirica mongolitimonae* infection, Sri Lanka. *J Infect Dev Ctries*. 2017;11:668–71. <https://doi.org/10.3855/jidc.8743>
12. Nouchi A, Monsel G, Jaspard M, Jannic A, Angelakis E, Caumes E. *Rickettsia sibirica mongolitimonae* infection in a woman travelling from Cameroon: a case report and review of the literature. *J Travel Med*. 2018;25. <https://doi.org/10.1093/jtm/tax074>
13. Caron J, Rolain JM, Mura F, Guillot B, Raoult D, Bessis D. *Rickettsia sibirica* subsp. *mongolitimonae* infection and retinal vasculitis. *Emerg Infect Dis*. 2008;14:683–4. <https://doi.org/10.3201/eid1404.070859>
14. Ibarra V, Portillo A, Palomar AM, Sanz MM, Metola L, Blanco JR, et al. Septic shock in a patient infected with *Rickettsia sibirica mongolitimonae*, Spain. *Clin Microbiol Infect*. 2012;18:E283–5. <https://doi.org/10.1111/j.1469-0691.2012.03887.x>
15. Revilla-Martí P, Cecilio-Irazola Á, Gayán-Ordás J, Sanjoaquín-Conde I, Linares-Vicente JA, Oteo JA. Acute myopericarditis associated with tickborne *Rickettsia sibirica mongolitimonae*. *Emerg Infect Dis*. 2017;23:2091–3. <https://doi.org/10.3201/eid2312.170293>
16. Loarte MDC, Melenotte C, Cassir N, Cammilleri S, Dory-Lautrec P, Raoult D, et al. *Rickettsia mongolitimonae* encephalitis, southern France, 2018. *Emerg Infect Dis*. 2020;26:362–4. <https://doi.org/10.3201/eid2602.181667>
17. Dubourg G, Socolovschi C, Del Giudice P, Fournier PE, Raoult D. Scalp eschar and neck lymphadenopathy after tick bite: an emerging syndrome with multiple causes. *Eur J Clin Microbiol Infect Dis*. 2014;33:1449–56. <https://doi.org/10.1007/s10096-014-2090-2>
18. Angelakis E, Richet H, Raoult D. *Rickettsia sibirica mongolitimonae* infection, France, 2010–2014. *Emerg Infect Dis*. 2016;22:880–2. <https://doi.org/10.3201/eid2205.141989>
19. Salazar Alarcón E, Guillén-Martín S, Callejas-Caballero I, Valero-Arenas A. Clinical case report: not all rickettsiosis are mediterranean spotted fever. *Enferm Infecc Microbiol Clin (Engl Ed)*. 2022;40:44–5. <https://doi.org/10.1016/j.eimce.2021.10.004>

20. Santibáñez S, Portillo A, Ibarra V, Santibáñez P, Metola L, García-García C, et al. Epidemiological, clinical, and microbiological characteristics in a large series of patients affected by *Dermacentor*-borne-necrosis-erythema-lymphadenopathy from a unique centre from Spain. *Pathogens*. 2022;11:528. <https://doi.org/10.3390/pathogens11050528>
21. Faccini-Martínez ÁA, García-Álvarez L, Hidalgo M, Oteo JA. Syndromic classification of rickettsioses: an approach for clinical practice. *Int J Infect Dis*. 2014;28:126–39. <https://doi.org/10.1016/j.ijid.2014.05.025>
22. Althaus F, Greub G, Raoult D, Genton B. African tick-bite fever: a new entity in the differential diagnosis of multiple eschars in travelers. Description of five cases imported from South Africa to Switzerland. *Int J Infect Dis*. 2010;14:e274–6. <https://doi.org/10.1016/j.ijid.2009.11.021>
23. Gaillard E, Socolovschi C, Fourcade C, Lavigne JP, Raoult D, Sotto A. A case of severe sepsis with disseminated intravascular coagulation during *Rickettsia sibirica mongolitimonae* infection [in French]. *Med Mal Infect*. 2015;45:57–9. <https://doi.org/10.1016/j.medmal.2014.10.005>
24. Todd SR, Dahlgren FS, Traeger MS, Beltrán-Aguilar ED, Marianos DW, Hamilton C, et al. No visible dental staining in children treated with doxycycline for suspected Rocky Mountain spotted fever. *J Pediatr*. 2015;166:1246–51. <https://doi.org/10.1016/j.jpeds.2015.02.015>
25. Brouqui P, Bacellar F, Baranton G, Birtles RJ, Bjoërsdorff A, Blanco JR, et al.; ESCMID Study Group on Coxiella, Anaplasma, Rickettsia and Bartonella; European Network for Surveillance of Tick-Borne Diseases. Guidelines for the diagnosis of tick-borne bacterial diseases in Europe. *Clin Microbiol Infect*. 2004;10:1108–32. <https://doi.org/10.1111/j.1469-0691.2004.01019.x>
26. Solary J, Socolovschi C, Aubry C, Brouqui P, Raoult D, Parola P. Detection of *Rickettsia sibirica mongolitimonae* by using cutaneous swab samples and quantitative PCR. *Emerg Infect Dis*. 2014;20:716–8. <https://doi.org/10.3201/eid2004.130575>
27. Wang JM, Hudson BJ, Watts MR, Karagiannis T, Fisher NJ, Anderson C, et al. Diagnosis of Queensland tick typhus and African tick bite fever by PCR of lesion swabs. *Emerg Infect Dis*. 2009;15:963–5. <https://doi.org/10.3201/eid1506.080855>
28. Bechah Y, Socolovschi C, Raoult D. Identification of rickettsial infections by using cutaneous swab specimens and PCR. *Emerg Infect Dis*. 2011;17:83–6. <https://doi.org/10.3201/eid1701.100854>
29. Yu X, Jin Y, Fan M, Xu G, Liu Q, Raoult D. Genotypic and antigenic identification of two new strains of spotted fever group rickettsiae isolated from China. *J Clin Microbiol*. 1993;31:83–8. <https://doi.org/10.1128/jcm.31.1.83-88.1993>
30. Parola P, Inokuma H, Camicas JL, Brouqui P, Raoult D. Detection and identification of spotted fever group rickettsiae and ehrlichiae in African ticks. *Emerg Infect Dis*. 2001;7:1014–7. <https://doi.org/10.3201/eid0706.010616>
31. Fernández de Mera IG, Ruiz-Fons F, de la Fuente G, Mangold AJ, Gortázar C, de la Fuente J. Spotted fever group rickettsiae in questing ticks, central Spain. *Emerg Infect Dis*. 2013;19:1163–5. <https://doi.org/10.3201/eid1907.130005>
32. Palomar AM, Portillo A, Mazuelas D, Roncero L, Arizaga J, Crespo A, et al. Molecular analysis of Crimean-Congo hemorrhagic fever virus and *Rickettsia* in *Hyalomma marginatum* ticks removed from patients (Spain) and birds (Spain and Morocco), 2009–2015. *Ticks Tick Borne Dis*. 2016;7:983–7. <https://doi.org/10.1016/j.ttbdis.2016.05.004>
33. Edouard S, Parola P, Socolovschi C, Davoust B, La Scola B, Raoult D. Clustered cases of *Rickettsia sibirica mongolitimonae* infection, France. *Emerg Infect Dis*. 2013;19:337–8. <https://doi.org/10.3201/eid1902.120863>
34. Toledo A, Olmeda AS, Escudero R, Jado I, Valcárcel F, Casado-Nistal MA, et al. Tick-borne zoonotic bacteria in ticks collected from central Spain. *Am J Trop Med Hyg*. 2009;81:67–74. <https://doi.org/10.4269/ajtmh.2009.81.67>
35. Keskin A, Bursali A, Keskin A, Tekin S. Molecular detection of spotted fever group rickettsiae in ticks removed from humans in Turkey. *Ticks Tick Borne Dis*. 2016;7:951–3. <https://doi.org/10.1016/j.ttbdis.2016.04.015>

Address for correspondence: Aránzazu Portillo, San Pedro University Hospital–Center for Biomedical Research of La Rioja (HOSP-CIBIR), Infectious Diseases Department, Center of Rickettsiosis and Arthropod-Borne Diseases (CRETAV), Piqueras, 98 26006, Logroño, La Rioja, Spain; email: aportillo@riojasalud.es

Article DOI: <https://doi.org/10.3201/eid3101.240151>

EID cannot ensure accessibility for supplementary materials supplied by authors. Readers who have difficulty accessing supplementary content should contact the authors for assistance.

Rickettsia sibirica mongolitimonae Infections in Spain and Case Review of the Literature

Appendix

Appendix Table 1. Detailed data about patients with *R. sibirica mongolitimonae* infections confirmed at the Center for Rickettsiosis and Arthropod-Borne Diseases (CRETAV) in Rioja, Spain, during 2007–2024

Case no. (ref)	Year	Bite/eschar location	No. eschars	Fever	Rash	Lymphangitis	Hospitalized	Available clinical samples	PCR+ sample	DNA amplicon size, bp*		IgG titers†, acute/conalescent
										<i>ompA</i>	<i>ompB</i>	
1 (1)	2007	Leg	None	Yes	No	No	No	Blood	Blood	486	382	Negative/negative
2 (2)	2011	Hip	1	Yes	Yes	No	Yes	Blood	Blood	486	381	Negative/1:512
3	2014	Forearm	1	Yes	Yes	Yes	Yes	Eschar swab	Eschar swab	503	359	No serum
4	2014	Groin	1	Yes	No	No	No	Eschar swab	Eschar swab	484	453	1:128/1:2,048
5 (3)	2016	Buttocks	1	Yes	No	No	Yes	Blood, eschar, eschar swab	Eschar, eschar swab	481	464	Negative/1:1,024
6	2017	Scalp	2	Yes	No	No	No	Blood, eschar swab	Blood, eschar swab	491	359	1:1,024/no serum
7	2017	Foot	1	Yes	No	Yes	Yes	Eschar swab	Eschar swab	491	382	Negative/no serum
8	2018	Forearm	1	Yes	No	No	No	Eschar swab	Eschar swab	515	464	No serum
9	2018	Shoulder	2	Yes	Yes	No	Yes	Eschar, eschar swab	Eschar, eschar swab	481	464	No serum
10	2019	Scapula/leg	2	Yes	No	No	No	Eschar swab	Eschar swab	484	453	No serum
11	2019	Leg	2	Yes	No	No	Yes	Eschar swab	Eschar swab	491	382	No serum
12	2020	Leg	2	Yes	Yes	Yes	Yes	Blood, eschar swab	Eschar swab	461	453	Negative/1:64
13 (4)	2020	Scrotum	1	Yes	Yes	No	Yes	Eschar	Eschar	491	464	No serum
14	2020	Scalp	1	Yes	Yes	Yes	No	Eschar swab	Eschar swab	486	452	Negative/no serum
15	2020	Ankle	1	Yes	Yes	Yes	Yes	Eschar swab	Eschar swab	491	464	No serum
16	2020	Thigh	1	Yes	Yes	No	No	Blood	Blood	486	382	Negative/no serum
17	2021	Thigh/hip	1	Yes	No	No	No	Eschar swab	Eschar swab	491	464	1:64/no serum
18	2021	Buttocks	1	Yes	Yes	Yes	Yes	Blood, eschar	Eschar	491	464	No serum
19	2021	Unknown	None	Yes	Yes	No	Yes	Blood	Blood	481	380	Negative/1:1,024
20	2021	Arm	2	Yes	Yes	No	Yes	Blood, eschar	Blood, eschar	481	464	No serum
21	2022	Hip	1	Yes	Yes	No	No	Blood, eschar, eschar swab	Eschar and eschar swab	491	382	No serum
22	2022	Face	1	Yes	No	No	No	Eschar swab	Eschar swab	491	382	No serum
23	2022	Arm	1	Yes	No	Yes	Yes	Eschar swab	Eschar swab	491	464	No serum
24	2023	Leg	1	Yes	No	Yes	Yes	Eschar swab	Eschar swab	491	464	No serum

Case no. (ref)	Year	Bite/eschar location	No. eschars	Fever	Rash	Lymphangitis	Hospitalized	Available clinical samples	PCR+ sample	DNA amplicon size, bp*		IgG titers†, acute/convalescent
										ompA	ompB	
25	2023	Abdomen/ groin	2	Yes	Yes	No	Yes	Eschar swab	Eschar swab	472	464	No serum
26	2023	Iliac fossa	1	Yes	No	No	Yes	Blood, eschar swab	Blood and eschar swab	481	464	Negative/1:1,024
27	2023	Abdomen	1	Yes	Yes	No	Yes	Eschar swab	Eschar swab	491	464	No serum
28	2023	Armpit	1	Yes	No	No	No	Tick	Tick	491	464	No serum
29	2024	Buttocks	1	Yes	No	No	No	Eschar swab	Eschar swab	491	459	Negative/no serum

*All PCR amplicons of *ompA* and *ompB* genes showed 100% identity with those of *Rickettsia sibirica mongolitimonae*. bp, base pairs; ref, reference; +, positive.
†IgG titers determined for acute and convalescent serum samples by using immunofluorescence assays.

Appendix Table 2. Epidemiologic, clinical, and microbiologic characteristics associated with patients infected with *Rickettsia sibirica mongolitimonae**

Case no.	Country	Year case occurred/publication	Patient age, y/sex	Tick bite reported	Other epidemiologic condition	Month†	Bite/eschar locations	No. eschars	Fever	Rash	Lymphangitis	PCR+ sample	Ref.
2	France	1998/2000	49/M	No	Gardener, living in rural area	May	Leg	1	Yes	No	Yes	Eschar	(6)
3	South Africa	2002/2004	34/M	No	Working in area with <i>Hyalomma truncatum</i>	September	Toe, foot	1	Yes	No	Yes	Eschar	(7)
4	France	2000–2004/2005	53/M	Yes	Gardening	May	Knee	1	Yes	Yes	No	Eschar	(8)
5	France	2000–2004/2005	40/F	Yes	Gardening	July	None	None	Yes	Yes	Yes	Serum	(8)
6	France	2000–2004/2005	59/M	Yes	Gardening	April	Back	1	Yes	Yes	No	Eschar	(8)
7	France	2000–2004/2005	21/F	No	Gardening	May	Heel	1	Yes	No	Yes	Serum	(8)
8	France	2000–2004/2005	70/M	No	Gardening, contact with birds	May	Forearm/ abdomen	2	Yes	Yes	No	Eschar	(8)
9	France	2000–2004/2005	55/M	No	Walk in Camargue National Park	June	Arm	1	Yes	Yes	Yes	Eschar	(8)
10	France, return from Algeria	2000–2004/2005	62/F	No	Travel to southern Algeria	April	Foot, hypochondrium	2	Yes	Yes	No	Eschar, serum	(8)
11	Crete	2002/2005	76/M	Yes, <i>H. anaticum excavatum</i>	Collecting olives	December	Scrotum	None	Yes	Yes	No	Blood, tick	(9)
12	Portugal	2004/2006	73/F	No	None	August	Toe	1	Yes	Yes	No	Blood culture	(10)
13	France	2005/2008	20/F	No	Walking	June	Face	1	Yes	Yes	No	Eschar	(11)
14	Portugal	2006/2008	44/M	No	Vacation	August	Forearm	1	Yes	Yes	Yes	Eschar	(12)
15	Spain	2007/2008	41/M	Yes, tick removed	Topographer	June	Leg	None	Yes	No	No	Blood	(1)
16	Spain	2007/2013	67/F	No	Gardening	July	Scalp	1	Yes	Yes	No	Eschar	(13)
17	Spain	2009/2013	32/M	No	Working at golf courses	September	Thigh	1	Yes	Yes	Yes	Eschar	(13)
18	Spain	2010/2013	33/M	No	Walking in rural area	April	Leg	1	Yes	No	Yes	Eschar	(13)

Case no.	Country	Year case occurred/publication	Patient age, y/sex	Tick bite reported	Other epidemiologic condition	Month†	Bite/eschar locations	No. eschars	Fever	Rash	Lymphangitis	PCR+ sample	Ref.
19	Spain	2011/2013	42/F	No	Walking in rural area	March	Shoulder	1	Yes	No	No	Eschar	(13)
20	Spain	2011/2013	40/F	Yes	Horseback riding	April	Neck	1	Yes	Yes	No	Eschar	(13)
21	Spain	2011/2013	75/F	No	Walking in rural area	July	Leg	1	Yes	Yes	Yes	Eschar	(13)
22	France	2009/2010	52/M	No	Trip to Egypt	September	Scapular area	1	Yes	No	No	Eschar	(14)
23	Spain	NA/2011	9/M	No	Rural environment	September /October	Scalp	1	Yes	No	No	Eschar	(15)
24	Spain	NA/2011	73/M	Yes	Working in vegetable patch	August	Back	1	Yes	Yes	No	Eschar	(16)
25	Spain	2011/2012	69/M	No	Vacation in rural area	September	Hip	1	Yes	Yes	No	Blood	(2)
26	France	2011/2013	73/M	No	Contact with animals	February	Armpit	1	Yes	Yes	No	NA	(17)
27	France	2011/2013	67/F	No	Contact with animals	April	Leg	1	Yes	No	Yes	NA	(17)
28	France	2011/2013	NA/M	No	Contact with animals	March	NA	1	Yes	NA	NA	NA	(17)
29	France	2012/2014	16/M	No	Fishing	May	Lower eyelid, forearm	2	Yes	No	No	Eschar swab	(18)
30–49	France	2010–2014/2016	Median age (\pm SD) 43 (\pm 21) [IQR 2–70]; F, n = 8; M, n = 12	No, n = 14; Yes, n = 6	Tick bites or handling, n = 6; outdoor activities, n = 5; frequent contact with dogs, n = 8	April–June, n = 11; July–September, n = 8; October, n = 1	Lower limbs, n = 7; upper limbs, n = 4; trunk, n = 3; neck, n = 4	\geq 1, n = 20; Multiple, n = 3	Yes	Yes, n = 19; no, n = 1	Yes, n = 7; no, n = 13	Eschar swab, n = 13; skin biopsy, n = 10	(19)
50	France	2013/2015	61/M	Yes	Insect bite	June	Forearm	1	Yes	Yes	No	Eschar	(20)
51	North Greece	2013/2016	13/M	No	Holidays, walking to the woods	May	Upper chest,	1	Yes	Yes	Yes	None‡	(21)
52	Spain	2014/NP	12/M	No	None	May	Forearm	1	Yes	Yes	Yes	Eschar swab	NP
53	Spain	2014/NP	71/M	No	None	July	Groin	1	Yes	No	No	Eschar swab	NP
54	Spain	NA/2015	46/F	No	Dog with ticks	May	Scalp	1	Yes	Yes	No	Eschar	(22)
55	Spain	NA/2015	73/M	No	Rural environment and hunting	July	Abdomen	1	Yes	Yes	No	Eschar	(23)
56	Spain	NA/2015	25/M	Yes	Dog with ticks	July	Trunk	1	Yes	No	No	Eschar	(23)
57	Spain	2013–2014/2016	6/NA	NA	NA	NA	Scalp	1	Yes	Yes	No	Eschar	(24)
58	France, returned from Sri Lanka	2016/2017	30/F	Yes	Jungle	February	Flank	1	Yes	Yes	No	Eschar	(25)
59	Spain	2016/2017	39/M	No	Hunting	September	Buttocks	1	Yes	No	No	Eschar, eschar swab	(3)

Case no.	Country	Year case occurred/publication	Patient age, y/sex	Tick bite reported	Other epidemiologic condition	Month†	Bite/eschar locations	No. eschars	Fever	Rash	Lymphangitis	PCR+ sample	Ref.
60	Turkey	2016/2017	56/M	Yes, <i>H. marginatum</i> female	Farming	May	Umbilicus	1	Yes	Yes	No	Tick	(26)
61	France	2016/2018	42/F	No	Gardening	July	Abdominal	2	Yes	No	No	Eschar swab	(27)
62	Spain	2017/NP	76/F	No	Living with dogs	June	Scalp	2	Yes	No	No	Eschar swab, blood	NP
63	Spain	2017/NP	66/M	No	Hunting	September	Foot	1	Yes	No	Yes	Eschar swab	NP
64	Cameroon	NA/2017	54/F	No	Travel	May	Back	1	Yes	Yes	No	Eschar swab, eschar	(28)
65	Spain	2018/NP	39/M	No	Rural environment	August	Forearm	1	Yes	No	No	Eschar swab	NP
66	Spain	2018/NP	70/M	No	None	September	Shoulder	2	Yes	Yes	No	Eschar swab, eschar	NP
67	France	2018/2020	66/M	No	Living in rural area with animals	July	Ankle	1	Yes	Yes	Yes	Eschar swab	(29)
68	Spain	2019/NP	50/F	No	None	May	Leg/scapula	2	Yes	No	No	Eschar swab	NP
69	Spain	2019/NP	61/M	No	None	September	Leg	2	Yes	No	Yes	Eschar swab	NP
70	Spain	2020/NP	82/M	Yes	4 ticks attached	May	Leg	2	Yes	Yes	Yes	Eschar swab	NP
71	Spain	2019/2020	59/M	No	Rural area and contact with animals	April	Leg	1	Yes	No	Yes	Eschar	(30)
72	Spain	2020/2021	11/M	No	Walking with dog	July	Forearm	1	Yes	Yes	Yes	Eschar	(31)
73	Spain	2020/2021	5/M	Yes	Rural area and dog with ticks	June	Scrotum	1	Yes	Yes	No	Eschar	(4)
74	Spain	2020/NP	12/F	No	None	August	Scalp	1	Yes	Yes	Yes	Eschar swab	NP
75	Spain	2020/NP	75/M	No	None	September	Ankle	1	Yes	Yes	Yes	Eschar swab	NP
76	Spain	2020/NP	34/M	No	Hunting	June	Thigh	1	Yes	Yes	No	Blood	NP
77	Spain	2021/NP	34/M	Yes	Tick bite	April	Thigh/hip	1	Yes	No	No	Eschar swab	NP
78	Spain	2021/NP	70/M	No	None	June	Buttocks	1	Yes	Yes	Yes	Eschar	NP
79	Spain	2021/NP	66/M	Yes	Tick bite	June	Unknown	None	Yes	Yes	No	Blood	NP
80	Spain	2021/NP	74/M	No	None	June	Arm	2	Yes	Yes	No	Eschar, blood	NP
81	Spain	2022/NP	65/M	No	None	March	Hip	1	Yes	Yes	No	Eschar, eschar swab	NP

Case no.	Country	Year case occurred/publication	Patient age, y/sex	Tick bite reported	Other epidemiologic condition	Month†	Bite/eschar locations	No. eschars	Fever	Rash	Lymphangitis	PCR+ sample	Ref.
82	Spain	2022/NP	78/F	No	Rural environment	April	Face	1	Yes	No	No	Eschar swab	NP
83	Spain	2022/NP	52/M	No	Cat scratch	May	Arm	1	Yes	No	Yes	Eschar swab	NP
84	Spain	NA/2022	4/M	NA	NA	NA	Thigh	1	Yes	No	Yes	Eschar	(32)
85	Spain	NA/2022	6/M	No	None	NA	Scalp	2	Yes	No	No	Eschar	(33)
86	North Macedonia	2022/2022	60/F	<i>Hyalomma</i> sp.	Living in rural area	June	Armpit	1	Yes	Yes	No	Blood	(34)
87	Spain	2021/2023	29/M	Insect bite	Holidays in rural area	June	Forearm	1	Yes	No	Yes	Eschar	(35)
88	Spain	NA/2023	75/M	No	Living in rural area	NA	Neck	1	Yes	Yes	No	Eschar	(36)
89	Spain	2023/NP	57/M	Yes	Tick bite	May	Leg	1	Yes	No	Yes	Eschar swab	NP
90	Spain	2023/NP	74/M	Yes	Tick bite	July	Abdomen/groin	2	Yes	Yes	No	Eschar swab	NP
91	Spain	2023/NP	68/M	No	Vegetable patch	July	Iliac fossa	1	Yes	No	No	Eschar swab, blood	NP
92	Spain	2023/NP	69/F	No	Gardening	September	Abdomen	1	Yes	Yes	No	Eschar swab	NP
93	Spain	2023/NP	70/M	Yes, <i>R. pusillus</i>	Gardening	July	Armpit	1	Yes	No	No	Tick attached	NP
94	Spain	2024/NP	46/F	No	None	April	Buttocks	1	Yes	No	No	Eschar	NP

*Bold text indicates cases not previously published. Data are from patients with *R. sibirica mongolitimonae* infection diagnosed at the Center for Rickettsiosis and Arthropod-Borne Diseases in Rioja, Spain, during 2007–2024 and from literature published in PubMed during 1996–2024. NA, not available; NP, not published; Ref, reference; *R. pusillus*, *Rhipicephalus pusillus* tick; +, positive.

†Month patients were bitten or month of symptom onset.

‡Microbiologic diagnosis by seroconversion.

References

1. Aguirrebengoa K, Portillo A, Santibáñez S, Marín JJ, Montejo M, Oteo JA. Human *Rickettsia sibirica mongolitimonae* infection, Spain. *Emerg Infect Dis.* 2008;14:528–9. [PubMed https://doi.org/10.3201/eid1403.070987](https://doi.org/10.3201/eid1403.070987)
2. Ibarra V, Portillo A, Palomar AM, Sanz MM, Metola L, Blanco JR, et al. Septic shock in a patient infected with *Rickettsia sibirica mongolitimonae*, Spain. *Clin Microbiol Infect.* 2012;18:E283–5. [PubMed https://doi.org/10.1111/j.1469-0691.2012.03887.x](https://doi.org/10.1111/j.1469-0691.2012.03887.x)
3. Revilla-Martí P, Cecilio-Irazola Á, Gayán-Ordás J, Sanjoaquín-Conde I, Linares-Vicente JA, Oteo JA. Acute myopericarditis associated with tickborne *Rickettsia sibirica mongolitimonae*. *Emerg Infect Dis.* 2017;23:2091–3. [PubMed https://doi.org/10.3201/eid2312.170293](https://doi.org/10.3201/eid2312.170293)

4. Salazar Alarcón E, Guillén-Martín S, Callejas-Caballero I, Valero-Arenas A. Clinical case report: not all rickettsiosis are mediterranean spotted fever. *Enferm Infecc Microbiol Clin (Engl Ed)*. 2022;40:44–5. [PubMed https://doi.org/10.1016/j.eimce.2021.10.004](https://doi.org/10.1016/j.eimce.2021.10.004)
5. Raoult D, Brouqui P, Roux V. A new spotted-fever-group rickettsiosis. *Lancet*. 1996;348:412. [PubMed https://doi.org/10.1016/S0140-6736\(05\)65037-4](https://doi.org/10.1016/S0140-6736(05)65037-4)
6. Fournier PE, Tissot-Dupont H, Gallais H, Raoult DR. *Rickettsia mongolotimonae*: a rare pathogen in France. *Emerg Infect Dis*. 2000;6:290–2. [PubMed https://doi.org/10.3201/eid0603.000309](https://doi.org/10.3201/eid0603.000309)
7. Pretorius AM, Birtles RJ. *Rickettsia mongolotimonae* infection in South Africa. *Emerg Infect Dis*. 2004;10:125–6. [PubMed https://doi.org/10.3201/eid1001.020662](https://doi.org/10.3201/eid1001.020662)
8. Fournier PE, Gouriet F, Brouqui P, Lucht F, Raoult D. Lymphangitis-associated rickettsiosis, a new rickettsiosis caused by *Rickettsia sibirica mongolotimonae*: seven new cases and review of the literature. *Clin Infect Dis*. 2005;40:1435–44. [PubMed https://doi.org/10.1086/429625](https://doi.org/10.1086/429625)
9. Psaroulaki A, Germanakis A, Gikas A, Scoulica E, Tselentis Y. Simultaneous detection of *Rickettsia mongolotimonae* in a patient and in a tick in Greece. *J Clin Microbiol*. 2005;43:3558–9. [PubMed https://doi.org/10.1128/JCM.43.7.3558-3559.2005](https://doi.org/10.1128/JCM.43.7.3558-3559.2005)
10. de Sousa R, Barata C, Vitorino L, Santos-Silva M, Carrapato C, Torgal J, et al. *Rickettsia sibirica* isolation from a patient and detection in ticks, Portugal. *Emerg Infect Dis*. 2006;12:1103–8. [PubMed https://doi.org/10.3201/eid1207.051494](https://doi.org/10.3201/eid1207.051494)
11. Caron J, Rolain JM, Mura F, Guillot B, Raoult D, Bessis D. *Rickettsia sibirica* subsp. *mongolotimonae* infection and retinal vasculitis. *Emerg Infect Dis*. 2008;14:683–4. [PubMed https://doi.org/10.3201/eid1404.070859](https://doi.org/10.3201/eid1404.070859)
12. de Sousa R, Duque L, Anes M, Poças J, Torgal J, Bacellar F, et al. Lymphangitis in a Portuguese patient infected with *Rickettsia sibirica*. *Emerg Infect Dis*. 2008;14:529–30. [PubMed https://doi.org/10.3201/eid1403.070680](https://doi.org/10.3201/eid1403.070680)
13. Ramos JM, Jado I, Padilla S, Masiá M, Anda P, Gutiérrez F. Human infection with *Rickettsia sibirica mongolotimonae*, Spain, 2007–2011. *Emerg Infect Dis*. 2013;19:267–9. [PubMed https://doi.org/10.3201/eid1902.111706](https://doi.org/10.3201/eid1902.111706)

14. Socolovschi C, Barbarot S, Lefebvre M, Parola P, Raoult D. *Rickettsia sibirica mongolitimonae* in traveler from Egypt. *Emerg Infect Dis*. 2010;16:1495–6. [PubMed https://doi.org/10.3201/eid1609.100258](https://doi.org/10.3201/eid1609.100258)
15. Morales V, Garcia Acebes CR, Miguelez Hernandez AP, Alfageme Roldan F, Rodriguez Albarran A, Alins Sahun Y, et al. Infección por *Rickettsia sibirica* subsp. *monogolitimonae*. [*Rickettsia sibirica* subsp. *mongolitimonae* infection]. *Piel. Formación continuada en dermatología*. 2011;26:224–6. <https://doi.org/10.1016/j.piel.2011.01.005>
16. Fleta-Asín B, Alonso-Castro L, Jado-García I, Anda-Fernández P. Detection by polymerase chain reaction of *Rickettsia sibirica mongolotimonae* in the skin biopsy of a rash: a case report [in Spanish]. *Enferm Infecc Microbiol Clin*. 2011;29:778–9. [PubMed https://doi.org/10.1016/j.eimc.2011.05.011](https://doi.org/10.1016/j.eimc.2011.05.011)
17. Edouard S, Parola P, Socolovschi C, Davoust B, La Scola B, Raoult D. Clustered cases of *Rickettsia sibirica mongolitimonae* infection, France. *Emerg Infect Dis*. 2013;19:337–8. [PubMed https://doi.org/10.3201/eid1902.120863](https://doi.org/10.3201/eid1902.120863)
18. Solary J, Socolovschi C, Aubry C, Brouqui P, Raoult D, Parola P. Detection of *Rickettsia sibirica mongolitimonae* by using cutaneous swab samples and quantitative PCR. *Emerg Infect Dis*. 2014;20:716–8. [PubMed https://doi.org/10.3201/eid2004.130575](https://doi.org/10.3201/eid2004.130575)
19. Angelakis E, Richet H, Raoult D. *Rickettsia sibirica mongolitimonae* infection, France, 2010–2014. *Emerg Infect Dis*. 2016;22:880–2. [PubMed https://doi.org/10.3201/eid2205.141989](https://doi.org/10.3201/eid2205.141989)
20. Gaillard E, Socolovschi C, Fourcade C, Lavigne JP, Raoult D, Sotto A. A case of severe sepsis with disseminated intravascular coagulation during *Rickettsia sibirica mongolitimonae* infection [in French]. *Med Mal Infect*. 2015;45:57–9. [PubMed https://doi.org/10.1016/j.medmal.2014.10.005](https://doi.org/10.1016/j.medmal.2014.10.005)
21. Chochlakakis D, Mantadakis E, Thomaidis S, Tselenti Y, Chatzimichael A, Psaroulaki A. First human case of *Rickettsia sibirica mongolotimonae* infection in northern Greece. *Isr Med Assoc J*. 2016;18:544–6. [PubMed https://doi.org/10.1016/j.isrmed.2016.05.005](https://doi.org/10.1016/j.isrmed.2016.05.005)

22. Nogueras MM, Roson B, Lario S, Sanfeliu I, Pons I, Anton E, et al. Coinfection with *Rickettsia sibirica* subsp. *mongolotimonae* and *Rickettsia conorii* in a human patient: a challenge for molecular diagnosis tools. J Clin Microbiol. 2015;53:3057–62. [PubMed](#) <https://doi.org/10.1128/JCM.00457-15>
23. Pulido-Pérez A, Gómez-Recuero L, Lozano-Masdemont B, Suárez-Fernández R. *Rickettsia sibirica mongolotimonae* infection in two immunocompetent adults [in Spanish]. Enferm Infecc Microbiol Clin. 2015;33:635–6. [PubMed](#) <https://doi.org/10.1016/j.eimc.2015.03.006>
24. Monterde-Álvarez ML, Calbet-Ferré C, Rius-Gordillo N, Pujol-Bajador I, Ballester-Bastardie F, Escribano-Subías J. Rickettsiosis after tick bite: a subtle clinic picture on many occasions, we must be vigilant [in Spanish]. Enferm Infecc Microbiol Clin. 2017;35:100–3. [PubMed](#) <https://doi.org/10.1016/j.eimc.2016.01.013>
25. Cordier C, Tattevin P, Leyer C, Cailleaux M, Raoult D, Angelakis E. *Rickettsia sibirica mongolotimonae* infection, Sri Lanka. J Infect Dev Ctries. 2017;11:668–71. [PubMed](#) <https://doi.org/10.3855/jidc.8743>
26. Kuscu F, Orkun O, Ulu A, Kurtaran B, Komur S, Inal AS, et al. *Rickettsia sibirica mongolotimonae* infection, Turkey, 2016. Emerg Infect Dis. 2017;23:1214–6. [PubMed](#) <https://doi.org/10.3201/eid2307.170188>
27. Rajoelison P, Mediannikov O, Javelle E, Raoult D, Parola P, Aoun O. *Rickettsia sibirica mongolotimonae* human infection: a diagnostic challenge. Travel Med Infect Dis. 2018;26:72–3. [PubMed](#) <https://doi.org/10.1016/j.tmaid.2018.07.002>
28. Nouchi A, Monsel G, Jaspard M, Jannic A, Angelakis E, Caumes E. *Rickettsia sibirica mongolotimonae* infection in a woman travelling from Cameroon: a case report and review of the literature. J Travel Med. 2018;25. [PubMed](#) <https://doi.org/10.1093/jtm/tax074>
29. Loarte MDC, Melenotte C, Cassir N, Cammilleri S, Dory-Lautrec P, Raoult D, et al. *Rickettsia mongolotimonae* encephalitis, southern France, 2018. Emerg Infect Dis. 2020;26:362–4. [PubMed](#) <https://doi.org/10.3201/eid2602.181667>
30. Miguélez Ferreiro S, Navalpotro Rodríguez D. Tubular acute lymphangitis caused by *Rickettsia sibirica mongolotimonae*. Enferm Infecc Microbiol Clin (Engl Ed). 2020;38:506–7. [PubMed](#) <https://doi.org/10.1016/j.eimce.2020.10.001>

31. Echevarría-Zubero R, Porrás-López E, Campelo-Gutiérrez C, Rivas-Crespo JC, Lucas AM, Cobo-Vázquez E. Lymphangitis-associated rickettsiosis by *Rickettsia sibirica mongolitimonae*. J Pediatric Infect Dis Soc. 2021;10:797–9. [PubMed](#)
<https://doi.org/10.1093/jpids/piab018>
32. Vázquez-Pérez Á, Rodríguez-Granger J, Calatrava-Hernández E, Santos-Pérez JL. Pediatric tubular acute lymphangitis caused by *Rickettsia sibirica mongolitimonae*: case report and literature review. Enferm Infecc Microbiol Clin (Engl Ed). 2022;40:218–9. [PubMed](#)
<https://doi.org/10.1016/j.eimce.2021.10.007>
33. Cemeli Cano M, Rodríguez Sanz L, Vidal Lana P, Arlabán Carpintero L, Laliena Aznar S, Jiménez Pérez E. Fiebre botonosa mediterránea “like” por *Rickettsia sibirica mongolitimonae* en la consulta de atención primaria. Rev Latin Infect Pediatr. 2022;35:122–4.
<https://doi.org/10.35366/108136>
34. Jakimovski D, Mateska S, Simin V, Bogdan I, Mijatović D, Estrada-Peña A, et al. Mediterranean spotted fever-like illness caused by *Rickettsia sibirica mongolitimonae*, North Macedonia, June 2022. Euro Surveill. 2022;27:2200735. [PubMed](#) <https://doi.org/10.2807/1560-7917.ES.2022.27.42.2200735>
35. Davila-Arias S, Rabadan-Rubio E, Rabadan-Rubio A, Arranz-Caso JA. *Rickettsia sibirica mongolitimonae* infection in Cantabria, Spain. Enferm Infecc Microbiol Clin (Engl Ed). 2023;41:520–1. [PubMed](#) <https://doi.org/10.1016/j.eimce.2023.04.001>
36. Lasierra Lavilla I, Caballero Castro JP, Zabala López SI. *Rickettsia sibirica* infection. Med Clin (Barc). 2023;160:460–1. [PubMed](#)
<https://doi.org/10.1016/j.medcli.2022.12.012>