

## Possible New Focus of Diphyllbothriasis, Central Europe

Tomáš Scholz,<sup>1</sup> Roman Kuchta,<sup>1</sup> Jan Brabec

Author affiliation: Institute of Parasitology, Biology Centre of the Czech Academy of Sciences, České Budějovice, Czech Republic

DOI: <https://doi.org/10.3201/eid3012.241330>

Diphyllbothriasis is a human parasitic infection that is widespread in the Northern Hemisphere. Popular sport fish such as pike and perch are the source of human infection. We document the autochthonous origin of diphyllbothriasis in a popular tourist destination in Central Europe, which likely marks recent colonization of the parasite.

In contrast to most human parasitic infections, which occur mainly in tropical and subtropical regions that have lower standards of hygiene and less economic development, diphyllbothriasis (also known as dibothriocephalosis) is more common in temperate and cold latitudes. The disease, which is caused by the human broad tapeworm (*Dibothriocephalus latus*), is particularly prevalent in the Northern Hemisphere. The source of infection is the consumption of popular sport fish, such as pike and perch (1–4).

There are 4 main foci of diphyllbothriasis in Europe: Fennoscandia; Baltic region; the Alpine lakes; the Danube region; and certain areas in Russia (Figure). The number of cases decreased drastically after World War II (4). Today, only small foci remain, mainly in the Alpine lakes of northern Italy, Switzerland, and France, where diphyllbothriasis continues to circulate (4,5).

With the exception of a few imported cases, no cases of human diphyllbothriasis or of fish infected with parasite larvae have been reported in Central Europe (Czech Republic and neighboring countries such as Austria, Hungary, and eastern Germany), although the fish parasites have been intensively studied for over a century (4,6,7). In 2024, however, an autochthonous case of diphyllbothriasis caused by *D. latus* was documented in the Czech Republic.

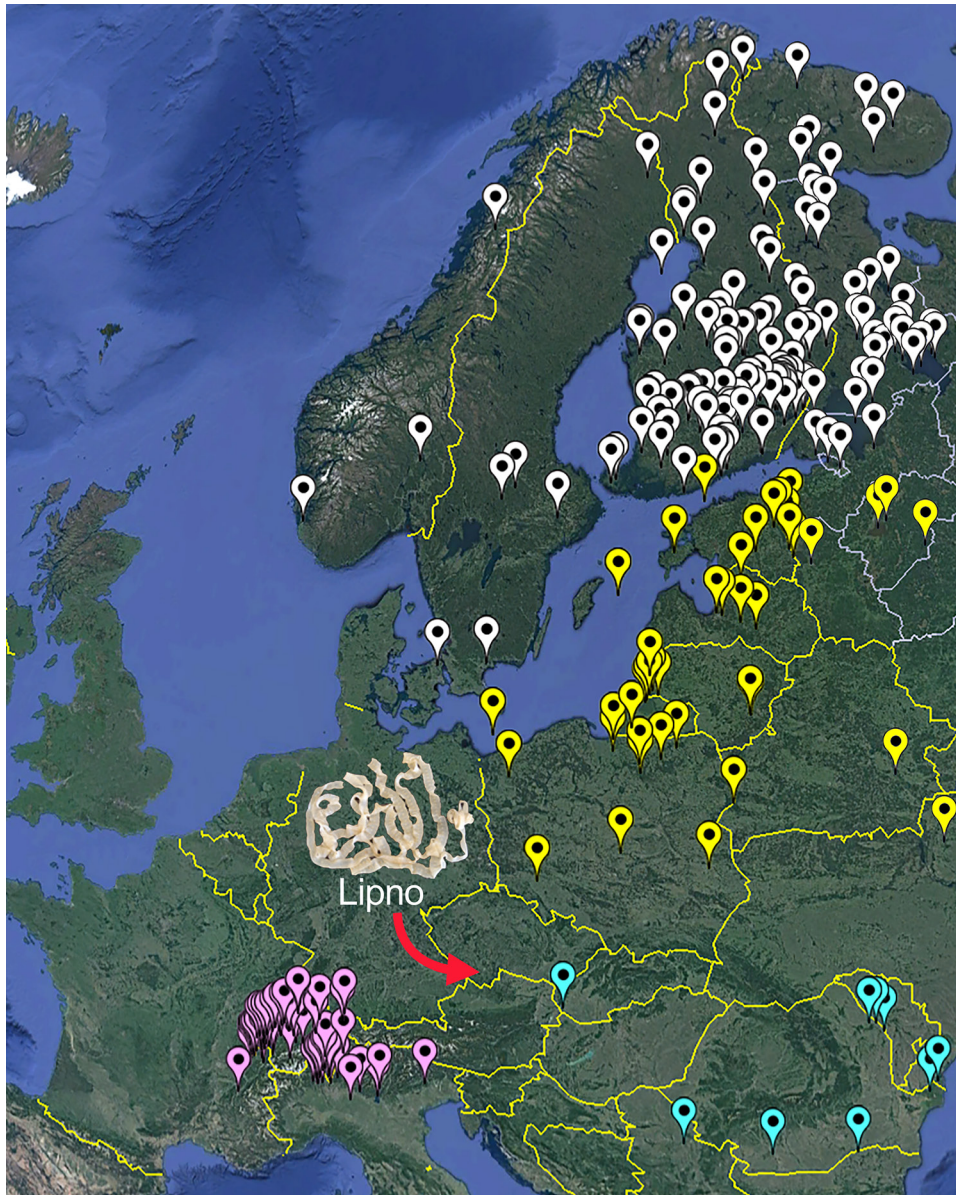
A 37-year-old man, who had not traveled to known diphyllbothriasis-endemic areas and had not previously consumed raw or undercooked fish or fish products, obtained a pike (*Esox lucius*)

caught in October 2023 near Horní Planá, the largest settlement on the Lipno reservoir (48.7 km<sup>2</sup>) in South Bohemia, Czech Republic (Figure). He consumed ≈1 teaspoon of raw salted roe (caviar) from the pike, which is the most common source of diphyllbothriasis in many parts of Russia (8). Two months later, he experienced occasional abdominal bloating. After another 2 months, he expelled a piece of tapeworm with dozens of proglottids. A coprologic examination confirmed the presence of the typical diphyllbothriid eggs. Treatment with mebendazole (Vermox, 6 tablets) (Johnson & Johnson, <https://www.jnj.com>) was unsuccessful, but the tapeworm was later completely expelled after a single dose of praziquantel (Biltricide) (Bayer, <https://www.bayer.com>). Sequencing of the complete mitochondrial cytochrome *c* oxidase subunit I gene (*cox1*) from the eggs (GenBank accession no. PQ270068) confirmed the species identity as *D. latus*. Because the patient could not have been infected elsewhere and his symptoms appeared after eating the pike roe, considering his infection as an autochthonous case of diphyllbothriasis is reasonable. Furthermore, raw products from fish that serve as second intermediate hosts for the human broad tapeworm (i.e., pike, perch, or ruffe) are not imported into the Czech Republic.

The Lipno Reservoir is a popular year-round tourist destination in the Czech Republic, attracting hundreds of thousands of visitors every year, including many local and foreign anglers. The fish parasites in that reservoir were intensively studied in the 1960s after the construction and filling of the reservoir (9). However, *D. latus* has never been found in Central Europe, apart from a single case in the 1960s in an angler from southwestern Slovakia who consumed raw perch from the Danube (4,6,10) (Figure). A presumably autochthonous, unpublished but molecularly identified (*cox1*; GenBank accession no. PQ270069) case from 2014 involved a 43-year-old angler from the Czech Republic who had consumed pike from northeastern and southern Bohemia, Czech Republic (as in this case) and had not traveled to diphyllbothriasis-endemic areas.

Given the intensive study of the reservoir and the popularity of the area, the parasite going undetected for decades seems unlikely. The reservoir has also never been stocked with fish imported from abroad, such as pike, perch, or ruffe, so it is unlikely that the tapeworm was imported from diphyllbothriasis-endemic areas through

<sup>1</sup>These authors contributed equally to this article.



**Figure.** Map of the distribution of *Diphyllobothrium latum* in Europe according to Králová-Hromadová et al. (4) and Kuchta et al. (8). Diphyllbothriasis-endemic areas in Europe are identified by different colors: white indicates Fennoscandia, yellow indicates Baltic region, purple indicates Alpine lake region, and turquoise indicates Danube region. Red arrow indicates the newly reported case from the Czech Republic.

fish. During the examination of 108 potential second intermediate hosts (10 pike [including the pike whose eggs caused the human infection], 53 perch, and 54 ruffe) from the Lipno Reservoir in May and August 2024, no plerocercoids of *D. latum* have been found. However, the prevalence of the fish infection might be low even in other known foci of diphyllbothriasis (5). Therefore, a plausible explanation for the possibly autochthonous occurrence of *D. latum* in Central Europe is a recent appearance of the parasite in this ecosystem, probably introduced by tourists from a diphyllbothriasis-endemic area, such as the lake regions of northwestern Russia (8).

### Acknowledgments

We thank the editor and a reviewer for their helpful suggestions.

This study was supported by the Ministry of Education, Youth and Sports (project LUASK 22045).

### About the Author

Dr. Scholz is a senior researcher at the Institute of Parasitology, Biology Centre of the Czech Academy of Sciences in České Budějovice, Czech Republic. He deals with fish parasites and the systematics, diversity, phylogeny, and life cycles of helminths, especially tapeworms (Cestoda) and trematodes (Digenea).

## References

- Dick T. Diphyllbothriasis: the *Diphyllbothrium latum* human infection conundrum and reconciliation with a worldwide zoonosis. In: Murrell KD, Fried B, editors. *World Class Parasites*, vol. 11. Boston: Springer; 2008. p. 151–184.
- Scholz T, Kuchta R. Fish-borne, zoonotic cestodes (*Diphyllbothrium* and relatives) in cold climates: a never-ending story of neglected and (re)-emergent parasites. *Food Waterborne Parasitol.* 2016;4:23–28.
- Scholz T, Kuchta R, Brabec J. Broad tapeworms (Diphyllbothriidae), parasites of wildlife and humans: recent progress and future challenges. *Int J Parasitol Parasites Wildl.* 2019;9:359–69. <https://doi.org/10.1016/j.ijppaw.2019.02.001>
- Králová-Hromadová I, Radačovská A, Čisovská Bazsalovicsová E, Kuchta R. Ups and downs of infections with the broad fish tapeworm *Dibothriocephalus latus* in Europe from 1900 to 2020: Part I. *Adv Parasitol.* 2021; 114:75–166. <https://doi.org/10.1016/bs.apar.2021.08.008>
- Gustinelli A, Menconi V, Prearo M, Caffara M, Righetti M, Scanzio T, et al. Prevalence of *Diphyllbothrium latum* (Cestoda: Diphyllbothriidae) plerocercoids in fish species from four Italian lakes and risk for the consumers. *Int J Food Microbiol.* 2016;235:109–12. <https://doi.org/10.1016/j.ijfoodmicro.2016.06.033>
- Moravec F. Checklist of the Metazoan Parasites of Fishes of the Czech Republic and the Slovak Republic (1873–2000). Prague: Academia; 2001.
- Konecny R, Sattmann H, Schabuss M, Jütte M, Lewis JW. A review of research studies on helminth parasites of fish from Austria. *Acta ZooBot Austria.* 2020;157:41–62.
- Kuchta R, Radačovská A, Čisovská Bazsalovicsová E, Králová-Hromadová I. Ups and downs of infections with the broad fish tapeworm *Dibothriocephalus latus* in Europe (Part II) and Asia from 1900 to 2020. *Adv Parasitol.* 2023;122:1–69. <https://doi.org/10.1016/bs.apar.2023.05.001>
- Ergens R. Results of parasitological investigation on the health of *Esox lucius* L. in the Lipno reservoir. *Folia Parasitol.* 1966;13:222–36.
- Čatár G, Sobota K, Kvasz L, Hrúzik J. The 1st nonimported case of diphyllbothriasis in Czechoslovakia [in Slovak]. *Bratisl Lék Listy.* 1967;47:241–4.

Address for correspondence: Tomáš Scholz, Institute of Parasitology, Biology Centre of the Czech Academy of Sciences, Branišovská 31, 370 05 České Budějovice, Czech Republic; email: tscholz@paru.cas.cz

## COMMENT LETTER

## Sporotrichosis in Domestic Cat and Zoonotic Transmission

Sunil More, Timothy A. Snider, Akhilesh Ramachandran

Author affiliations: Oklahoma State University College of Veterinary Medicine, Stillwater, Oklahoma, USA (S. More, A. Ramachandran); University of Missouri College of Veterinary Medicine, Columbia, Missouri, USA (T.A. Snider)

DOI: <https://doi.org/10.3201/eid3012.240864>

**To the Editor:** Recent cases of feline sporotrichosis with zoonotic human infection have been highlighted in Kansas, USA (1). We describe a challenging feline sporotrichosis case in Oklahoma, USA, that emphasizes the critical need for early diagnostic strategies to mitigate the risk of further zoonotic transmission. Of note, the cat also scratched the veterinarian and owner and severe skin lesions subsequently developed on both of them; lesions resolved within 2 weeks (M. Carver, unpub. data, telephone report).

A 4-year-old domestic short-haired cat was taken for veterinary care with a raised, nodular, ulcerated mass on its right front foot. The mass was unrespon-

sive to antibacterial treatment and progressively necrosed; the leg was subsequently amputated. A similar lesion developed on the left front foot. Skin biopsy samples from the cat's left front foot were submitted for analysis. Histopathology revealed dermal infiltrates of neutrophils and macrophages with edema, fibrin, and karyorrhectic debris. We observed numerous intrahistiocytic and extracellular round to oval, faint basophilic 4 to 10- $\mu$ m diameter yeasts surrounded by a clear halo (Figure 1, panel A, black arrowhead). Gram and Grocott methenamine silver stains showed yeasts with occasional cigar-shaped morphology (Figure 1, panel B, magenta arrow). We identified the fungal culture colonies as *Sporothrix schenckii* by using matrix-assisted laser desorption/ionization time-of-flight (MALDI-TOF) mass spectrometry. We cultured and identified a large number of secondary bacterial contaminants from the lesions.

Sporotrichosis caused by dimorphic fungus of the genus *Sporothrix* presents potential diagnostic challenges because it can manifest in various clinical forms in human patients (2). The differential diagnoses for sporotrichosis in cats, because of overlapping clinical features, include feline leprosy, bartonellosis, atypical mycobacterial infections, *Staphylococcus* spp. pyoderma, dermatophytosis (ringworm), cutaneous lymphoma, deep mycoses (cryptococcosis,