

several years after initial infection (*I*). Issues with primaquine (i.e., *CYP2D6*-poor metabolizers or hemolysis risk in patients with glucose-6-phosphate dehydrogenase deficiency) complicate treatment of dormant hypnozoites that cause relapse (*I*). A new treatment, tafenoquine, which still causes hemolysis in glucose-6-phosphate dehydrogenase deficiency, was recently approved in the United States as a single dose for prevention of *P. vivax* malaria relapse (*10*), although this medication might not reach at-risk groups in South America. Ecuador and Peru currently follow the Pan American Health Organization guidelines regarding primaquine use (<https://www.paho.org/hq/dmdocuments/2011/TreatmentGuidelines-2nd-ed-2010-eng.pdf>).

Local ministries of health responded quickly to these cases and implemented case surveillance. However, reductions in resources after elimination of local malaria transmission in 2011–2012 severely limited malaria control efforts in Ecuador and Peru. Imported cases of malaria at the Ecuador–Peru border region pose a serious threat of continued resurgence in local transmission. We urge international solutions for Venezuela’s humanitarian crisis and augmentation of infectious disease surveillance and control along migration routes and in surrounding regions.

About the Author

Dr. Jaramillo-Ochoa is an epidemiologist working for the Ministry of Health for the Health District of the city of Machala, El Oro Province, Ecuador. His primary research interests include the epidemiology of vectorborne diseases and monitoring and evaluating vector-control interventions.

References

1. Ashley EA, Pyae Phyo A, Woodrow CJ. Malaria. *Lancet*. 2018; 391:1608–21. [http://dx.doi.org/10.1016/S0140-6736\(18\)30324-6](http://dx.doi.org/10.1016/S0140-6736(18)30324-6)
2. World Health Organization. World malaria report 2018. Geneva: The Organization; 2018.
3. Recht J, Siqueira AM, Monteiro WM, Herrera SM, Herrera S, Lacerda MVG. Malaria in Brazil, Colombia, Peru and Venezuela: current challenges in malaria control and elimination. *Malar J*. 2017;16:273. <http://dx.doi.org/10.1186/s12936-017-1925-6>
4. Krisner LK, Krisner J, Ambuludi M, Arichabala A, Beltrán-Ayala E, Navarrete P, et al. Successful malaria elimination in the Ecuador–Peru border region: epidemiology and lessons learned. *Malar J*. 2016;15:573. <http://dx.doi.org/10.1186/s12936-016-1630-x>
5. World Health Organization. World malaria report 2014: Ecuador. Geneva: The Organization; 2014.
6. Ministerio de Salud Pública de Ecuador. Gaceta Vectorial SE 1–52, 2017. 2018 Jan 3 [cited 2018 Apr 15]. <https://www.salud.gob.ec/wp-content/uploads/2017/07/Gaceta-Vectorial-SE52.pdf>
7. Hotez PJ, Basañez MG, Acosta-Serrano A, Grillet ME. Venezuela and its rising vector-borne neglected diseases. *PLoS Negl Trop Dis*. 2017;11:e0005423. <http://dx.doi.org/10.1371/journal.pntd.0005423>
8. Grillet ME, Villegas L, Oletta JF, Tami A, Conn JE. Malaria in Venezuela requires response. *Science*. 2018;359:528.
9. Ryan SJ, Lippi CA, Boersch-Supan PH, Heydari N, Silva M, Adrian J, et al. Quantifying seasonal and diel variation in

Anopheline and *Culex* human biting rates in southern Ecuador.

10. Frampton JE. Tafenoquine: first global approval. *Drugs*. 2018;78:1517–23. <http://dx.doi.org/10.1007/s40265-018-0979-2>

Address for correspondence: Anna M. Stewart-Ibarra, Institute for Global Health & Translational Science, State University of New York Upstate Medical University, 505 Irving Ave, Syracuse, NY 13210, USA; email: stewart@upstate.edu

***Rickettsia parkeri* and *Candidatus Rickettsia andeanae* in Ticks of the *Amblyomma maculatum* Group, Mexico**

Jesús Delgado-de la Mora,¹
Sokani Sánchez-Montes,¹
Jesús D. Licona-Enríquez,¹
David Delgado-de la Mora,¹
Christopher D. Paddock, Lorenza Beati,
Pablo Colunga-Salas, Carmen Guzmán-Cornejo,
María L. Zambrano, Sandor E. Karpathy,
Andrés M. López-Pérez,
Gerardo Álvarez-Hernández

Author affiliations: Instituto Nacional de Ciencias Médicas y Nutrición Salvador Zubirán, Mexico City, Mexico (J. Delgado-de la Mora); Universidad Nacional Autónoma de México, Mexico City (S. Sánchez-Montes, P. Colunga-Salas, C. Guzmán-Cornejo, A.M. López-Pérez); Centro Médico Nacional Siglo XXI, Mexico City (J.D. Licona-Enríquez); Instituto Tecnológico de Sonora, Sonora, Mexico (D. Delgado-de la Mora); Centers for Disease Control and Prevention, Atlanta, Georgia, USA (C.D. Paddock, M.L. Zambrano, S.E. Karpathy); Georgia Southern University, Statesboro, Georgia, USA (L. Beati); Universidad de Sonora, Sonora (G. Álvarez-Hernández)

DOI: <https://doi.org/10.3201/eid2504.181507>

We report *Rickettsia parkeri* and *Candidatus Rickettsia andeanae* in ticks of the *Amblyomma maculatum* group collected from dogs in Sonora, Mexico. Molecular characterization of these bacteria was accomplished by DNA amplification and sequence analysis of portions of the rickettsial genes *gltA*, *htrA*, *ompA*, and *ompB*.

¹These authors contributed equally to this article.

Rickettsia parkeri, a member of the spotted fever group *Rickettsia* (SFGR), was initially identified in *Amblyomma maculatum* ticks in 1937, but not until 2004 was the first confirmed human infection reported (1). Through 2018, at least 9 cases of *R. parkeri* rickettsiosis have been identified across several mountainous locations in southern Arizona close to the US–Mexico border, and ticks of the *A. maculatum* group infected with *R. parkeri* have been collected from this region (2).

Epidemic levels of Rocky Mountain spotted fever (RMSF), a severe and frequently fatal spotted fever rickettsiosis, have been identified throughout regions of northern Mexico, including the state of Sonora (3). *R. rickettsii* (the agent of RMSF) is the only SFGR species linked with spotted fever rickettsiosis in Sonora; nonetheless, a unique lineage of *R. parkeri* associated with the *Dermacentor parvum* tick was reported recently from northern Mexico (4). Sonora shares an international border with Arizona; the recent identification of *R. parkeri* in *Amblyomma* ticks in southern Arizona (2) prompted our investigation during July 2016 for ticks in northern Sonora to determine whether another pathogenic SFGR species could also exist in Mexico.

The study area comprised 3 localities in Sonora (Yecora, 28°22'16"N, 108°55'32"W; Matarachi, 28°73'54"N, 108°95'87"W; and Mulatos, 28°65'85"N, 108°74'78"W) (Figure), each with a humid subtropical climate situated at ≈1,500 m, with vegetation comprising predominantly oak forests and grasslands (Appendix Figure, panel A, <https://wwwnc.cdc.gov/EID/article/25/4/18-1507-App1.pdf>). During August 2016 and September 2017, we inspected free-roaming dogs (*Canis lupus familiaris*) for attached or crawling ticks (Appendix Figure, panel B). We identified ticks using morphological characteristics (5).

For ticks collected in 2016, we dissected a portion of the posterolateral idiosoma from each specimen and extracted DNA using a DNeasy Blood and Tissue Kit (QIAGEN, <https://www.qiagen.com>). We screened DNA extracts using a *Rickettsia* genus-specific real-time PCR with primers PanR8_F and PanR8_R, probe PanR8_P (6), and 5 μL of DNA template. Samples with cycle threshold values <40 were tested by a PCR targeting a segment of the *ompA* gene using primers *Rr*190.70p and 190–701 (7). We also tested 1 positive sample using a nested PCR to amplify a segment of the 17-kDa antigen gene with primers R17122 and R17500 (8) in the primary amplification and TZ15 and TZ16 (9) in the nested amplification. Specimens collected in 2017 were processed similarly; however, we screened DNA extracts using a conventional PCR to amplify a segment of the *gltA* gene (4). We subsequently tested positive samples by conventional PCRs targeting fragments of the *ompA* and *ompB*, genes using primers and conditions described elsewhere (4). PCR products were sequenced using an ABI 3500 genetic analyzer with a BigDye Terminator v3.1 Cycle Sequencing Kit (Applied Biosystems, <https://www.thermofisher.com>). Sequences were assembled using Geneious R10 (Biomatters Ltd., <https://www.geneious.com>) and compared with GenBank data using blastn analysis (<http://blast.ncbi.nlm.nih.gov/Blast.cgi>).

We collected a total of 31 *A. maculatum* group ticks from northern Sonora (14 specimens from Yecora in 2016 and 17 from Matarachi and Mulatos in 2017). Three ticks collected in 2017 were deposited as voucher specimens in the Colección del Laboratorio de Acarología, Universidad Nacional Autónoma de México (Mexico City, Mexico).

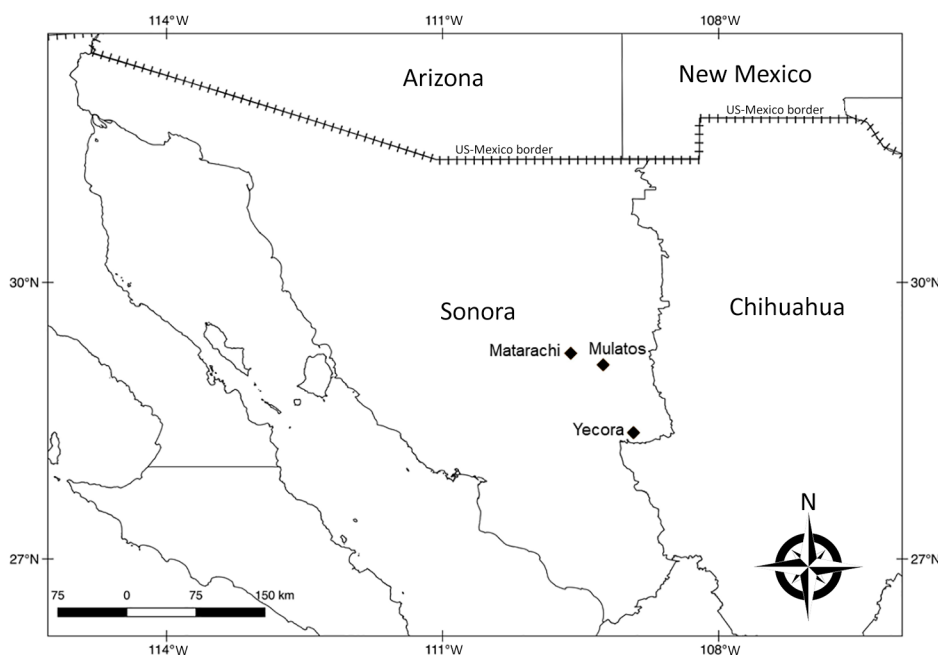


Figure. Locations where ticks of the *Amblyomma maculatum* group were collected (diamonds) in a study of *Rickettsia parkeri* and *Candidatus Rickettsia andeanae*, Sonora, Mexico. A layer of Google Maps was used to construct the figure.

We amplified a sequence demonstrating complete identity to the homologous 590-bp segment of the *ompA* gene of *R. parkeri* strain Maculatum 20 (GenBank accession no. U43802) from 1 (7%) of 14 ticks collected in 2016. We further amplified sequences demonstrating complete identities to the homologous segments of the *ompA* (590 bp) and 17-kDa antigen (208 bp) genes of *Candidatus Rickettsia andeanae* (GenBank accession nos. KF179352 and KY402193, respectively) from another tick in this group and sequences revealing complete identity to each other and to the homologous segments of the *gltA* (760 bp), *ompB* (760 bp), and *ompA* (490 bp) genes of *R. parkeri* strain Portsmouth (GenBank accession no. CP003341.1) from 10 (71%) of 14 ticks evaluated from the 2017 collection.

We identified DNA of *R. parkeri* and *Candidatus Rickettsia andeanae* in *A. maculatum* group ticks in northern Sonora. *R. parkeri* causes a disease less severe than RMSF and should be suspected in patients with an eschar, rash, and lymphadenopathy (1). The results of this investigation suggest that *R. parkeri* could contribute to at least some of the cases of spotted fever rickettsiosis described in Sonora and possibly in other regions of Mexico where *A. maculatum* group ticks are found. Differentiation between these 2 diseases is important, principally because there are no reports of fatal disease caused by *R. parkeri*. Nonetheless, clinical suspicion of any SFGR requires immediate treatment with doxycycline. *Candidatus Rickettsia andeanae*, a SFGR of undetermined pathogenicity, has been detected in the United States and Central and South America (2,10). Our findings highlight the need for specific diagnostic tests for SFGR in Mexico that can identify other potential SFGR of public health concern in this country.

About the Author

Dr. Delgado-de la Mora is a researcher and resident of Pathology at Instituto Nacional de Ciencias Médicas y Nutrición Salvador Zubirán. His research interests include tickborne diseases, particularly those caused by *Rickettsia* spp.

References

- Paddock CD, Sumner JW, Comer JA, Zaki SR, Goldsmith CS, Goddard J, et al. *Rickettsia parkeri*: a newly recognized cause of spotted fever rickettsiosis in the United States. *Clin Infect Dis*. 2004;38:805–11. <http://dx.doi.org/10.1086/381894>
- Allerdice MEJ, Beati L, Yaglom H, Lash RR, Delgado-de la Mora J, Licona-Enriquez JD, et al. *Rickettsia parkeri* (Rickettsiales: Rickettsiaceae) detected in ticks of the *Amblyomma maculatum* (Acari: Ixodidae) group collected from multiple locations in southern Arizona. *J Med Entomol*. 2017;54:1743–9. <http://dx.doi.org/10.1093/jme/tjx138>
- Álvarez-Hernández G, Roldán JFG, Milan NSH, Lash RR, Behravesh CB, Paddock CD. Rocky Mountain spotted fever in Mexico: past, present, and future. *Lancet Infect Dis*. 2017;17:e189–96. [http://dx.doi.org/10.1016/S1473-3099\(17\)30173-1](http://dx.doi.org/10.1016/S1473-3099(17)30173-1)
- Sánchez-Montes S, López-Pérez AM, Guzmán-Cornejo C, Colunga-Salas P, Becker I, Delgado-de la Mora J, et al. *Rickettsia parkeri* in *Dermacentor parumapertus* ticks, Mexico. *Emerg Infect Dis*. 2018;24:1108–11. <http://dx.doi.org/10.3201/eid2406.180058>
- Lado P, Nava S, Mendoza-Urbe L, Caceres AG, Delgado-de la Mora J, Licona-Enriquez JD, et al. The *Amblyomma maculatum* Koch, 1844 (Acari: Ixodidae) group of ticks: phenotypic plasticity or incipient speciation? *Parasites Vectors*. 2018;11:610.
- Kato CY, Chung IH, Robinson LK, Austin AL, Dasch GA, Massung RF. Assessment of real-time PCR assay for detection of *Rickettsia* spp. and *Rickettsia rickettsii* in banked clinical samples. *J Clin Microbiol*. 2013;51:314–7. <http://dx.doi.org/10.1128/JCM.01723-12>
- Regnery RL, Spruill CL, Plikaytis BD. Genotypic identification of rickettsiae and estimation of intraspecies sequence divergence for portions of two rickettsial genes. *J Bacteriol*. 1991;173:1576–89. <http://dx.doi.org/10.1128/jb.173.5.1576-1589.1991>
- Massung RF, Davis LE, Slater K, McKechnie DB, Puerzer M. Epidemic typhus meningitis in the southwestern United States. *Clin Infect Dis*. 2001;32:979–82. <http://dx.doi.org/10.1086/319351>
- Tzianabos T, Anderson BE, McDade JE. Detection of *Rickettsia rickettsii* DNA in clinical specimens by using polymerase chain reaction technology. *J Clin Microbiol*. 1989;27:2866–8.
- Paddock CD, Fournier PE, Sumner JW, Goddard J, Elshenawy Y, Metcalfe MG, et al. Isolation of *Rickettsia parkeri* and identification of a novel spotted fever group *Rickettsia* sp. from Gulf Coast ticks (*Amblyomma maculatum*) in the United States. *Appl Environ Microbiol*. 2010;76:2689–96. <http://dx.doi.org/10.1128/AEM.02737-09>

Address for correspondence: Jesús Delgado-de la Mora, Instituto Nacional de Ciencias Médicas y Nutrición Salvador Zubirán, Departamento de Anatomía Patológica, Avenida Vasco de Quiroga 15, Belisario Domínguez, C.P. 14080, Mexico City, Mexico; email: jdelgadom1992@gmail.com

Reduced Susceptibility to Neuraminidase Inhibitors in Influenza B Isolate, Canada

Yacine Abed,¹ Clément Fage,¹ Patrick Lagüe,¹ Julie Carbonneau, Jesse Papenburg, Donald C. Vinh, Guy Boivin

Author affiliations: Laval University, Québec City, Québec, Canada (Y. Abed, C. Fage, P. Lagüe, J. Carbonneau, G. Boivin); Montreal Children's Hospital, Montreal, Québec (J. Papenburg); McGill University Health Center, Montreal (D.C. Vinh)

DOI: <https://doi.org/10.3201/eid2504.181554>

¹These authors contributed equally to this article.