

7. Al-Benwan K, Ahmad S, Mokaddas E, Johny M, Kapoor M. Diagnosis of endocarditis caused by *Mycobacterium abscessus*. *Ann Saudi Med*. 2010;30:408–11.
8. Corrales-Medina V, Concha R, Simkins J, Sanchez M, Baracco G. Native valve endocarditis caused by rapidly growing mycobacteria: case report and review of the literature. *Scand J Infect Dis*. 2007;39:639–41. <http://dx.doi.org/10.1080/00365540601169745>
9. Tsai WC, Hsieh HC, Su HM, Lu PL, Lin TH, Sheu SH, et al. *Mycobacterium abscessus* endocarditis: a case report and literature review. *Kaohsiung J Med Sci*. 2008;24:481–6. [http://dx.doi.org/10.1016/S1607-551X\(09\)70005-1](http://dx.doi.org/10.1016/S1607-551X(09)70005-1)
10. Clinical and Laboratory Standards Institute. 2011. Susceptibility testing of mycobacteria, nocardia, and other aerobic actinomycetes; Approved Standard-Second Edition. CLSI document M24–A2. Wayne, PA: Clinical and Laboratory Standards Institute. Vol. 31, Number 5.
11. Galil K, Thurer R, Glatter K, Barlam T. Disseminated *Mycobacterium chelonae* infection resulting in endocarditis. *Clin Infect Dis*. 1996;23:1322–3. <http://dx.doi.org/10.1093/clinids/23.6.1322>

Address for correspondence: R. Gordon Huth, University of Texas Southwestern Residency Programs, 601 E 15th St, Austin, TX 78701, USA; email: ghuth@seton.org

***Rickettsia rickettsii* in *Amblyomma patinoi* Ticks, Colombia**

**Álvaro A. Faccini-Martínez,
Francisco B. Costa, Tatiana E. Hayama-Ueno,
Alejandro Ramírez-Hernández,
Jesús A. Cortés-Vecino, Marcelo B. Labruna,
Marylin Hidalgo**

Author affiliations: Pontificia Universidad Javeriana, Bogotá, Colombia (Á.A. Faccini-Martínez, M. Hidalgo); Universidade de São Paulo, São Paulo, Brazil (F.B. Costa, T.E. Hayama-Ueno, M.B. Labruna); Universidad Nacional de Colombia, Bogotá (A. Ramírez-Hernández, J.A. Cortés-Vecino)

DOI: <http://dx.doi.org/10.3201/eid2103.140721>

To the Editor: *Rickettsia rickettsii* is the etiologic agent of Rocky Mountain spotted fever (RMSF), a highly lethal tick-borne rickettsiosis restricted to the Western Hemisphere (1,2). In Colombia, *R. rickettsii* was first reported during the 1930s, when 62 (95%) of 65 affected persons died of RMSF in Tobia town (Cundinamarca Department) (3), from where highly virulent strains of *R. rickettsii* were isolated through the inoculation of patient blood or of *Amblyomma cajennense* sensu lato (s.l.) extracts into guinea pigs (4). Thereafter, RMSF remained unnoticed in Colombia until the 21st century, when new outbreaks with high case-fatality rates were reported in different regions, including Villeta, a nearby locality of Tobia (1).

Recent studies have shown that *A. cajennense* s.l., widely distributed from the southern United States to Argentina, is actually a complex of 6 different species: *A. cajennense* sensu stricto (Amazonian region), *A. mixtum* (from Texas, USA, to western Ecuador), *A. sculptum* (northern Argentina, Bolivia, Paraguay, Brazil), *A. interandinum* (inter-Andean valley of Peru), *A. tonelliae* (dry areas of northern Argentina, Bolivia, and Paraguay), and *A. patinoi* (eastern cordillera of Colombia) (5). With this new classification, *A. patinoi*, originally described from Villeta, is the only species of this complex known to occur in the RMSF-endemic area of Cundinamarca, Colombia (5).

In August 2013, we collected 15 *A. patinoi* adult ticks from cattle in Naranjal village (5°3'31.52"N, 74°26'50.24"W), Villeta town, an area of Cundinamarca, Colombia, to which RMSF is endemic. Ticks were taken alive to the laboratory, where they were frozen at –80°C for further analysis. The 15 ticks were defrosted, surface sterilized with iodine alcohol, and processed individually by the shell vial technique for isolation of rickettsiae in Vero cells, as described (6). Infected cells were always incubated at 28°C. Rickettsiae were observed by Gimenez staining within cells (online Technical Appendix Figure 1, <http://wwwnc.cdc.gov/EID/article/21/3/14-0721-Techapp1.pdf>) from only 1 (inoculated from a female tick) of the 15 inoculated shell vials. This isolate was subjected to at least 7 Vero cell passages, each achieving >90% infected cells.

DNA was extracted from an aliquot of first passage–infected cells and tested by a battery of PCR protocols targeting fragments of the rickettsial genes *gltA*, *ompA*, and *ompB* and the intergenic regions RR0155-*rpmB*, RR1240-*tlc5b*, and *cspA-ksgA* (Table). We sequenced 1,106 bp, 512 bp, and 799 bp of the *gltA*, *ompA*, and *ompB* genes, respectively. By BLAST analyses (<http://www.ncbi.nlm.nih.gov/blast>), these sequences were 100% identical to corresponding sequences of *R. rickettsii* from Colombia and Brazil (GenBank accession nos. CP003306, CP003305). Generated sequences for 2 intergenic regions, RR0155-*rpmB* (228 bp) and RR1240-*tlc5b* (306 bp), were 100% identical to corresponding sequences of the same 2 *R. rickettsii* isolates from Colombia and Brazil. A 337-bp sequence of the *cspA-ksgA* intergenic region was 100% (337/337 nt) identical to *R. rickettsii* from Brazil (CP003305) and 99.7% (336/337) to *R. rickettsii* from Colombia (CP003306). Partial sequences from *R. rickettsii* generated in this study were deposited into GenBank and assigned nucleotide accession nos. KJ735644–KJ735649.

Whole-body remnants of the 15 ticks used to inoculate shell vials were also subjected to DNA extraction and processed by PCR for the rickettsial *gltA* gene (Table); only 1 tick (the one that provided the rickettsial isolate) contained rickettsial DNA, indicating a 6.6% (1/15) infection rate. We confirmed the taxonomic identification of this

Table. Primer pairs used for amplification of rickettsial genes or intergenic regions, Colombia, August 2013

Target, primer pairs, primers	Primer sequences, 5' → 3'	Fragment size, bp	Reference
<i>gltA</i>			
1			
CS-78	GCAAGTATCGGTGAGGATGTAAT	401	(6)
CS-323	GCTTCCTTAAAATCAATAAATCAGGAT		(6)
2			
CS-239	GCTCTTCTCATCCTATGGCTATTAT	834	(6)
CS-1069	CAGGGTCTTCGTGCATTCTT		(6)
<i>ompA</i>			
3			
Rr190.70p	ATGGCGAATATTTCTCCAAAA	530	(7)
Rr190.602n	AGTGCCAGCATTGCTCCCCCT		(7)
<i>ompB</i>			
4			
120-M59	CCGCAGGGTTGGTAACTGC	862	(8)
120-807	CCTTTTAGATTACCGCCTAA		(8)
RR0155- <i>rpmB</i>			
5			
Forward	TTTCTAGCAGCGGTTGTTTTATCC	290	(9)
Reverse	TTAGCCCATGTTGACAGGTTTACT		(9)
RR1240- <i>tlc5^p</i>			
6			
Forward	CGGGATAACGCCGAGTAATA	357	(10)
Reverse	ATGCCGCTCTGAATTTGTTT		(10)
<i>cspA-ksgA</i>			
7			
Forward	CATCACTGCTTCGCTTATTTT	405	(9)
Reverse	ATTTCTTTTCTCCTCTTCATCAA		(9)

tick as *A. patinoi* by generating mitochondrial 16S rRNA partial sequences from it and from an *A. patinoi* paratype that is deposited in the tick collection of the University of São Paulo (Brazil) (accession no. CNC-1585) (5). Both sequences were 100% identical to each other (deposited into GenBank under accession nos. KP036466–KP036467).

A 3 mL-aliquot of the second infected cell passage was inoculated intraperitoneally into an adult male guinea pig, in which high fever (rectal temperature >40.0°C) developed during days 5–8 days post inoculation. A total of 3 guinea pig passages were performed, always followed by high fever. A second passage animal survived; scrotal necrosis developed (online Technical Appendix Figure 2), and this animal seroconverted to *R. rickettsii* with 32,768 endpoint IgG titer through the immunofluorescence assay, as described (2).

A highly pathogenic strain of *R. rickettsii* was isolated from an *A. patinoi* specimen collected at Villeta, where recent human cases of RMSF have been reported (1). More than 70 years ago, the only previous *R. rickettsii* tick isolates in Colombia were obtained from *A. cajennense* s.l. in Tobia, only 20 km from Villeta (4). At that time, ticks of the *A. cajennense* complex were considered natural vectors of *R. rickettsii* in Tobia (4). Because the *A. cajennense* s.l. complex was recently found to be represented in the eastern cordillera of Colombia (which includes Tobia and Villeta) by the species *A. patinoi* (5), the tick isolates obtained >70 years ago also are highly likely to have been obtained from *A. patinoi*. Therefore, *A. patinoi* ticks should be considered the main vector of *R. rickettsii* to humans in this region of Colombia.

COLCIENCIAS provided financial support (code 120351929098). Regulatory permits for this work were as follows: Scientific research in biodiversity (Corporación Autónoma Regional no. 005 of June 19/2012), and Ministerio de Ambiente y Desarrollo sostenible from Colombia (no. 85 of 2013).

References

- Hidalgo M, Orejuela L, Fuya P, Carrillo P, Hernández J, Parra E, et al. Rocky Mountain spotted fever, Colombia. *Emerg Infect Dis*. 2007;13:1058–60. <http://dx.doi.org/10.3201/eid1307.060537>
- Krawczak FS, Nieri-Bastos FA, Nunes FP, Soares JF, Moraes-Filho J, Labruna MB. Rickettsial infection in *Amblyomma cajennense* ticks and capybaras (*Hydrochoerus hydrochaeris*) in a Brazilian spotted fever–endemic area. *Parasit Vectors*. 2014;7:7.
- Patiño L, Afanador A, Paul JH. A spotted fever in Tobia, Colombia. *Am J Trop Med*. 1937;17:639–53.
- Patiño-Camargo L. Nuevas observaciones sobre un tercer foco de fiebre petequial (maculosa) en el hemisferio Americano. *Bol De la Ofic Sanit Panamericana*. 1941;20:1112–24.
- Nava S, Beati L, Labruna MB, Caceres AG, Mangold AJ, Guglielmo AA. Reassessment of the taxonomic status of *Amblyomma cajennense* (Fabricius, 1787) with the description of three new species, *Amblyomma tonelliae* n. sp., *Amblyomma interandinum* n. sp. and *Amblyomma patinoi* n. sp., and resurrection of *Amblyomma mixtum* Koch, 1844 and *Amblyomma scultrum* Berlese, 1888 (Ixodida: Ixodidae). *Ticks Tick Borne Dis*. 2014;5:252–76. <http://dx.doi.org/10.1016/j.ttbdis.2013.11.004>
- Labruna MB, Whitworth T, Horta MC, Bouyer DH, McBride JW, Pinter A, et al. *Rickettsia* species infecting *Amblyomma cooperi* ticks from an area in the state of São Paulo, Brazil, where Brazilian spotted fever is endemic. *J Clin Microbiol*. 2004;42:90–8. <http://dx.doi.org/10.1128/JCM.42.1.90-98.2004>
- Eremeeva M, Yu X, Raoult D. Differentiation among spotted fever group rickettsiae species by analysis of restriction fragment

length polymorphism of PCR-amplified DNA. *J Clin Microbiol.* 1994;32:803–10.

8. Roux V, Raoult D. Phylogenetic analysis of members of the genus *Rickettsia* using the gene encoding the outer membrane protein rOmpB (*ompB*). *Int J Syst Evol Microbiol.* 2000;50:1449–55. <http://dx.doi.org/10.1099/00207713-50-4-1449>
9. Karpathy SE, Dasch GA, Ereemeeva ME. Molecular typing of isolates of *Rickettsia rickettsii* by use of DNA sequencing of variable intergenic regions. *J Clin Microbiol.* 2007;45:2545–53. <http://dx.doi.org/10.1128/JCM.00367-07>
10. Fournier PE, Zhu Y, Ogata H, Raoult D. Use of highly variable intergenic spacer sequences for multispacer typing of *Rickettsia conorii* strains. *J Clin Microbiol.* 2004;42:5757–66. <http://dx.doi.org/10.1128/JCM.42.12.5757-5766.2004>

Address for correspondence: Marylin Hidalgo, Microbiology Department, Building 50, Pontificia Universidad Javeriana, Carrera 7ª No 43-82, Bogotá, Colombia; email: hidalgo.m@javeriana.edu.co

***Mycobacterium bovis* BCG–Associated Osteomyelitis/Osteitis, Taiwan**

**Nan-Chang Chiu, Meng-Chin Lin, Wen-Li Lin,
Shin-Yi Wang, Hsin Chi, Li-Min Huang,
Ren-Bin Tang, Yhu-Chering Huang,
Ching-Chuan Liu, Fu-Yuan Huang, Tzou-Yien Lin**

Author affiliations: Mackay Memorial Hospital, Taipei, Taiwan (N.-C. Chiu, M.-C. Lin, W.-L. Lin, H. Chi, F.-Y. Huang); Mackay Junior College of Medicine, Nursing and Management, Taipei (N.-C. Chiu, H. Chi); Taiwan Centers for Disease Control, Taipei (S.-Y. Wang); National Taiwan University Hospital, Taipei (L.-M. Huang); Cheng Hsin General Hospital, Taipei (R.-B. Tang); Chang Gung Memorial Hospital, Taoyuan, Taiwan (Y.-C. Huang, T.-Y. Lin); National Cheng Kung University Hospital, Tainan, Taiwan (C.-C. Liu); Ministry of Health and Welfare, Executive Yuan, Taipei (T.-Y. Lin)

DOI: <http://dx.doi.org/10.3201/eid2103.140789>

To the Editor: Thirty-eight patients with *Mycobacterium bovis* BCG–associated osteomyelitis/osteitis, including 8 who were previously reported (1), were identified during Taiwan’s vaccine injury compensation program during 1989–2012; a total of 30 (79%) patients applied for compensation during 2009–2012 (Figure). In Taiwan, a laboratory program to differentiate BCG from other species of the *M. tuberculosis* complex, using a kit for the Tokyo-172 vaccine strain spoligotyping, was established in 2004 (1). Since 2008, the isolated extrapulmonary tuberculosis strains and pathologic specimens collected from children <5 years of age have been sent to the national reference mycobacterial laboratory for BCG detection (2). The

detected incidence of BCG osteitis/osteomyelitis increased from 3.68 cases per million vaccinations during 2002–2006 to 30.1 per million during 2008–2012.

Parents or guardians signed written consent forms on behalf of the children when they submitted claims for the vaccine injury compensation program. After consent, children’s hospital information was stored in the Taiwan Centers for Disease Control database and used for research.

Of the 38 compensated BCG osteomyelitis/osteitis patients, 18 were boys. According to chart review, no patients had immunodeficiency or other underlying conditions; however, 3 were premature babies (born at 34–36 weeks of gestation). Eighteen (47%) children had received BCG at ≤ 1 week of age, 12 (32%) at 1–4 weeks, 7 (18%) at 1–2 months, and 1 at >2 months. The average age at inoculation was 16.2 ± 16.6 days. Symptoms or signs began 3–32 months (average 12.4 ± 6.1 months) after BCG vaccination; for 68%, symptoms or signs developed 7–18 months after vaccination (online Technical Appendix Figure, <http://wwwnc.cdc.gov/EID/article/21/3/14-0789-Techapp1.pdf>). Time from vaccination to onset of symptoms or signs did not differ for the 3 premature infants.

As in previous reports (3,4), extremity bones were more commonly involved than axial bones. For 30 (79%) children, extremity bones were involved: 14 right lower limbs, 7 left lower limbs, 6 left upper limbs, and 3 right upper limbs. The tibia was the most common site (9 patients), followed by ankle bones (8 patients), femur (4 patients), radius and thumb (3 patients each), humerus and knee (2 patients each), and ulna (1 patient). Of these, 2 patients had 2 bony lesions. In 8 (21%) children, axial bones were involved: 5 sternums, 2 thoracic vertebrae, and 1 right rib. Presentation included a mass (25 [66%] children), tenderness (22 [58%]), limping (19 [50%]), redness (14 [37%]), and heat (7 [18%]). Average time from first clinical visit to final surgical management was 1.6 ± 2.1 months.

Eight (53%) of 15 patients had positive tuberculin skin test results. No specific abnormalities were found with regard to blood cell counts and inflammation markers or to chest radiographs, except for 1 child with rib

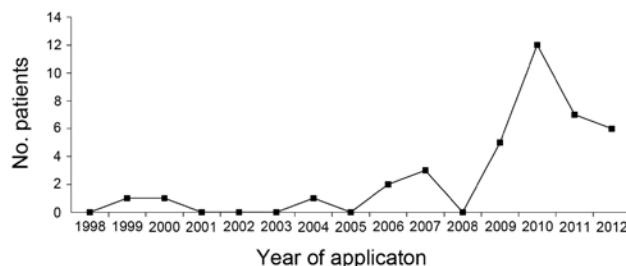
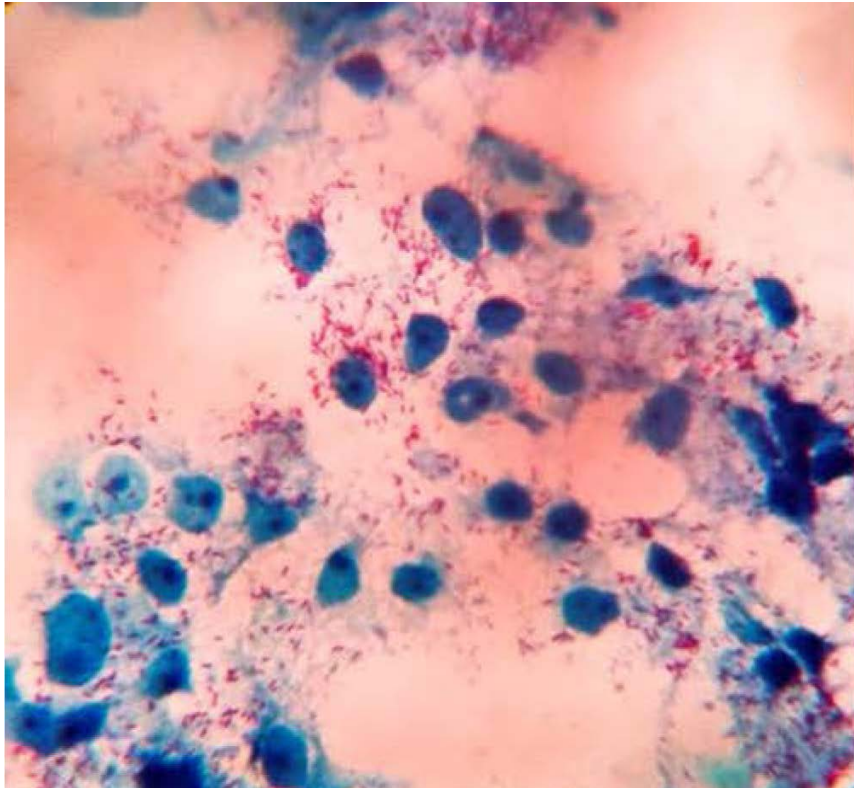


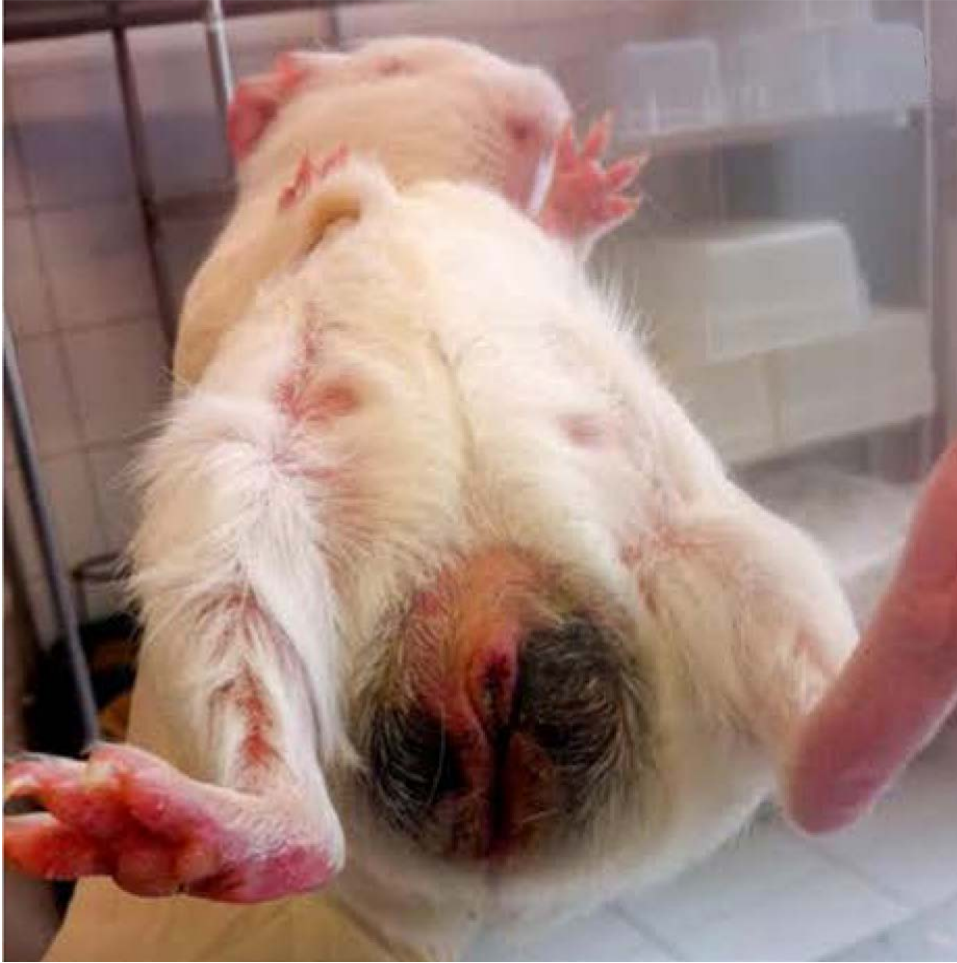Figure. Number of patient applications for compensation as a result of *Mycobacterium bovis* BCG osteomyelitis/osteitis in vaccine injury compensation program, Taiwan, 1998–2012.

Rickettsia rickettsii in *Amblyomma patinoi* Ticks, Colombia

Technical Appendix



Technical Appendix Figure 1. *Rickettsia rickettsii* isolated from an *Amblyomma patinoi* tick, Villeta, Colombia, August 2013. Second passage of infected Vero cells that were inoculated with infected tick extract through the shell vial technique. Gimenez staining, original magnification $\times 100$.



Technical Appendix Figure 2. Scrotal necrosis in a guinea pig that had been inoculated with *Rickettsia rickettsii*-infected Vero cells 14 days previously.