

Hospital Medical Center in Flushing, New York, with complaints of headache, fever, and vomiting, which she had experienced for  $\approx$ 1 week. She had no photophobia, confusion, or rash; neurologic examination found no abnormalities. CSF contained 81 leukocytes with 82% lymphocytes, 3 erythrocytes, protein at 194 mg/dL, and glucose at 67 mg/dL. CSF was positive for HSV-1 viral DNA by PCR. A computed tomography (CT) scan of the head showed unilateral temporal lobe edema. Intravenous acyclovir 10 mg/kg every 8 hours was administered. HIV test was negative. On day 5, a repeat CT scan showed worsening edema and hemorrhage, despite clinical improvement (Figure). CSF contained 490 leukocytes with 99% lymphocytes and protein at 336 mg/dL. After continued treatment with paravenous acyclovir, the patient's symptoms resolved. On day 12, the patient

was discharged after a final CT scan showed resolution of hemorrhage and edema and CSF contained decreased leukocytes and protein.

Although this patient had classic signs of meningitis without encephalitis, the CT scan of the head showed cerebral involvement. These factors can be explained by the location of cerebral inflammation in the nondominant lobe of the brain, thereby masking signs of encephalitis. The classic teaching that viral meningitis may not need treatment may miss the occasional viral encephalitis if brain imaging and CSF PCR are not performed. Failure to perform these tests may lead to illness and death from HSV encephalitis if this disease is not considered as a possible diagnosis.

**Deborah Asnis and Nadia Niazi**

Author affiliation: Flushing Hospital Medical Center, Flushing, New York, USA

DOI: 10.3201/eid1508.090466

## References

1. Whitley RJ. Viral encephalitis. *N Engl J Med.* 1990;323:242–9.
2. Levitz RE. Herpes simplex encephalitis: a review. *Heart Lung.* 1998;27:209–12. DOI: 10.1016/S0147-9563(98)90009-7
3. Taylor SW, Lee DH, Jackson AC. Herpes simplex encephalitis presenting with exclusively frontal lobe involvement. *J Neurovirol.* 2007;13:477–81. DOI: 10.1080/13550280701491131
4. Politei JM, Demey I, Pagano MA. Cerebral hematoma in the course of herpes simplex encephalitis. *Rev Neurol.* 2003;36:636–9.
5. Kennedy PGE, Chaudhuri A. Herpes simplex encephalitis. *J Neurol Neurosurg Psychiatry.* 2002;73:237–8. DOI: 10.1136/jnnp.73.3.237
6. Fodor PA, Levin MJ, Weinberg A, Sandberg E, Sylman J, Tyler KL. Atypical herpes simplex virus encephalitis diagnosed by PCR amplification of viral DNA from CSF. *Neurology.* 1998;51:554–9.

Address for correspondence: Deborah Asnis, Flushing Hospital Medical Center, Department of Internal Medicine, 4500 Parsons Blvd, Flushing, NY 11335, USA; email: iddoc@erols.com

## Tick-Borne Rickettsiosis in Traveler Returning from Honduras

**To the Editor:** Although tick-borne rickettsioses are widespread globally, few reports document their presence in Central America (1). Sero-surveys detected rickettsial antibodies in humans in Central America in 1971 in Costa Rica, Honduras, Nicaragua, and Panama (2,3). An outbreak of rickettsial illness was reported to have occurred in Costa Rica in 1974, where 2 case clusters affected 6 of 15 family members (4). A rickettsial organism was isolated from a patient who died in Panama in 1950 (5), and more recently *Rickettsia rickettsii* was con-

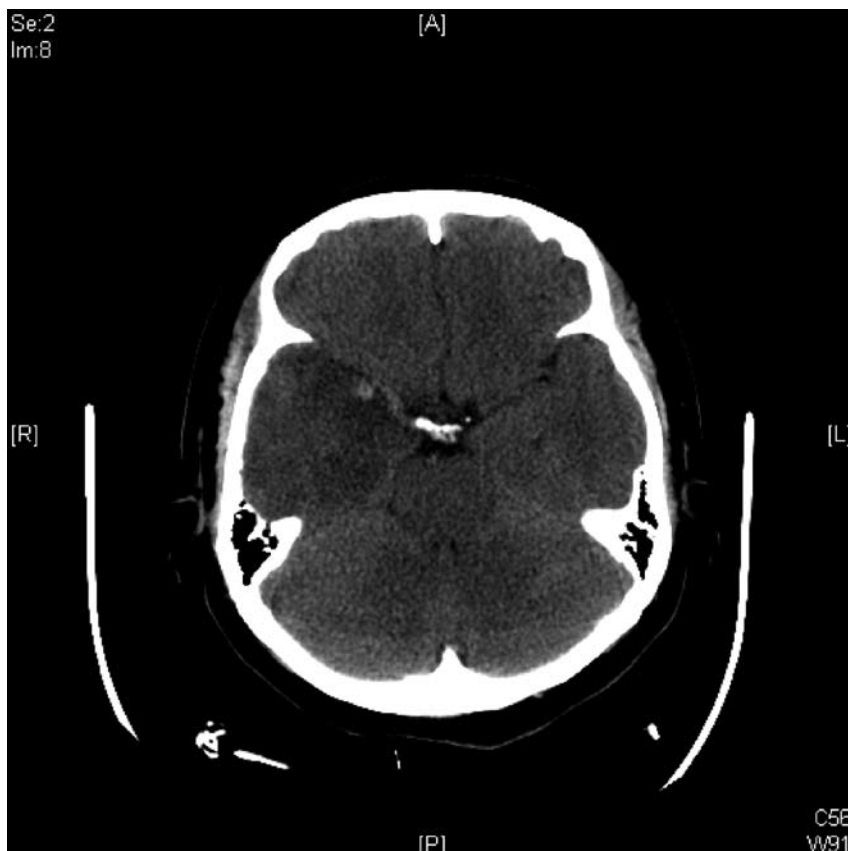


Figure. Computed tomograph scan showing hemorrhage in edematous part of brain of patient with herpes simplex virus encephalitis, day 5 of hospitalization.

firmed in a fatal case in Panama (6). We report a patient with serologic evidence of rickettsiosis after a tick bite sustained during travel in Honduras.

A 51-year-old man sought medical evaluation after returning from travel to Roatan, Honduras, where he was bitten by a tick in the lower abdomen. He reported erythema and induration at the site of the tick bite with associated central necrosis. He described an illness with headache, fever, weakness, dizziness, abdominal discomfort, diarrhea, flu-like symptoms, and respiratory symptoms affecting him 1–2 weeks after the tick bite. He was evaluated while still traveling and received multiple diagnoses, including malaria, respiratory infection, and parasites, and was given chloroquine, primaquine, penicillin, and mebendazole. His condition improved. He returned to the United States 2 months after the tick bite.

His travel history included Thailand, Jamaica, Aruba, the Bahamas, Belize, Germany, Spain, Hungary, the Netherlands, and New Zealand. The patient recalled removing ticks from his body as a child in Maryland but had no associated illness. He denied any recent tick bite other than the one in Honduras, where he had close contact with a horse and dogs and was frequently outdoors.

Results of his physical examination were unremarkable; routine laboratory studies showed values within reference ranges. No antibodies to *Borrelia burgdorferi* or *Plasmodium* spp. were detected.

Serologic analysis for rickettsia, performed by a commercial laboratory (Focus Diagnostics, Cypress, CA, USA) and the Centers for Disease Control and Prevention (Atlanta, GA, USA), showed elevated titers (Table). The patient took doxycycline (100 mg 2×/d) for 10 days and subjectively improved.

On the basis of infections documented in the Americas, *R. rickettsii*, *R. africae*, and other less well-known

rickettsial pathogens such as *R. parkeri* or *R. massiliae* (1) are possible etiologic agents in our case. The most common human-biting tick in Central America is *Amblyomma cajennense*, which is a known vector of *R. rickettsii*. Serosurveys have suggested the presence of *R. rickettsii* infection in the Yucatan (7), and PCR has confirmed a case of *R. rickettsii* in that region (8). *Rhipicephalus sanguineus*, the vector of *R. conorii* (boutonneuse fever) in the Mediterranean, is also found in Mexico, but to date no transmission of *R. conorii* has been documented in the Americas. *R. sanguineus* was implicated in a cluster of human Rocky Mountain spotted fever cases in the United States in 2002–2004 (9).

Our patient had not traveled to the areas of the Caribbean where transmission of *R. africae* has been documented, but he had lived in areas of the United States with potential transmission of rickettsial infections. *R. parkeri* is a newly recognized pathogen in the Americas (10). Its vectors (*A. maculatum* and *A. triste*) are found in parts of North, Central, and South America. The illness caused by *R. parkeri* appears to be less severe than Rocky Mountain spotted fever and could be consistent with our patient's illness. Because antibodies against *R. parkeri* and *R. rickettsii* cross-react, serologic analy-

sis is of little use for differentiating these 2 organisms.

The history and serologic findings for our patient suggest a recent tick-borne rickettsiosis, most likely acquired in Honduras. However, we can neither confirm that infection was recent nor confirm the species. The history of a tick bite and description of the skin lesion are consistent with an eschar, but no physical evidence of the tick or eschar remained at the time of evaluation. Diagnosis of rickettsial infection can be confirmed by demonstrating at least a 4-fold increase in titers between acute-phase and convalescent-phase serum samples, by identification of rickettsiae in an acute-phase serum or tissue sample, or by culture. Use of an immunofluorescent antibody assay alone does not identify the specific agent causing spotted fever.

Because our patient was examined 2 months after the exposure, options for making a diagnosis were limited. Extensive serologic cross-reactivity exists among the rickettsial species, which precludes the determination of species in our case. Although antibodies to rickettsiae can be long-lived, the extremely high levels of immunoglobulin (Ig) G and IgM suggest a recent rickettsial infection in our patient. Testing was unavailable for other rickettsiae (e.g., *R. parkeri*, *R. massiliae*).

Table. *Rickettsia* spp. serologic titers for a man who returned from Honduras, 2005\*

Test	Titers on specific date				
	May 26	Jun 10	Jul 14	Aug 25	Nov 22
RMSF IgG†	Positive, ≥1,024		Positive, ≥1,024	Positive, ≥1,024	Positive, ≥1,024
RMSF IgM†	Positive, 512		Positive, 256	Positive, 128	Positive, 256
<i>R. conorii</i> IgG‡			≥1,024	512	512
<i>R. conorii</i> IgM‡			64	64	64
<i>R. africae</i> IgG‡		2,048		4,096	
<i>R. africae</i> IgM‡		512			
<i>R. conorii</i> IgG‡		2,048		4,096	
<i>R. conorii</i> IgM‡		512			
<i>R. rickettsii</i> IgG‡		1,024			
<i>R. rickettsii</i> IgM‡		256			

\*Reference titer for negative/normal result is <64. RMSF, Rocky Mountain spotted fever; Ig, immunoglobulin.

†Testing done by Focus Diagnostics, Cypress, CA, USA.

‡Testing done by Centers for Disease Control and Prevention, Atlanta, GA, USA.

Our patient likely had rickettsial infection acquired in Honduras. We present this case to alert clinicians to consider the diagnosis of rickettsial infections in the Americas, even if infections have not been previously documented in a specific country or region. Because rickettsial infections can be severe and are treatable, the clinician should consider rickettsial infections in returned travelers with compatible clinical findings. Our case also demonstrates the potential role of travelers as sentinels of emerging infectious diseases.

### Acknowledgments

We thank Sam Telford and Philippe Parola for their helpful comments and reviews.

### Lin H. Chen and Mary E. Wilson

Author affiliations: Mount Auburn Hospital, Cambridge, Massachusetts, USA (L.H. Chen, M.E. Wilson); Harvard Medical School, Boston, Massachusetts, USA (L.H. Chen, M.E. Wilson); and Harvard School of Public Health, Boston (M.E. Wilson)

DOI: 10.3201/eid1508.090172

### References

1. Parola P, Labruna MB, Raoult D. Tick-borne rickettsioses in America: unanswered questions and emerging diseases. *Curr Infect Dis Rep*. 2009;11:40–50. DOI: 10.1007/s11908-009-0007-5
2. Parola P, Paddock CD, Raoult D. Tick-borne rickettsioses around the world: emerging diseases challenging old concepts. *Clin Microbiol Rev*. 2005;18:719–56. DOI: 10.1128/CMR.18.4.719-756.2005
3. Peacock MG, Ormsbee RA, Johnson KM. Rickettsioses of Central America. *Am J Trop Med Hyg*. 1971;20:941–9.
4. Campbell CC, Hobbs JH, Marranghello L, Vargas M, Shepard C, Feldman RA. An apparent outbreak of rickettsial illness in Costa Rica, 1974. *Bull Pan Am Health Organ*. 1978;12:104–11.
5. De Rodaniche EC, Rodaniche A. Spotted fever in Panama: isolation of the etiologic agent from a fatal case. *Am J Trop Med Hyg*. 1950;30:511–7.
6. Estrepeaut D, Aramburu MG, Saez-Llorens X, Thompson HA, Dasch GA, Paddock CD, et al. Rocky Mountain spotted fever, Panama. *Emerg Infect Dis*. 2007;13:1763–5.
7. Zavala-Velazquez JE, Yu X-J, Walker DH. Unrecognized spotted fever group rickettsiosis masquerading as dengue fever in Mexico. *Am J Trop Med Hyg*. 1996;55:157–9.
8. Zavala-Castro JE, Zavala-Velázquez JE, Walker DH, Ruiz Arcila EE, Laviada-Molina H, Olano JP, et al. Fatal human infection with *R. rickettsii*, Yucatan, Mexico. *Emerg Infect Dis*. 2006;12:672–4.
9. Demma LJ, Traeger MS, Nicholson WL, Paddock CD, Blau DM, Eremeeva ME, et al. Rocky Mountain spotted fever from an unexpected tick vector in Arizona. *N Engl J Med*. 2005;353:587–94. DOI: 10.1056/NEJMoa050043
10. Paddock CD, Sumner JW, Comer JA, Zaki SR, Goldsmith CS, Goddard J, et al. *Rickettsia parkeri*: a newly recognized cause of spotted fever rickettsiosis in the United States. *Clin Infect Dis*. 2004;38:805–11. DOI: 10.1086/381894

Address for correspondence: Lin H. Chen, Travel Medicine Center, Division of Infectious Diseases, Mount Auburn Hospital, 330 Mount Auburn St, Cambridge, MA 02238, USA; email: lchen@hms.harvard.edu

## KI and WU Polyomaviruses in Patients Infected with HIV-1, Italy

**To the Editor:** Before 2007, two human polyomaviruses were known to infect humans: BK virus and JC virus (1,2). Recently, 2 novel polyomaviruses, KI polyomavirus (KIPyV) and WU polyomavirus (WUPyV), were identified in the respiratory secretions of children with signs of acute respiratory signs (3,4); little evidence exists to suggest that these viruses are causative agents of respiratory tract disease (5). To determine the prevalence of WUPyV and KIPyV in the plasma of HIV-1-infected patients, we screened 62 persons who were HIV-1 positive

by using PCR to detect the 2 viruses. We also conducted phylogenetic analysis of the identified strains.

Plasma specimens were collected at Istituto di Ricovero e Cura a Carattere Scientifico Istituto Fisioterapico Ospetaliere–San Gallicano Institute and Tor Vergata University Hospital, Rome, Italy, from April 2005 through September 2008. Patients were adults (37–54 years of age, median age 45.5 years) and were being treated with antiretroviral drugs. HIV-1 viral load determination, CD4+ counts, and HIV-1 genotyping were performed as part of the routine investigation. Plasma viremia levels ranged from <50 to 2,877,764 copies/mL, and CD4+ counts ranged from 150 to 1,218. Most patients (64.5%) were infected by HIV-1 subtype B. Other subtypes found were F, G, and C.

Total DNA was extracted from 0.2 mL of plasma by using the QIAamp DNA Mini Kit according to the manufacturer's instruction (QIAGEN S.p.A., Milan, Italy) and then stored at –80°C until analysis. KIPyV and WUPyV PCR screening was carried out as described (3,4). Positive isolates were reamplified with primers encompassing the N-terminal part of the large T antigen (*T-Ag*) and almost the entire small t antigen (*t-Ag*) genes. KIPyV was amplified as described (6), and, for WUPyV, the primers were FWUV4460 5'-ACTGAGACCAC-CAGTAATCCCAG-3' (4460–4482 nt) and RWUV5200 5'-AAGCAGAG-GGCCTTGCTGAGGCG-3' (5200–5178 nt). The thermal cycling profile was 1 cycle at 94°C for 10 min and then 40 cycles at 94°C for 30 s, at 65°C for 30 s, and at 72°C for 60 s. The amplified *t-Ag* fragments were sequenced as described (6). The obtained sequences (KIV-RM21, KIV-RM22, and WU-IT3) were submitted to GenBank (accession nos. FJ842112–FJ842114) and matched against all deposited sequences ([www.ncbi.nlm.nih.gov/BLAST](http://www.ncbi.nlm.nih.gov/BLAST)). ClustalX software (<http://bips.u-strasbg.fr/fr/documentation/>