

queries for influenza-like illness and acute diarrhea and the incidences of these diseases; the peak of the time series of Google queries occurred at the same time as that of the disease incidences. The best query for chickenpox had a 1-week lag, i.e., was 1 week behind the incidence time series.

In conclusion, for each of 3 infectious diseases, 1 well-chosen query was sufficient to provide time series of searches highly correlated with incidence. We have shown the utility of an Internet search engine query data for surveillance of acute diarrhea and chickenpox in a non-English-speaking country. Thus, the ability of Internet search-engine query data to predict influenza in the United States presented by Ginsberg et al. (3) appears to have a broader application for surveillance of other infectious diseases in other countries.

This study was supported by the Institut National de la Santé et de la Recherche Médicale.

**Camille Pelat, Clément Turbelin, Avner Bar-Hen, Antoine Flahault, and Alain-Jacques Valleron**

Author affiliations: Institut National de la Santé et de la Recherche Médicale, Paris, France (C. Pelat, C. Turbelin, A.-J. Valleron); Université Pierre et Marie Curie–Paris 6, Paris (C. Pelat, C. Turbelin, A.-J. Valleron); Université Paris Descartes, Paris (A. Bar-Hen); and Ecole des Hautes Études en Santé Publique, Paris (A. Flahault)

DOI: 10.3201/eid1508.090299

**References**

1. Eysenbach G. Infodemiology: tracking flu-related searches on the web for syndromic surveillance. AMIA Annu Symp Proc. 2006:244–8.
2. Polgreen PM, Chen Y, Pennock DM, Nelson FD. Using internet searches for influenza surveillance. Clin Infect Dis. 2008;47:1443–8. DOI: 10.1086/593098
3. Ginsberg J, Mohebbi MH, Patel RS, Brammer L, Smolinski MS, Brilliant L. Detecting influenza epidemics using search en-

gine query data. Nature. 2009;457:1012–4. DOI: 10.1038/nature07634


4. Valleron AJ, Bouvet E, Garmerin P, Menares J, Heard I, Letrait S, et al. A computer network for the surveillance of communicable diseases: the French experiment. Am J Public Health. 1986;76:1289–92. DOI: 10.2105/AJPH.76.11.1289
5. Google insights for search, 2009 [cited 2009 Feb 27]. Available from <http://www.google.com/insights/search/#>

Address for correspondence: Camille Pelat, Institut National de la Santé et de la Recherche Médicale, Unité Mixte de Recherche S 707, Faculté de Médecine Pierre et Marie Curie, Site Saint-Antoine, Porte 807, 27 rue Chaligny, 75571 Paris CEDEX 12, France; email: [pelat@u707.jussieu.fr](mailto:pelat@u707.jussieu.fr)

**Human-to-Dog Transmission of Methicillin-Resistant *Staphylococcus aureus***

**To the Editor:** In November 2007, a 76-year-old man with diabetes mellitus, chronic lymphocytic leukemia, and chronic obstructive pulmonary disease, who was being treated with prolonged corticosteroid therapy, received a diagnosis of invasive pulmonary aspergillosis. After 4 weeks of voriconazole therapy, cellulitis with substantial erythema, induration, and tenderness developed in his right bicep muscle. Bacterial cultures from a skin biopsy sample yielded methicillin-resistant *Staphylococcus aureus* (MRSA), resistant to trimethoprim/sulfamethoxazole, clindamycin, erythromycin, tetracycline, and ciprofloxacin. The patient received intravenous vancomycin for 3 weeks. After prolonged hospitalization, he was discharged but again hospitalized in February 2008 for cellulitis in the right ankle. Cultures of drainage around the ankle grew MRSA with a susceptibility pattern identical to that of the previous isolate. In April 2008, after the patient had received vancomycin for 1 week and the infection had resolved, a nasal swab showed carriage of MRSA with a susceptibility pattern identical to that of the previous isolates.

In late February 2008, the man's 8-year-old spayed female Labrador retriever was examined for cellulitis and generalized abscessation of the neck area, which had not responded to empirical treatment with oral cephalexin. In December 2007, she had undergone surgery for a ruptured cranial cruciate ligament (right tibial plateau-leveling osteotomy). She had chewed some sutures out after surgery, and cultures of a purulent discharge from the incision grew *Pseudomonas aeruginosa*;



this infection was successfully treated with enrofloxacin. As a result of implant failure, surgery was repeated in early February 2008. Cultures of the joint fluid and implants at this time were negative.

Physical examination in late February showed a large, firm area of extensive swelling on the ventral aspect of the dog's neck and purulent discharge from ulcerations (Figure). She had dried discharge around her right stifle and was moderately lame on that leg. Cultures of blood, tissue samples from her neck, and fluid draining from the right stifle joint all grew MRSA (also resistant to trimethoprim/sulfamethoxazole, clindamycin, erythromycin, tetracycline, enrofloxacin, marbofloxacin, and orbifloxacin). A biopsy sample of the neck showed severe, acute, multifocal, neutrophilic vasculitis with numerous fibrin thrombi and moderate to severe, superficial to deep, perivascular to periadnexal, suppurative lymphohistiocytic dermatitis. The dog became increasingly lethargic; systemic inflammatory response syndrome developed, and the neck became severely ulcerated and necrotic. Aggressive therapy with intravenous hydration and antimicrobial

drugs (clindamycin and cefazolin, given before culture results were known) produced little clinical response. Extensive regions of skin sloughed, the face and neck became edematous, and focal masses developed within the lips. Signs of septic shock developed, and the dog was humanely euthanized 48 hours after this admission for skin lesions.

Pulsed-field gel electrophoresis was performed on isolates from the man and the dog. The isolates were indistinguishable and not consistent with recognized USA epidemic clones. *Spa* typing was also performed, and all isolates were *spa* type 3, also known as t037 according to the Ridom classification. Genes encoding for production of the Panton-Valentine leukocidin gene were not detected by real-time PCR (1).

Prevalence of MRSA in humans is increasing in most of the world. Similarly, MRSA colonization and infections in pets have increased in the past few years (1–5). MRSA can be transmitted between persons and their pets (1–4,6), although the route of transmission, risk factors for transmission, and incidence of interspecies transmission are not well understood.

We describe a case of human-to-dog transmission of MRSA, which led to euthanasia of the dog.

Given the degree of antimicrobial-drug resistance in the MRSA isolates and the close ongoing contact of the human with the healthcare system, we suspect that the source of the MRSA infection was the human healthcare system. The dog likely acquired MRSA through close contact with her owner in that she had an open wound from complications of her orthopedic surgery. Most cases of MRSA in dogs have been associated with colonization, skin and soft tissue infections, or surgical site infections (1,7,8). Human-to-dog transmission is also supported by the temporal association of both infections and the dog's negative bacterial cultures in early February.

Studies of MRSA infection and colonization in household pets show that pets tend to be infected or colonized with MRSA strain types from the local human population (3,7). We, along with others, believe that MRSA in pets is closely linked to MRSA in humans and that infected or colonized humans may often be the source of MRSA in household animals (5). For some MRSA cases, infection reportedly resolved after the reservoir (either humans or animals in the household) was identified and treated appropriately (4–6). With MRSA infections reaching epidemic proportions, physicians and veterinarians must be aware of MRSA and the risk for cross-infection between species. To help develop infection control and treatment strategies to reduce the risk for infection within a household, further study is needed to clarify the epidemiology of interspecies transmission of MRSA.

**Bronwyn E. Rutland,  
J. Scott Weese, Carole Bolin,  
Jennifer Au,  
and Anurag N. Malani**

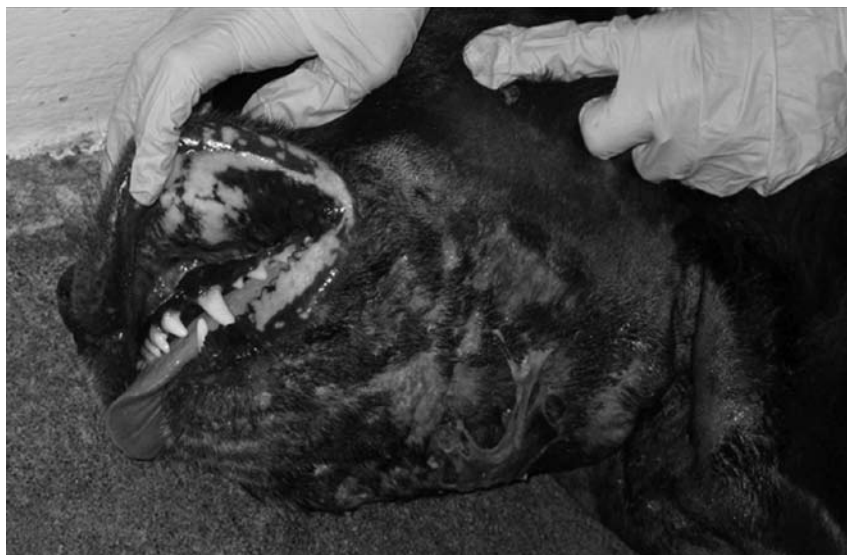

Figure. Extensive neck swelling with ulcerations and purulent discharge on 8-year-old spayed female Labrador retriever. Culture of the exudate and a macerated skin biopsy specimen grew methicillin-resistant *Staphylococcus aureus*. A color version of this figure is available online ([www.cdc.gov/EID/content/15/8/1329-F.htm](http://www.cdc.gov/EID/content/15/8/1329-F.htm)).

Author affiliations: Michigan State University, East Lansing, Michigan, USA (B.E. Rutland, C. Bolin, J. Au); University of Guelph, Guelph, Ontario, Canada (J.S. Weese); and St. Joseph Mercy Health System, Ann Arbor, Michigan, USA (A.N. Malani)

DOI: 10.3201/eid1508.081635

## References

- Rankin S, Roberts S, O'Shea K, Maloney D, Lorenzo M, Benson CE. Panton Valantine leukocidin (PVL) toxin positive MRSA strains isolated from companion animals. *Vet Microbiol.* 2005; 145–8.
- van Duijkeren E, Wolhagen MJ, Box AT, Heck ME, Wannet WJ, Fluit AC. Human-to-dog transmission of methicillin-resistant *Staphylococcus aureus*. *Emerg Infect Dis.* 2004;10:2235–7.
- Weese JS, Dick H, Willey BM, McGeeer A, Kreiswirth BN, Innis B, et al. Suspected transmission of methicillin-resistant *Staphylococcus aureus* between domestic pets and humans in veterinary clinics and in the household. *Vet Microbiol.* 2006;115:148–55. DOI: 10.1016/j.vetmic.2006.01.004
- Sing A, Tuschak C, Hörmandorfer S. Methicillin-resistant *Staphylococcus aureus* in a family and its pet cat. *N Engl J Med.* 2008;358:1200–1. DOI: 10.1056/NEJMc0706805
- Vitale CB, Gross TL, Weese JS. Methicillin-resistant *Staphylococcus aureus* in cat and owner. *Emerg Infect Dis.* 2006;12:1998–2000.
- Cefai C, Ashurst S, Owens C. Human carriage of methicillin-resistant *Staphylococcus aureus* linked with a pet dog. *Lancet.* 1994;344:539–40. DOI: 10.1016/S0140-6736(94)91926-7
- Loeffler A, Boag AK, Sung J, Lindsay JA, Guardabassi L, Dalsgaard A, et al. Prevalence of methicillin-resistant *Staphylococcus aureus* among staff and pets in a small animal referral hospital in the UK. *J Antimicrob Chemother.* 2005;56:692–7. DOI: 10.1093/jac/dki312
- Tomlin J, Peard MJ, Lloyd DH, Howell S, Hartmann F, Jackson HA, et al. Methicillin-resistant *Staphylococcus aureus* infections in 11 dogs. *Vet Rec.* 1999;144:60–4.

Address for correspondence: Anurag N. Malani, St. Joseph Mercy Health System, 5333 McAuley Dr, Suite 3106, Ypsilanti, MI 48197, USA; email: malanian@umich.edu

## Potential Malaria Reemergence, Northeastern Thailand

**To the Editor:** The emergence and reemergence of infectious diseases are major problems for healthcare systems worldwide. Unfortunately, because accurate prediction of the occurrence of such diseases is difficult, if not impossible, surveillance and control can be carried out only after the outbreak has occurred. Predicting the likelihood of a disease outbreak should make it possible to start surveillance programs before outbreaks occur and to initiate control programs before the population has become seriously affected. We used data on changes in land use patterns to predict the likelihood of malaria reemergence in northeastern Thailand.

Because natural rubber is of major economic importance and cannot be replaced by synthetic alternatives, the demand for and production of this commodity has consistently increased (1). This situation has led to changes in agricultural practices in various countries in Southeast Asia; rubber production has increased in Myanmar, Laos, Thailand, and Vietnam (1,2).

Northeastern Thailand (Isaan) is a relatively poor area, and most rubber plantations belong to smallholders and provide them with a large source of income (3). In 1993, ≈284 km<sup>2</sup> of northeastern Thailand were covered by rubber plantations; this area increased to 422 km<sup>2</sup> in 1998 and to 948 km<sup>2</sup> by 2003 (3). Since then, planting has increased exponentially so that, by 2006, the total area planted with rubber was >2,463 km<sup>2</sup>; new plantings expanded another ≈1,345 km<sup>2</sup> from 2004 to 2006 and increased to a total of 5,029 km<sup>2</sup> in 2007 (3). The plants mature ≈6 years after planting; at that stage, the trees can reach 10–12 m in height, although the growth rate depends on the physical and biotic environment (4).

Deforestation in northeastern Thailand early in the last century led to an extreme reduction in the incidence of malaria (5) because the main vector mosquito in this area, *Anopheles dirus* sensu stricto, is forest dwelling and requires a shaded environment for its survival and reproduction (6). Currently, the northeastern part of the country is relatively free of autochthonous malaria cases except for 3 provinces that border Cambodia and Laos (5), Srisaket, Ubon Ratchathani, and Surin. In Srisaket and Ubon Ratchathani, 25% and 31%, respectively, of malaria cases are imported, particularly from Cambodia (7).

Mosquitoes are sensitive to changes in environmental conditions, such as shade, temperature, and humidity. These conditions are often influenced by land use change, such as conversion of rice paddies to rubber plantations (8). In addition to providing economic benefits for the population, rubber plantations also provide suitable habitats for *A. dirus* s.s., perhaps even better habitats than those found in the original rain forest; new plantations lead to increased mosquito density and disease incidence (8). Thus, planting large tracts of rubber potentially increases the likelihood of the reemergence of malaria in northeastern Thailand, although a malaria vector such as *A. dirus* s.s. could return without reemergence of the disease (9).

Should malaria return, the greatly reduced contact between the local Isaan population and *Plasmodium* spp. over the past ≈50 years suggests that malaria would enter a highly susceptible population, potentially leading to major health problems at the individual and regional levels. This possibility is of particular concern because several strains of *Plasmodium* in Thailand and surrounding countries are multidrug resistant, which leads to treatment difficulties (5).

Each land use change creates different microclimatic conditions,