

Rickettsia slovaca and *R. raoultii* in Tick-borne Rickettsioses

Philippe Parola, Clarisse Rovey, Jean Marc Rolain, Philippe Brouqui, Bernard Davoust, and Didier Raoult

Tick-borne lymphadenopathy (TIBOLA), also called *Dermacentor*-borne necrosis erythema and lymphadenopathy (DEBONEL), is defined as the association of a tick bite, an inoculation eschar on the scalp, and cervical adenopathies. We identified the etiologic agent for 65% of 86 patients with TIBOLA/DEBONEL as either *Rickettsia slovaca* (49/86, 57%) or *R. raoultii* (7/86, 8%).

In 1968, *Rickettsia slovaca*, a spotted fever group (SFG) *Rickettsia*, was isolated from *Dermacentor marginatus* ticks in the former Czechoslovakia before being detected in *D. marginatus* or *D. reticulatus* ticks throughout Europe (Figure 1) (1). In 1997, *R. slovaca* was described as a human pathogen and an agent of tick-borne lymphadenopathy (TIBOLA) (2). This syndrome, also called *Dermacentor*-borne necrosis erythema and lymphadenopathy (DEBONEL), is defined as the association of a tick bite, an inoculation eschar on the scalp, and cervical lymphadenopathies (3).

Since 1999, several rickettsial genotypes, called DnS14, DnS28, and RpA4, have been detected in *Dermacentor* spp. ticks throughout Europe (Figure 1). Isolates have been obtained and shown to belong to a unique new SFG rickettsia species named *R. raoultii* (4). In 2002, *R. raoultii* DNA was detected in a *D. marginatus* tick taken from the scalp of a patient in whom TIBOLA/DEBONEL developed in France (4). Moreover, DNA of what is now known to be *R. raoultii* has been found in the blood of 1 patient with TIBOLA/DEBONEL (5). The goal of this study was to identify the rickettsial agents in patients with TIBOLA/DEBONEL symptoms and in those who had an isolated tick bite on the scalp.

The Study

We included all patients with TIBOLA/DEBONEL symptoms (Figure 2) and those who had an isolated tick

bite on the scalp without any symptoms from whom samples (serum, skin biopsy, or ticks harvested from the scalp) were received at our laboratory from January 2002 through December 2007. Epidemiologic and clinical data were collected retrospectively. The study was approved by the ethics committee of the Medicine School of Marseille under reference 08-008.

Immunoglobulin (Ig) G and IgM titers against rickettsial antigens were estimated by microimmunofluorescent assay; results were verified by Western blot and cross-absorption studies (3). Ticks found on persons and skin biopsy specimens were cultured on human embryonic

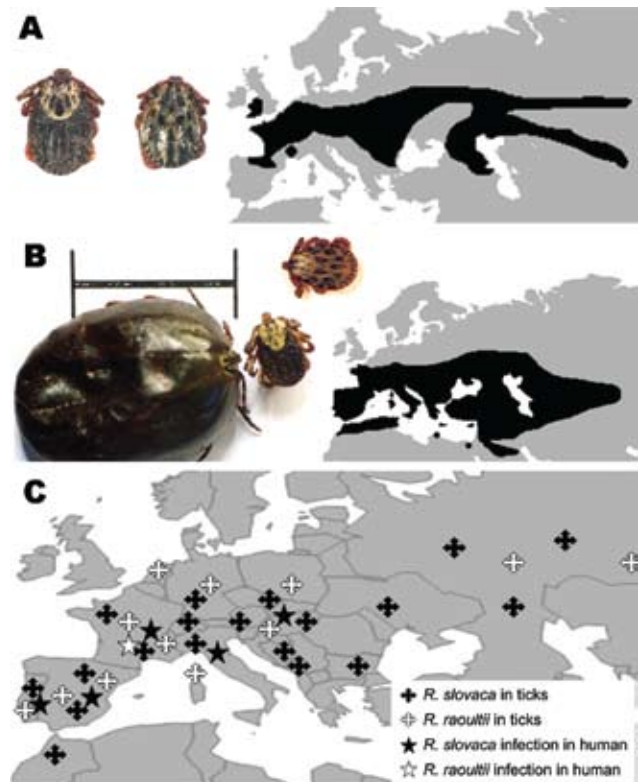


Figure 1. *Dermacentor reticulatus*, the ornate dog tick (A) (female, left; male, right), and *D. marginatus*, the ornate sheep tick (B) (engorged female, left; unfed female, center; male, right; scale bar = 1 cm), and their distribution. *D. marginatus* is most frequently found in Mediterranean areas of Europe with dense bush and tree cover and is common under oak and pine vegetation. It also has a restricted distribution in North Africa, in the cooler and more humid areas associated with the Atlas Mountains. Adults infest large mammals such as sheep, cattle, goats, and wild boars. Larvae and nymphs feed mostly on small mammals and medium sized carnivores. *D. reticulatus* is most frequently found in colder northern areas of western Europe and the former Soviet Union, with high humidity and mild winters. *D. reticulatus* is primarily a tick of dogs and carnivores, but it can be found on ungulates such as sheep, cattle, and horses (9). *D. marginatus* and *D. reticulatus* have been suggested as reservoirs of *R. slovaca* and *R. raoultii*, which are maintained in ticks through transstadial and transovarial transmission. Therefore, the geographic distribution of these rickettsiae likely parallels that of *Dermacentor* ticks (C).

Author affiliations: Unité des Rickettsies, Marseille, France (P. Parola, C. Rovey, J.M. Rolain, P. Brouqui, D. Raoult); and Direction Régionale du Service de Santé des Armées, Toulon, France (B. Davoust)

DOI: 10.3201/eid1507.081449

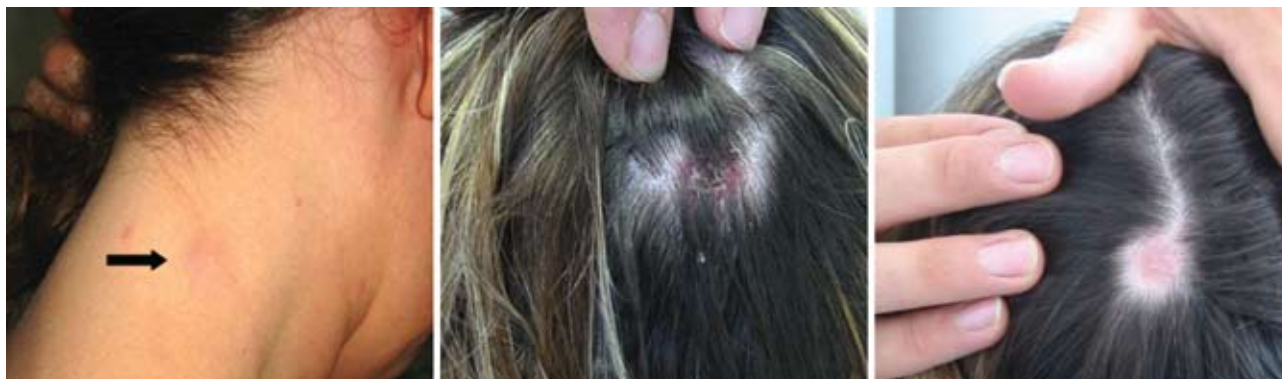

Figure 2. Typical signs of TIBOLA (tick-borne lymphadenopathy)/DEBONEL (*Dermacentor*-borne necrosis erythema and lymphadenophy). Here, infections were caused by *Rickettsia slovaca*, resulting in cervical lymphadenopathy (left panel, arrow), inoculation on the scalp (middle panel), and residual alopecia 4 weeks later (right panel).

lung cells (6). These samples were also used to amplify and identify outer membrane protein A–encoding gene fragments of rickettsiae by PCR (3). Also, the so-called suicide PCR-assay was used with acute-phase serum samples (1).

Among 98 study patients, 86 were classified as TIBOLA/DEBONEL patients. Twelve (12.2%) patients made up the second group with an isolated tick bite. All but 1 patient, who was bitten in Belgium, were bitten in France. Tick bites more frequently occurred from February through May (50/86, 58.1%). Because of results of serologic techniques, we could conclude that 66 (84.6%) of 78 TIBOLA/DEBONEL patients with obtained serum specimens had a recent rickettsial disease. Western blot and cross-adsorption analyses enabled detection of antibodies specifically directed against *R. slovaca* and *R. raoultii* in 34 and 4 patients, respectively (online Appendix Table, available from www.cdc.gov/EID/content/15/7/1105-appT.htm).

Two patients who were infected with *R. slovaca* were found to be co-infected with *Coxiella burnetii* in an acute form of Q fever. Serologic testing was performed in 12 patients with isolated tick bites, and results were negative in all cases. A total of 19 skin biopsy specimens were obtained. Four *R. slovaca* infections were diagnosed by regular PCR, and 3 isolates of this rickettsia were obtained. The suicide PCR on acute-phase serum samples identified 1 additional case of *R. slovaca* infection. Because of molecular tools and culture, 6 patients received the diagnosis of an *R. slovaca* infection, including 5 who did not receive a diagnosis by serologic assays (online Appendix Table). Ticks removed from 28 TIBOLA/DEBONEL patients consisted of 23 *D. marginatus* (88.4%), 2 *Dermacentor* spp., 1 *Haemaphysalis punctata*, and 2 that were not identified. Overall, the tick studies enabled us to suggest the diagnosis of *R. slovaca* and *R. raoultii* infections in 10 and 3 patients, respectively, whose conditions were not diagnosed with previous tests (online Appendix Table).

All DNA sequences obtained showed 100% identity with *R. raoultii* or *R. slovaca*, excluding the coexistence of several rickettsiae in the corresponding samples. According to our investigations, 49 (57%) of 86 patients with TIBOLA/DEBONEL had probable or certain *R. slovaca* infections, and 7 (8%) of 86 had probable *R. raoultii* infections. The characteristics of these patients are shown in the Table.

Conclusions

We report 86 patients with TIBOLA/DEBONEL; this group includes 14 patients whose conditions had been preliminarily reported (7). We also describe several cases caused by the emerging pathogen *R. raoultii* (4), including patients with indirect molecular evidence of infection because the pathogen was detected in the ticks that had bitten them. Original findings also include facial edema as a new clinical feature in TIBOLA/DEBONEL, and the report of the second patient co-infected with *R. slovaca* and *C. burnetii* (8). Because acute Q fever, a worldwide zoonosis, may be asymptomatic, we recommend that patients infected with tick-borne pathogens also undergo testing for concurrent infections with *C. burnetii*.

No TIBOLA/DEBONEL cases were recorded during the warmest summer months; peak incidence occurred during March–May and during September–November, linked with the activity of *Dermacentor* ticks in Europe (Figure 1) (9). However, to date, we have no explanation for the finding that children and women are at higher risk for TIBOLA/DEBONEL or why *D. marginatus* and *D. reticulatus* ticks prefer to bite persons on the scalp. A possible explanation could be that *Dermacentor* ticks usually bite hairy domestic and wild animals and the longer hair of women and children may attract them.

One of the most remarkable findings of this work is the proportional importance of *R. slovaca* in TIBOLA/DEBONEL patients, compared with *R. raoultii*. In 2006, Ibarra

Table. Characteristics of TIBOLA/DEBONEL patients with certain or probable *Rickettsia slovaca* infection compared with patients with certain or probable *R. raoultii* infection*

Characteristic	TIBOLA/DEBONEL patients, n = 86		p value
	No. <i>R. slovaca</i> infections (%), n = 49†‡	No. <i>R. raoultii</i> infections (%), n = 7†	
Female sex	33/49 (67)	7/7 (100)	0.04
Mean age, y	32	32	0.90
Age ≤12 y	20/49 (41)	3/7 (43)	0.46
Hiking or recreational activities such as a walk in the forest	21/28 (75)	4/5 (80)	0.44
Fever§	21/39 (54)	4/5 (80)	0.27
Painful eschar	14/22 (64)	3/3 (100)	0.30
Painful adenopathies	18/26 (69)	5/5 (100)	0.20
Face edema	6/31 (19)	2/5 (40)	0.30
Rash	7/30 (23)	1/5 (20)	0.68
Headache	16/30 (53)	4/4 (100)	0.10
Alopecia	16/27 (59)	0/4	0.09
Asthenia	23/33 (70)	5/5 (100)	0.20
Prolonged asthenia¶	10/29 (35)	2/4 (50)	0.46
Chronic asthenia#	4/28 (14)	1/4 (25)	0.51

*Certain cases were those with positive culture, PCR, or suicide PCR results in blood or skin biopsy samples or with lymph node aspirates. Probable cases were those with identification by PCR and sequencing of the corresponding *Rickettsia* spp. in ticks, Western blot results demonstrating *R. slovaca*– or *R. raoultii*–specific antibodies, or a cross-absorption assay demonstrating specific antibodies against *R. slovaca* or *R. raoultii*. TIBOLA, tick-borne lymphadenopathy; DEBONEL, *Dermacentor*-borne necrosis erythema and lymphadenopathy.

†Denominators indicate the number of patients for whom the criterion was available.

‡Includes 14 patients previously reported (7).

§Temperature >37°C.

¶Self-reported, persistent asthenia of 1 to 6 months.

#Self-reported persistent or relapsing asthenia of >6 consecutive months.

et al. reported on 14 persons in Spain who had a *D. marginatus* tick attached to the scalp (10). All ticks were found to be infected by rickettsiae: 8 (58%) were infected by *R. slovaca*, and 6 (42%) by *R. raoultii*. In 10 of the patients, TIBOLA/DEBONEL symptoms developed, including in all 8 of the patients who had been bitten by a tick infected by *R. slovaca* and in 2 of the 6 patients who had been bitten by a tick infected by *R. raoultii*. *R. slovaca* was more significantly associated with TIBOLA/DEBONEL patients than was *R. raoultii* ($p < 0.05$) (10). Here, focusing on the studies of ticks removed from TIBOLA/DEBONEL patients, we found that 12 of 19 ticks harbored *R. slovaca*, whereas only 3 of 19 harbored *R. raoultii* ($p = 0.047$). In the patients with asymptomatic tick bites, from whom 9 ticks were obtained, all ticks positive by PCR harbored *R. raoultii*.

Moreover, *R. raoultii* seems to be more highly prevalent in *D. marginatus* and *D. reticulatus* ticks in nature than is *R. slovaca*. Although comparing field surveys of ticks is difficult because of the sampling methods, the sizes of the samples, and the potential PCR inhibitors, *R. raoultii* has been more frequently detected in *D. marginatus* ticks than has *R. slovaca*. In southeastern Spain, 73% of 101 *D. marginatus* ticks were infected by *R. raoultii* and 27% by *R. slovaca* (11). Similar differences have been shown in Germany, Portugal, the Netherlands, and Spain (12–15). Although interpreting these data definitively is difficult, the recurrence of similar published results by different teams suggests that exposure to *R. raoultii* through the bite of a *Dermacentor* spp. tick is likely more frequent than expo-

sure to *R. slovaca*. However, more cases of *R. slovaca* infection have been recorded, which suggests that *R. raoultii* is less pathogenic.

TIBOLA/DEBONEL is a newly recognized disease, and its incidence is likely underestimated. In our laboratory, TIBOLA/DEBONEL is the most frequently reported rickettsial disease, except during the dry summer period. Doxycycline remains the treatment of choice, with new macrolides as alternative treatments (1). Although we report 6 more cases of *R. raoultii* infection in addition to the 2 recently reported (4,5), this *Dermacentor*-borne rickettsia seems to be less pathogenic than *R. slovaca*.

Acknowledgments

We thank all clinicians for help in collecting epidemiologic and clinical data.

Dr Parola is associate professor of infectious diseases and tropical medicine at the Medical School of Marseille, France. His research interests focus on vector-borne infectious tropical diseases, travel medicine, and medical entomology.

References

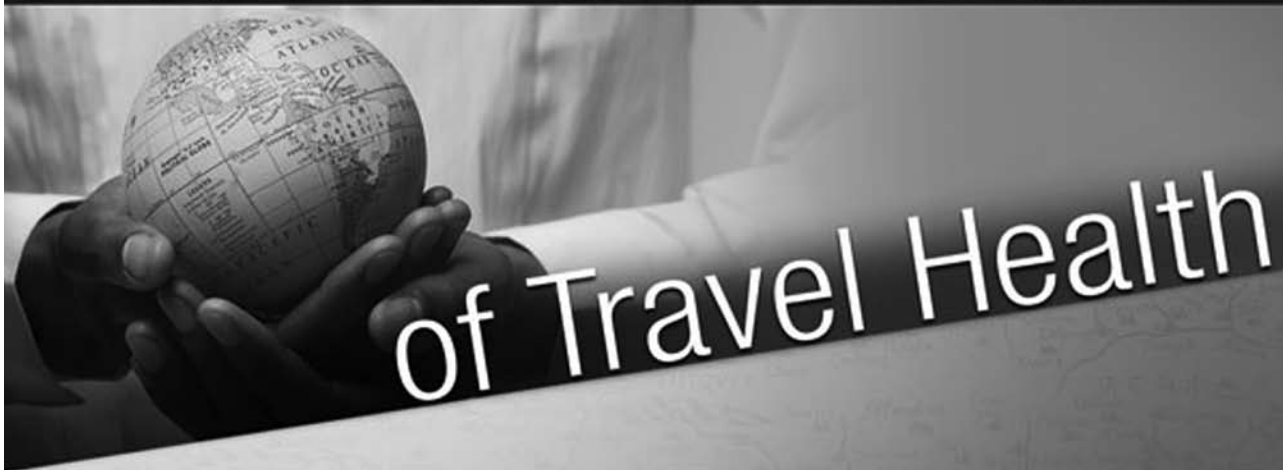1. Parola P, Paddock C, Raoult D. Tick-borne rickettsioses around the world: emerging diseases challenging old concepts. *Clin Microbiol Rev.* 2005;18:719–56. DOI: 10.1128/CMR.18.4.719-756.2005
2. Raoult D, Berbis P, Roux V, Xu W, Maurin M. A new tick-transmitted disease due to *Rickettsia slovaca*. *Lancet.* 1997;350:112–3. DOI: 10.1016/S0140-6736(05)61814-4

3. Raoult D, Lakos A, Fenollar F, Beytout J, Brouqui P, Fournier PE. Spotless rickettsiosis caused by *Rickettsia slovaca* and associated with *Dermacentor* ticks. *Clin Infect Dis*. 2002;34:1331–6. DOI: 10.1086/340100
4. Mediannikov O, Matsumoto K, Samoylenko I, Drancourt M, Roux V, Rydkina E, et al. *Rickettsia raoultii* sp. nov., a spotted fever group rickettsia associated with *Dermacentor* ticks in Europe and Russia. *Int J Syst Evol Microbiol*. 2008;58:1635–9. DOI: 10.1099/ijs.0.64952-0
5. Ibarra V, Oteo JA, Portillo A, Santibanez S, Blanco JR, Metola L, et al. *Rickettsia slovaca* infection: DEBONEL/TIBOLA. *Ann N Y Acad Sci*. 2006;1078:206–14. DOI: 10.1196/annals.1374.040
6. Parola P, Vestris G, Martinez D, Brochier B, Roux V, Raoult D. Tick-borne rickettsiosis in Guadeloupe, the French West Indies: isolation of *Rickettsia africae* from *Amblyomma variegatum* ticks and serosurvey in humans, cattle, and goats. *Am J Trop Med Hyg*. 1999;60:888–93.
7. Gouriet F, Rolain JM, Raoult D. *Rickettsia slovaca* infection, France. *Emerg Infect Dis*. 2006;12:521–3.
8. Tissot-Dupont H, Raoult D. Q fever. *Infect Dis Clin North Am*. 2008;22:505–14. DOI: 10.1016/j.idc.2008.03.002
9. Estrada-Pena A, Bouattour A, Camicas JL, Walker AR. Ticks of domestic animals in the Mediterranean region. Zaragoza (Spain): University of Zaragoza; 2004.
10. Ibarra V, Portillo A, Santibanez S, Blanco JR, Perez-Martinez L, Marquez J, et al. DEBONEL/TIBOLA: is *Rickettsia slovaca* the only etiological agent? *Ann N Y Acad Sci*. 2005;1063:346–8. DOI: 10.1196/annals.1355.056
11. Marquez FJ, Rojas A, Ibarra V, Cantero A, Rojas J, Oteo JA, et al. Prevalence data of *Rickettsia slovaca* and other SFG rickettsiae species in *Dermacentor marginatus* in the southeastern Iberian peninsula. *Ann N Y Acad Sci*. 2006;1078:328–30. DOI: 10.1196/annals.1374.062
12. Dautel H, Dippel C, Oehme R, Hartelt K, Schettler E. Evidence for an increased geographical distribution of *Dermacentor reticulatus* in Germany and detection of *Rickettsia* sp. RpA4. *Int J Med Microbiol*. 2006;296:149–56. DOI: 10.1016/j.ijmm.2006.01.013
13. Vitorino L, De SR, Bacellar F, Ze-Ze L. *Rickettsia* sp. strain RpA4 detected in Portuguese *Dermacentor marginatus* ticks. *Vector Borne Zoonotic Dis*. 2007;7:217–20. DOI: 10.1089/vbz.2006.0603
14. Nijhof AM, Bodaan C, Postigo M, Nieuwenhuijs H, Opsteegh M, Franssen L, et al. Ticks and associated pathogens collected from domestic animals in the Netherlands. *Vector Borne Zoonotic Dis*. 2007;7:585–95. DOI: 10.1089/vbz.2007.0130
15. Marquez FJ. Spotted fever group *Rickettsia* in ticks from southeastern Spain natural parks. *Exp Appl Acarol*. 2008;45:185–94. DOI: 10.1007/s10493-008-9181-7

Address for correspondence: Didier Raoult, URMITE, Unité des Rickettsies, CNRS-IRD UMR 6236, Faculté de Médecine, 27, Blvd Jean Moulin, 13385 Marseille, France; email: didier.raoult@gmail.com

The opinions expressed by authors contributing to this journal do not necessarily reflect the opinions of the Centers for Disease Control and Prevention or the institutions with which the authors are affiliated.

Discover the world...



www.cdc.gov/travel

Visit the CDC Travelers' Health website for up-to-date information on global disease activity and international travel health recommendations.

Department of Health and Human Services • Centers for Disease Control and Prevention

Appendix Table. Results of microbiologic investigations regarding rickettsial diseases of patients with TIBOLA/DEBONEL or tick-bite*

Patients	Serologic assays (MIF assay and WB)†				Suicide PCR‡ of acute-phase serum sample				Standard PCR and/or culture of cutaneous biopsy specimens				Tick study			All methods			
	No. pos/ no. tested	Rs	Rr	ND	No. tested	Rs	Rr	Neg	No. tested	Rs	Rr	Neg	No. tested	Rs	Rr	Neg	Rs	Rr	ND
With TIBOLA/ DEBONEL (n = 86)	66/78	34	4	28	36	1§	0	35	19	5¶	0	13	19	12#	3	4	49**,††	7**	30
Had isolated tick bite (n = 12)	0/5	–	–	–	5	0	0	0	–	–	–	–	9	0	5	4	0‡‡	5‡‡	7

*TIBOLA, tick-borne lymphadenopathy; DEBONEL, *Dermacentor*-borne necrosis erythema and lymphadenopathy; MIF, microimmunofluorescent; WB, Western blot; pos, positive; Rs, *Rickettsia slovaca* specific diagnosis or identification; Rr, *Rickettsia raoultii* specific diagnosis or identification; ND, specific rickettsia involved was not determined; neg, negative.

†MIF assay using 7 spotted fever group rickettsial antigens (*R. conorii*, *R. aeschlimannii*, *R. massiliae*, *R. helvetica*, *R. slovaca*, *R. raoultii*, *R. felis*), a typhus group antigen, *R. typhi*, and *Coxiella burnetii*. For rickettsial antigens, titers ≥ 64 for immunoglobulin (Ig) G and ≥ 32 for IgM, as well as seroconversion or a 4-fold increase in antibody titers from early to late serum specimens, were considered MIF positive. When cross-reactions were noted among several rickettsial antigens, a rickettsial antigen was considered to indicate presence of the infectious agent if titers of IgG and/or IgM antibody against this antigen were at least 2-fold higher than titers of IgG and/or IgM antibody against other rickettsial antigens. When titers differed by ± 1 standard dilution, WB assays and cross absorption studies were performed.

‡Nestled PCR in which both the template DNA fragment and the primers are used only once. (Primers available on request.) All positive PCR amplicons were sequenced with the primers used for PCR, for precise identification of the infecting *Rickettsia* species. As negative controls, introduced for every 5 patient specimens, we used cardiac valve biopsy specimens obtained from patients who had undergone a valvular replacement for a degenerative disease. No positive controls were used.

§Sample from patient negative by serologic assays.

¶Includes 4 samples from patients negative by serologic assays.

#Includes 10 samples from patients negative by serologic assays, culture, and molecular methods.

** $p < 0.05$ (by Mantel-Haenszel test) between these 2 groups.

††Including 2 cases with coinfection with *C. burnetii*, the agent of Q fever. The first case occurred in the patient described above with neurologic symptoms (diagnosed on the basis of an anti-phase II IgG titer of 100 and an anti-phase II IgM titer of 50). The second case-patient was a pregnant woman with no symptoms other than the TIBOLA/DEBONEL (diagnosed on the basis of an anti-phase II IgG titer of 400 and an anti-phase II IgM titer of 100).

‡‡ $p < 0.05$ (by Mantel-Haenszel test) between these 2 groups.