

cattle (2,8). Taken together, the prevalence of EHEC serotype O145:H- in cats, humans, and cattle might indicate that the girl was probably more likely the infection source for the cat than vice versa. Third, a cycle of mutual infection and reinfection between the girl and her pet cat cannot be ruled out. Although the excretion rate for EHEC changes over time and EHEC can therefore remain undetected in stool samples while still present within the patient, the child tested EHEC negative for a short period. Despite all the precautions taken, the girl may have been reinfected by the cat.

This case illustrates several issues: 1) domestic animals such as cats (3), dogs (3,4), and rabbits (9) may serve as reservoirs for EHEC, irrespective of whether they are the primary or secondary source for these bacteria; 2) domestic cats as carriers may excrete EHEC for a prolonged period; 3) autovaccination may be effective for treating EHEC-infected animals; and 4) fondness for pets may be problematic: although EHEC O145:H- is among the 4 most often isolated EHEC serotypes associated with severe colitis or life-threatening hemolytic uremic syndrome (10), the girl's parents, after weighing the infectious risks against the psychological benefits for both their daughter and her feline companion, decided not to send the cat to an animal shelter until its EHEC infection disappeared.

Ulrich Busch,*

Stefan Hörmansdorfer,*

Stephan Schraner,† Ingrid Huber,*

Karl-Heinz Bogner,*

and Andreas Sing*

*Bavarian Health and Food Safety Authority, Oberschleißheim, Germany; and †Veterinary Inspection Office, Landshut, Germany

References

- Nataro JP, Kaper JB. Diarrheagenic *Escherichia coli*. Clin Microbiol Rev. 1998;11:142–201.

- Bettelheim KA. Non-O157 verotoxin-producing *Escherichia coli*: a problem, paradox, and paradigm. Exp Biol Med. 2003;228:333–44.
- Krause G, Zimmermann S, Beutin L. Investigation of domestic animals and pets as a reservoir for intimin- (eae) gene positive *Escherichia coli* types. Vet Microbiol. 2005;106:87–95.
- Sancak AA, Rutgers HC, Hart CA, Batt RM. Prevalence of enteropathogenic *Escherichia coli* in dogs with acute and chronic diarrhoea. Vet Rec. 2004;154:101–6.
- Eklund M, Scheutz F, Siitonen A. Clinical isolates of non-O157 Shiga toxin-producing *Escherichia coli*: serotypes, virulence characteristics, and molecular profiles of strains of the same serotype. J Clin Microbiol. 2001;39:2829–34.
- Beutin L, Zimmermann S, Gleier K. Human infections with Shiga toxin-producing *Escherichia coli* other than serogroup O157 in Germany. Emerg Infect Dis. 1998;4:635–9.
- Brooks JT, Sowers EG, Wells JG, Greene KD, Griffin PM, Hoekstra RM, et al. Non-O157 Shiga toxin-producing *Escherichia coli* infections in the United States, 1983–2002. J Infect Dis. 2005;192:1422–9.
- Pearce MC, Evans J, McKendrick II, Smith AW, Knight HI, Mellor DJ, et al. Prevalence and virulence factors of *Escherichia coli* serogroups O26, O103, O111, and O145 shed by cattle in Scotland. Appl Environ Microbiol. 2006;72:653–9.
- Garcia A, Fox JG. The rabbit as a new reservoir host of enterohemorrhagic *Escherichia coli*. Emerg Infect Dis. 2003;9:1592–7.
- Gerber A, Karch H, Allerberger F, Verweyen HM, Zimmerhackl LB. Clinical course and the role of Shiga toxin-producing *Escherichia coli* infection in the hemolytic-uremic syndrome in pediatric patients, 1997–2000, in Germany and Austria: a prospective study. J Infect Dis. 2002;186:493–500.

Address for correspondence: Andreas Sing, MA DTM&H, Bavarian Health and Food Safety Authority, Veterinärstraße 2, 85764 Oberschleißheim, Germany; email: andreas.sing@lgl.bayern.de



Misdiagnosing Melioidosis

To the Editor: Melioidosis is endemic in southern and Southeast Asia and northern Australia. Although relatively few indigenous cases are recognized in the Indian subcontinent, a substantial proportion of cases imported into the United Kingdom originate there, probably reflecting patterns of immigration and travel, and underdiagnosis within the Indian subcontinent (1–3).

A 33-year-old woman spent 3 months in India. Shortly after arriving there, fever, myalgia, rigors, pharyngitis, and tender cervical lymphadenopathy developed. After she received antimicrobial agents, her symptoms initially improved, but in September 2005, 1 week after returning to the United Kingdom, she visited her general practitioner with recurrent fever and increasingly painful cervical lymphadenopathy. She was given a course of oral co-amoxiclav 625 mg 3× daily. However, the following week she visited the emergency department of her local hospital with left-sided suppurative cervical lymphadenitis. Pus aspirated from the lymph node grew an aminoglycoside-resistant “pseudomonad” identified as *Pseudomonas fluorescens* (API20NE profile 1056554), assumed to be a contaminant. She was discharged home to complete a further 10-day course of co-amoxiclav.

One month later, the patient again went to the emergency department, this time with a submental abscess. An otolaryngology consultation was sought, and the abscess was incised and drained. Although tuberculosis was suspected, no acid-fast bacilli were identified, and cultures were negative for mycobacteria; histologic examination showed noncaseating granulomata. Culture of fluid from the submental collection again yielded an aminoglycoside-resistant pseudomonad, however. At this point misidentifi-

cation was suspected, and the isolate, which had a characteristic colony form on Ashdown's Medium, microscopic appearance (Figure, panel A), API20NE profile (1556574), and fatty acid profile, was identified as *Burkholderia pseudomallei*, the etiologic agent of melioidosis.

The patient had no relevant past medical history. Before immigrating to the United Kingdom 3 years earlier, she had lived in Tanjore, a rice-farming area of Tamil Nadu. She had stayed with family there during her recent trip, which coincided with the monsoon season, but she denied rural travel, fresh water contact, or skin abrasions. On examination, she was obese with acanthosis nigricans and tender cervical lymphadenopathy. Blood tests showed a mild microcytosis, low ferritin level, and erythrocyte sedimentation rate 40 mm/h; serum biochemistry and levels of C-reactive protein, fasting glucose, and hemoglobin by electrophoresis were nor-

mal. Two blood cultures were negative. Results of chest and abdominal imaging were normal. The patient was treated with intravenous ceftazidime for 10 days and oral co-trimoxazole for 4 months. She remains well.

B. pseudomallei serologic tests, performed subsequently, showed negative results by ELISA against the standard laboratory strain (204). However, when the assay was repeated using the patient's own isolate, the result was positive (immunoglobulin G titer 4,000). Comparison of lipopolysaccharide (LPS) antigens from the 2 strains by sodium dodecyl sulfate-polyacrylamide gel electrophoresis and immunoblotting showed that they differed in O-repeating units (Figure, panel B).

B. pseudomallei is an aerobic, gram-negative, environmental saprophyte ubiquitous in soil and surface water (e.g., paddy fields) in disease-endemic areas. Acquisition may occur through skin abrasions, aspiration of

fresh water, inhalation, and possibly ingestion and may occasionally occur in the laboratory. An association between severe respiratory melioidosis and heavy monsoonal rains suggests that inhalation has previously been underrecognized as a route of infection (4); this is the likely mode in this case.

Many infections are initially subclinical but may result in latency and delayed manifestations, even after several decades. Clinical signs and symptoms include septicemia, cavitating pneumonia, bone and soft tissue infections, disseminated abscesses, mycotic aneurysms, lymphadenitis, and childhood parotitis. Most patients have an underlying predisposition to infection, especially diabetes, renal disease, alcoholism, and thalassemia, but in the largest Indian case series 50% patients had no traditional risk factors, as with our patient (5). *B. pseudomallei* is a category B potential bioterrorism agent.

Limited awareness of the disease, confusion with other conditions such as tuberculosis, and laboratory constraints all probably contribute to underdiagnosis of melioidosis in many areas (6). However, accurate diagnosis is important because septicemic melioidosis may be rapidly fatal. *B. pseudomallei* is intrinsically resistant to many antimicrobial agents, and prolonged treatment is usually required to minimize relapse. Diagnosis is usually by culture from sterile sites. Laboratory misidentification is not uncommon and occurred in this case because the diagnosis was not considered. Isolation of aminoglycoside-resistant pseudomonads in patients from disease-endemic areas should always prompt consideration of melioidosis and accurate identification. PCR is an emerging diagnostic tool not yet extensively validated (7).

The role of serology in diagnosis is limited by high background seropositivity rates in disease-endemic areas. No standardized serologic test is inter-

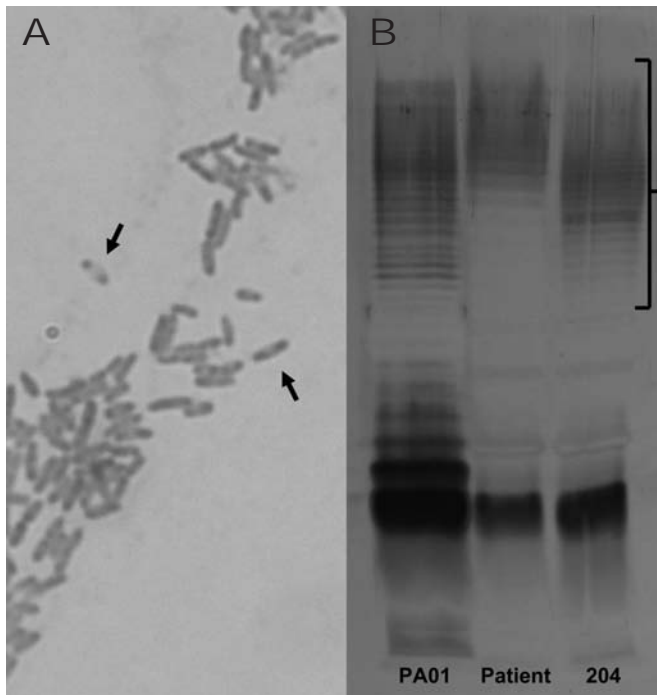


Figure. A) Gram stain of pus from the patient's submental collection, showing the characteristic safety-pin pattern (arrows) of bipolar staining. B) Sodium dodecyl sulfate-polyacrylamide gel electrophoresis of lipopolysaccharide (LPS) antigens from the patient and *Burkholderia pseudomallei* reference strain (204), showing different O-repeating units (bracket). A control isolate of *Pseudomonas aeruginosa* LPS (PA01) is shown for comparison.

nationally agreed upon. This case illustrates another potential pitfall in melioidosis serodiagnosis. Most isolates express a conserved LPS antigen, which allows use of a single reference strain for determination of anti-LPS antibodies (8). However, because some strains express different LPS antigens, serologic tests must be performed with the patient's own strain.

This case illustrates potential pitfalls in diagnosing melioidosis, which requires clinical and laboratory awareness and knowledge of its geographic distribution. LPS-based serologic assays should use a range of isolates representative of known LPS types.

Acknowledgment

We are grateful to the patient for permission to publish this case report.

A. J. Brent and R. Handy had clinical responsibility for the patient. R. Handy and P.C. Matthews made the initial microbiologic diagnosis of melioidosis, and T.L. Pitt confirmed the isolate as *Burkholderia pseudomallei*. T.L. Pitt performed the serology and SDS-PAGE analysis of lipopolysaccharide antigens. All authors contributed to preparation of the manuscript. A.J. Brent is guarantor for the article, had full access to all the clinical and microbiologic data, and had final responsibility for the decision to submit for publication.

Andrew J. Brent,* Philippa C. Matthews,* David A. Dance,†

Tyrone L. Pitt,‡ and Rupert Handy§

*John Radcliffe Hospital, Headley Way, Headington, Oxford, United Kingdom; †Health Protection Agency (South West), Plymouth, Devon, United Kingdom; ‡Laboratory of HealthCare Associated Infection, London, United Kingdom; and §Heatherwood and Wexham Park Hospitals, Wexham, Slough, United Kingdom

References

1. Dance DA, Smith MD, Aucken HM, Pitt TL. Imported melioidosis in England and Wales. *Lancet*. 1999;353:208.

2. John TJ, Jesudason MV, Lalitha MK, Ganesh A, Mohandas V, Cherian T, et al. Melioidosis in India: the tip of the iceberg? *Indian J Med Res*. 1996;103:62–5.
3. John TJ. Melioidosis, the mimicker of maladies. *Indian J Med Res*. 2004;119:vi–viii.
4. Currie BJ, Jacups SP. Intensity of rainfall and severity of melioidosis, Australia. *Emerg Infect Dis*. 2003;9:1538–42.
5. Jesudason MV, Anbarasu A, John TJ. Septicaemic melioidosis in a tertiary care hospital in south India. *Indian J Med Res*. 2003;117:119–21.
6. Dance DAB. Melioidosis: the tip of the iceberg? *Clin Microbiol Rev*. 1991;4:52–60.
7. Novak RT, Glass MB, Gee JE, Gal D, Mayo MJ, Currie BJ, et al. Development and evaluation of a real-time PCR assay targeting the type III secretion system of *Burkholderia pseudomallei*. *J Clin Microbiol*. 2006;44:85–90.
8. Pitt TL, Aucken H, Dance DA. Homogeneity of lipopolysaccharide antigens in *Pseudomonas pseudomallei*. *J Infect*. 1992;25:139–46.

Address for correspondence: Andrew J. Brent, Nuffield Department of Infectious Diseases & Microbiology, John Radcliffe Hospital, Headington, Oxford, United Kingdom OX3 9DU; email: dr.a.brent@gmail.com

Subclinical *Plasmodium falciparum* Infection and HIV-1 Viral Load

To the Editor: Studies indicate that *Plasmodium falciparum* infection increases HIV replication in adults (1,2). Although malaria-related illness and death are more common in children, and HIV-1 generally progresses faster in children than in adults (3,4), to our knowledge the effect of intermittent malaria on HIV-1 viral load has not been directly explored in children. To investigate this issue, we monitored HIV-positive infants from a 1996–2001 birth cohort study in Kisumu, Kenya, a *P. falciparum*-holoendemic area.

Study design and methods have been described elsewhere (5,6). Twenty-four children that were perinatally infected with HIV were included in this substudy. During monthly visits during the child's first 2 years of life, malaria and HIV incidence were recorded (5,6). Both children with malaria-positive blood smears and those with fever but no smear result available were treated with sulfadoxine-pyrimethamine according to national guidelines. At the time of this substudy, none of the study participants were taking antiretroviral drugs.

HIV and malaria diagnoses were determined by using standard methods (5–7). To reduce the chance of including infants infected through breast-feeding, perinatal infection was defined as ≥ 2 consecutive HIV-positive tests, with the first positive PCR result by 4 months of age (7). The so-called baseline viral load was the pre-malaria value measured 1 month before the first observation in the analysis. To be included in the analysis, follow-up visits had to have data available on the current and previous months' viral load and malaria status and occur at roughly monthly intervals at ≥ 4 months of age.

Malaria parasites were found at 53 of 146 visits in the month before viral load measurement, although at 89% of visits in which children were malaria-positive, the children's samples had $< 1,000$ parasites/ μL , and in only 13% of visits in which children had parasitemia did they also have fever (8). Median number of observations per child was 7 (range 2–18). No significant demographic or clinical differences were found between HIV-positive children in this substudy and those enrolled in the full cohort (data not shown).

Clinical and demographic variables were evaluated in univariate repeated measures analysis to determine associations with log-transformed HIV-1 viral load. Age and