

Supplementary Figures

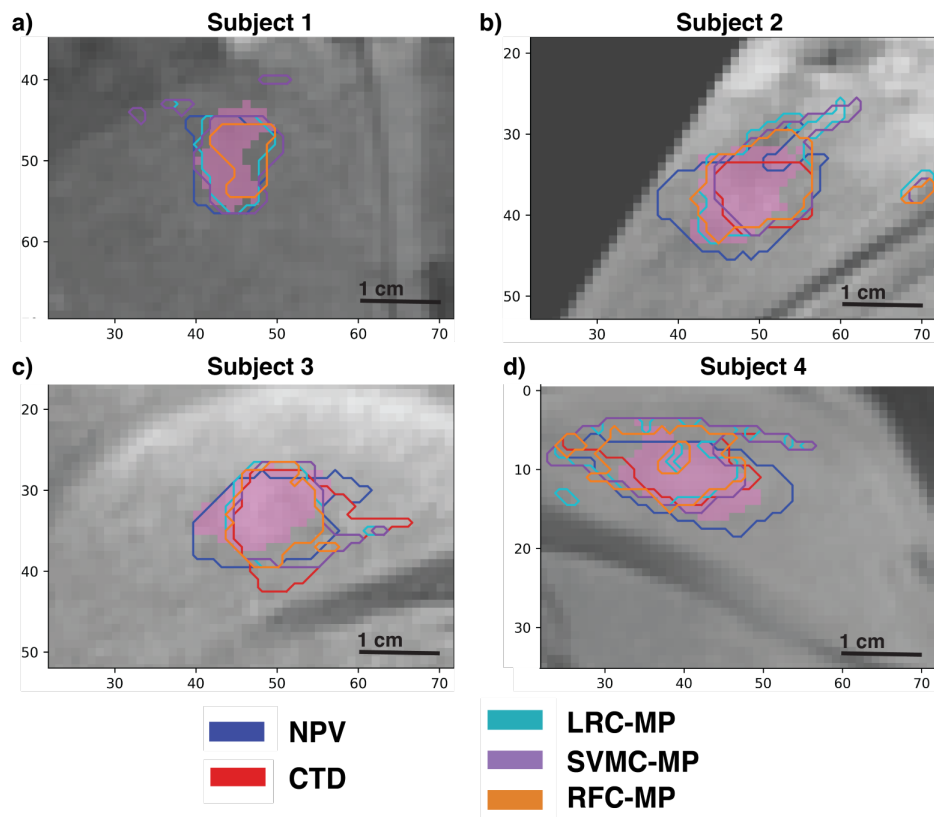


Figure S1. Pre-contrast 1-mm isotropic T1-weighted 2D coronal cross-sections of quadricep muscles located near the center of the ablated lesion with the voxel-wise histology necrosis label (light pink overlay). Contours of the acute NPV and LOO-trained optimized CTD and MPMR biomarkers in each test subjects 1-4 (from a) to d), respectively). For scale, the x- and y- axes are in [mm].